



**PATIENT PRESENTING CLINICAL SIGNS**

**Sadie Deakin**  
**SPECIES** History: Presented for decreased appetite/ anorexia for 3 days. Patient was visibly icteric. Has had chronic changes to liver enzymes in the past. Appeared tense during palpation but pt also has significant anxiety in hospital.

**Canine**  
**BREED** Abnormal PE/Chem/CBC/UA Results: Elevated ALT, ALP. Bilirubin chronic mild elevation, now > 15. CBC/CHEM attached. HCT wnl. Usg was 1.011.

**Med Mixed Breed**  
**ULTRASONOGRAPHIC EXAMINATION OF THE ABDOMEN**

**SEX**  
**Urinary System**

**Female Spayed**  
The urinary bladder is moderately distended with anechoic urine. The bladder wall, trigone, ureteral papillae and visible urethra (to a depth of 2 cm) appear normal with no evidence of wall thickening, mucosal irregularities, masses or cystic calculi.

**AGE**

**6.5 years**  
The left kidney has a normal shape and size (6.64 cm). Overall echogenicity is normal with adequate corticomedullary distinction and a typical 1:3 cortex:medulla ratio. There is no evidence of perinephric inflammation or effusion. There is no evidence of pyelectasia, nephroliths, infarcts or hydroureter. Renal vasculature is normal.

**WEIGHT**

**50.9 lbs**  
The right kidney has a normal shape and size (7.28 cm). Overall echogenicity is normal with adequate corticomedullary distinction and a typical 1:3 cortex:medulla ratio. There is no evidence of perinephric inflammation or effusion. There is no evidence of pyelectasia, nephroliths, infarcts or hydroureter. Renal vasculature is normal.

**INTERPRETED BY**

Kathleen Sennello  
DVM, MS, Diplomate  
ACVIM (Small Animal  
Internal Medicine)

**Adrenal Glands**

The left adrenal gland is normal in size (0.55 cm at the caudal pole). It is observed in its normal position cranial to the left renal artery. It is normal in appearance (uniformly hypoechoic) and shape with no evidence of a mass effect.

**IMAGING PERFORMED BY**

Emily Kirk

The right adrenal gland is normal in size (0.80 cm at the caudal pole). It is observed in its normal position between the cranial aspect of the right kidney and the caudal vena cava. It is normal in appearance (uniformly hypoechoic) and shape with no evidence of a mass effect.

**HOSPITAL NAME**

Shiloh AH

**Spleen**

The spleen is subjectively normal in size, echotexture is homogenous, and the splenic capsule is smooth with no irregularities. The blood flow through the hilus and splenic parenchyma appears normal. No focal parenchymal abnormalities are visualized.

**REFERRING VET**

Shana Silverstein

**Liver**

The liver is subjectively normal/borderline small in size, and irregular in shape. The parenchyma is heterogenous. The visible portions of the vasculature and biliary tract appear normal. No focal nodules or cystic lesions are observed. The gall bladder lumen is minimally distended. The wall of the gall bladder appears prominent and thickened (0.34 cm). Luminal contents are primarily anechoic. The parenchyma appears irregular and diffusely nodular.

**INVOICE**

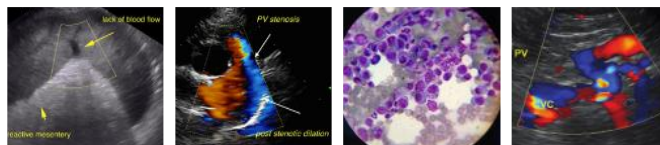
14056

**Gastrointestinal**

**DATE**

8.11.23

The stomach contains minimal luminal contents. It measures at a normal thickness of <0.7 cm with some variability due to the presence of rugal folds. The distinction of the gastric wall layers is adequate and there is no impression of reduced peristaltic activity. No masses or focal lesions were observed.



**PATIENT**

Sadie Deakin

**SPECIES**

Canine

**BREED**

Med Mixed Breed

**SEX**

Female Spayed

**AGE**

6.5 years

**WEIGHT**

50.9 lbs

**INTERPRETED BY**

Kathleen Sennello  
DVM, MS, Diplomate  
ACVIM (Small Animal  
Internal Medicine)

**IMAGING  
PERFORMED BY**

Emily Kirk

**HOSPITAL NAME**

Shiloh AH

**REFERRING VET**

Shana Silverstein

**INVOICE**

14056

**DATE**

8.11.23

The visualized areas of duodenum (0.62 cm), jejunum (0.50 cm) and ileum have a uniform diameter with minimal fluid distension. Wall thickness is increased (enter measurement if given). Bowel loops follow a typical curvilinear path. Some areas have reduced detail of wall layering with mucosal speckling. Visualized peristalsis appears appropriate. There were no focal lesions consistent with obstruction or a mass effect observed.

The ileocecal junction was visualized and exhibited normal intact wall layering and is subjectively of normal thickness. Sections of colon are visualized with formed fecal material and gas shadowing distally. There is no observed focal or generalized colon wall thickening or loss of layering.

**Pancreas**

The pancreas is normal and isoechoic to surrounding mesentery. There is no evidence of nodules or cystic lesions. There is no evidence of regional mesenteric inflammation or fluid.

**Free Abdomen**

Evaluation of the peritoneal cavity did not reveal any evidence of effusion, or subjective lymphadenomegaly. The Medial iliac nodes appear normal and there was no evidence of a caudal aortic thrombus at the bifurcation. The omentum is of normal uniform echogenicity.

**ULTRASONOGRAPHIC FINDINGS**

- Borderline small heterogenous, diffusely nodular liver – The diffuse hepatic changes are non-specific and could be consistent with vacuolar hepatopathy, nodular hyperplasia, inflammatory/immune-mediated disease, fibrosis, extramedullary hematopoiesis, toxic hepatopathy (e.g., copper), infiltrative neoplasia (less likely) or other hepatopathy. The nodular appearance is concerning for a possible cirrhotic liver.
- Thickened gallbladder wall – The gallbladder wall is minimally distended. This could be considered fibrosis, inflammation, etc.
- Diffuse small intestinal thickening with mild mucosal speckling – Bright mucosal speckling has been postulated to represent dilated lacteals or focal accumulations of mucus, cellular debris, etc. in the mucosal crypts.

**INTERPRETATION OF THE FINDINGS & FURTHER RECOMMENDATIONS**

The liver is borderline small and diffusely nodular. Given the history of a chronic bilirubin elevation, there is concern for possible cirrhotic-type changes. It's likely that a biopsy of the liver would be necessary to make this diagnosis (providing coagulation parameters are normal). Recommended, histopathology, cultures and copper quantitation, additionally, screening for Leptospirosis (if this has not already been done).

The gallbladder wall appears somewhat thickened, and the gallbladder is empty. This could be due to fibrosis, inflammation, mild edema, etc. Consider empirical treatment for liver failure with Ursodiol, amoxicillin, +/- lactulose, etc.

There could be concurrent gastrointestinal disease present. I suspect a majority of the symptoms described are due to the suspected liver failure. Empirical treatment for gastroenteritis can be considered.



**PATIENT**

Sadie Deakin

**SPECIES**

Canine

**BREED**

Med Mixed Breed

**SEX**

Female Spayed

**AGE**

6.5 years

**WEIGHT**

50.9 lbs

**INTERPRETED BY**

Kathleen Sennello  
DVM, MS, Diplomate  
ACVIM (Small Animal  
Internal Medicine)

**IMAGING  
PERFORMED BY**

Emily Kirk

**HOSPITAL NAME**

Shiloh AH

**REFERRING VET**

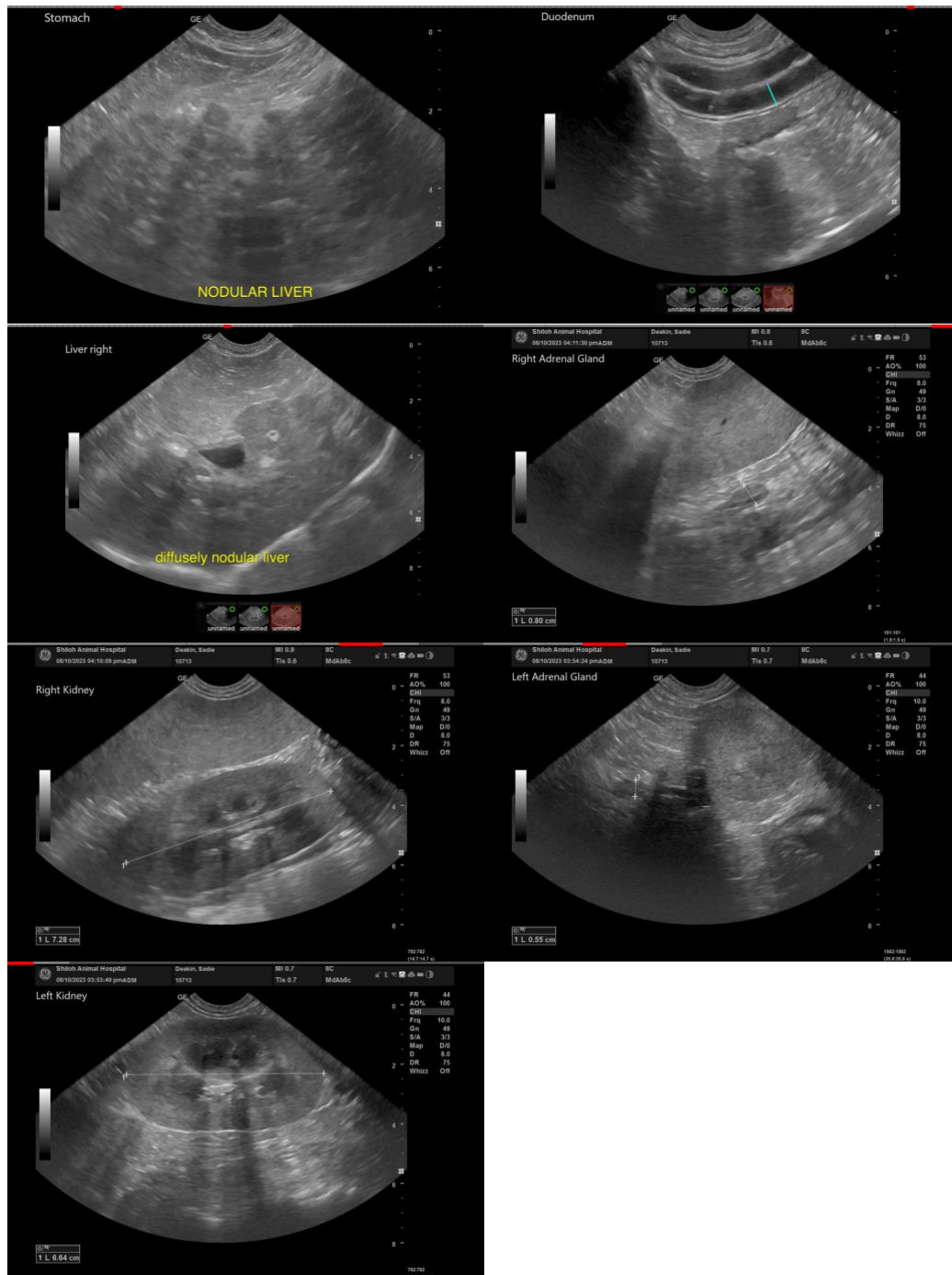
Shana Silverstein

**INVOICE**

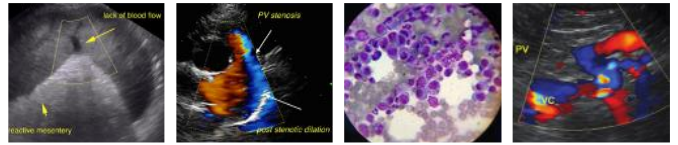
14056

**DATE**

8.11.23



The information and recommendations provided are based on the images presented by the referring veterinarian. No evaluation can be communicated regarding pathology that was not visible in the image/video clips provided.



**PATIENT**

Thank you for this referral. If the clinical or image interpretation does not parallel your findings or if I can be of any further assistance, please contact me.

Sadie Deakin

**SPECIES**

Kathleen Sennello DVM, MS, Diplomate ACVIM (Small animal Internal Medicine)  
[info@SonoPath.com](mailto:info@SonoPath.com)

Canine

**BREED**

Med Mixed Breed

**SEX**

Female Spayed

**AGE**

6.5 years

**WEIGHT**

50.9 lbs

**INTERPRETED BY**

Kathleen Sennello  
DVM, MS, Diplomate  
ACVIM (Small Animal  
Internal Medicine)

**IMAGING  
PERFORMED BY**

Emily Kirk

**HOSPITAL NAME**

Shiloh AH

**REFERRING VET**

Shana Silverstein

**INVOICE**

14056

**DATE**

8.11.23