

**DATE PRESENTING CLINICAL SIGNS**

8.11.2023 Presenting Complaint: Petey was presented to the oncology service today for a consultation regarding his recent diagnosis of right anal sac adenocarcinoma. Since his last visit he has been doing well at home overall but recently his stools have become flatter/more ribbon-like. He is currently taking Benadryl, Fortiflora, and Pepcid.

PATIENT

Petey Stevenson

Current Medications: None listed.

SPECIES

Canine

BREED

German Shepherd Mix

Lab Results: Petey's biopsy confirmed that his right perianal mass was an anal sac adenocarcinoma, a cancer of the cells that line the anal sac in dogs. This cancer can become large enough to impede defecation/urination and has a relatively high risk of metastasis (cancer spread) to other areas such as the regional lymph nodes/lungs as well as of regrowth in its original location. Today Petey has a mass in the area of the left anal sac; I collected a sample for cytology to determine if the swelling is due to cancer or inflammation/infection and the results will help guide recommendations for him.

Date of Previous IntraPet Ultrasound: 6/20/23. See attached.

Sedation: Dexdomitor/Torbugesic prior to sonographer arrival.

Stat Report: Not requested.

Imaging Performed By: Stephanie Warga RDCS, RVT.

SEX

Neutered Male

ULTRASONOGRAPHIC EXAMINATION OF THE ABDOMEN**AGE**

6/4/2012

Urinary System

The urinary bladder is moderately distended with anechoic urine. The bladder wall, trigone, ureteral papillae and visible urethra (to a depth of 2 cm) appear normal with no evidence of wall thickening, mucosal irregularities, masses or cystic calculi.

WEIGHT

76.2lbs

The visualized areas of prostate and surrounding tissue appear normal. Unfortunately, the prostate is not fully visualized likely due to its intrapelvic location. Correlate with rectal exam findings.

INTERPRETED BY

Kathleen Sennello
DVM, MS, Diplomate
ACVIM (Small Animal
Internal Medicine)

The left kidney has a normal shape and size (6.86 cm). Overall echogenicity is normal with adequate corticomedullary distinction and a typical 1:3 cortex:medulla ratio. There is no evidence of perinephric inflammation or effusion. There is no evidence of pyelectasia, nephroliths, infarcts or hydronephrosis. Renal vasculature is normal.

The right kidney has a normal shape and size (7.22 cm). Overall echogenicity is normal with adequate corticomedullary distinction and a typical 1:3 cortex:medulla ratio. There is no evidence of perinephric inflammation or effusion. There is no evidence of pyelectasia, nephroliths, infarcts or hydronephrosis. Renal vasculature is normal.

HOSPITAL NAME

Festival VC

Adrenal Glands

The left adrenal gland is normal in size (0.66 cm at the cranial pole / 0.78 cm at the caudal pole / 2.89 cm in length). It is observed in its normal position cranial to the left renal artery. It is slightly abnormal in appearance in that there is an ill-defined hyperechoic nodule in the caudal pole (measuring 0.74 x 0.49 cm) which does not deviate the margins of the adrenal gland. No evidence of vascular invasion is visualized.

REFERRING VET

Dr. Beron

The right adrenal gland is normal in size (1.22 cm at the cranial pole / 0.66 cm at the caudal pole / 2.51 cm in length). It is observed in its normal position between the cranial aspect of the right kidney and the caudal vena cava. It is normal in appearance (uniformly hypoechoic) and shape with no evidence of a mass effect.

INVOICE

14064

Spleen

The spleen is subjectively normal in size, echotexture is homogenous, and the splenic capsule is smooth with no irregularities. The blood flow through the hilus and splenic parenchyma appears normal. No focal parenchymal abnormalities are visualized.

Liver

The liver is subjectively normal in size, and echogenicity with smooth peripheral margins. The parenchyma is homogenous echotexture. The visible portions of the vasculature and biliary tract appear normal. No focal nodules or cystic lesions are observed. The gall bladder lumen is moderately distended. The wall of the gall bladder is not thickened and has a smooth mucosal surface. Luminal contents are primarily anechoic. There is an ill-defined hypoechoic nodule visualized within the parenchyma (measuring 3.81 x 2.45 cm).

The gallbladder is moderately distended with echogenic debris. Additionally, there is hyperechoic shadowing debris consistent with mineralized sandy debris. There is no evidence of gallbladder wall thickening or surrounding inflammation. The bile duct is normal/not visualized.

Gastrointestinal

The stomach contains mild fluid/air. It measures at a normal thickness of <0.7 cm with some variability due to the presence of rugal folds. The distinction of the gastric wall layers is adequate and there is no impression of reduced peristaltic activity. No masses or focal lesions were observed.

The visualized areas of duodenum, jejunum and ileum have a relatively uniform diameter with minimal fluid distension. Wall thickness is normal. Bowel loops follow a curvilinear path with distinct wall layering maintaining the typical 1:3 muscularis:mucosa layer ratio. The duodenum measured as normal (0.57 cm) and the jejunum measured as normal (0.36 cm) Visualized peristalsis appears appropriate. There were no focal lesions consistent with obstruction or a mass effect observed.

Sections of colon are visualized with formed fecal material and gas shadowing distally. There is no observed focal or generalized colon wall thickening or loss of layering.

Pancreas

region of the pancreas is normal and isoechoic to surrounding mesentery. There is no evidence of nodules or cystic lesions. There is no evidence of regional mesenteric inflammation or fluid.

Free Abdomen

Evaluation of the peritoneal cavity did not reveal any evidence of effusion, or subjective lymphadenomegaly. There are prominent lymph nodes visualized at the iliac trifurcation. In transverse view, they measure 0.60 x 1.35 cm and 0.92 x 0.94 cm. In the sagittal view, a lymph node is visualized (measuring 1.10 x 1.65 cm). Additionally, there are occasional mildly prominent mesenteric lymph nodes visualized (an example of which measures 0.45 cm). The omentum is generally of normal echogenicity.

ULTRASONOGRAPHIC FINDINGS

- Small, ill-defined hyperechoic nodule in the caudal pole of the left adrenal – This lesion appears stable from the previous measurement. It is likely most consistent with a focal area of hyperplasia.
- Ill-defined hypoechoic nodule/small mass visualized in the liver – This could represent a benign or a neoplastic process (large regenerative nodule, hyperplasia, carcinoma, adenoma, other).
- Moderate gallbladder debris with sandy, dependent shadowing debris –The significance of the aggregated gallbladder debris is unclear. This could represent an early mucocele, cholestasis, or may be secondary to fasting but seems unlikely to be causing a current issue. Recommend continued monitoring.
- Prominent/mildly enlarged iliac lymph nodes. These lymph nodes are modestly enlarged, most consistent with reactive lymph nodes, although metastatic disease cannot be ruled out.

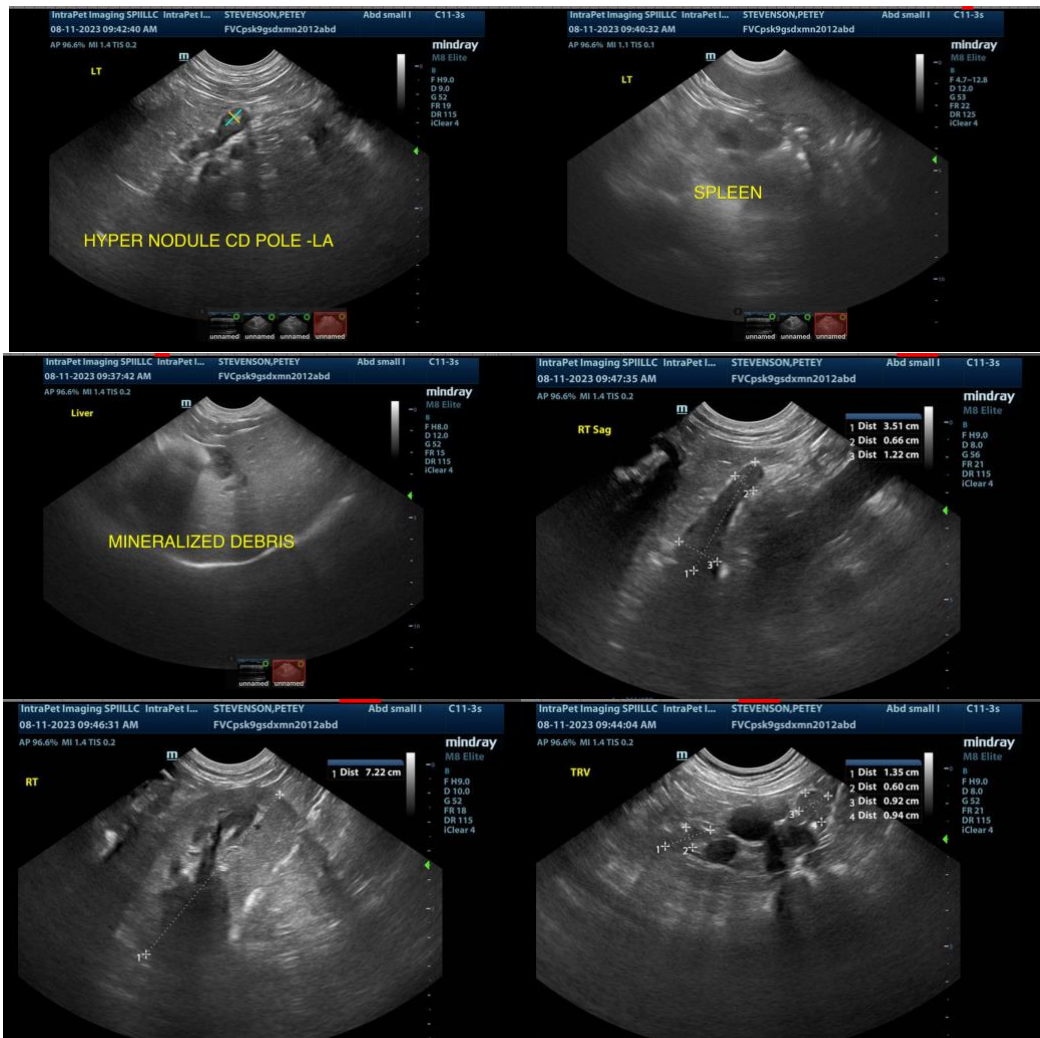
INTERPRETATION OF THE FINDINGS & FURTHER RECOMMENDATIONS

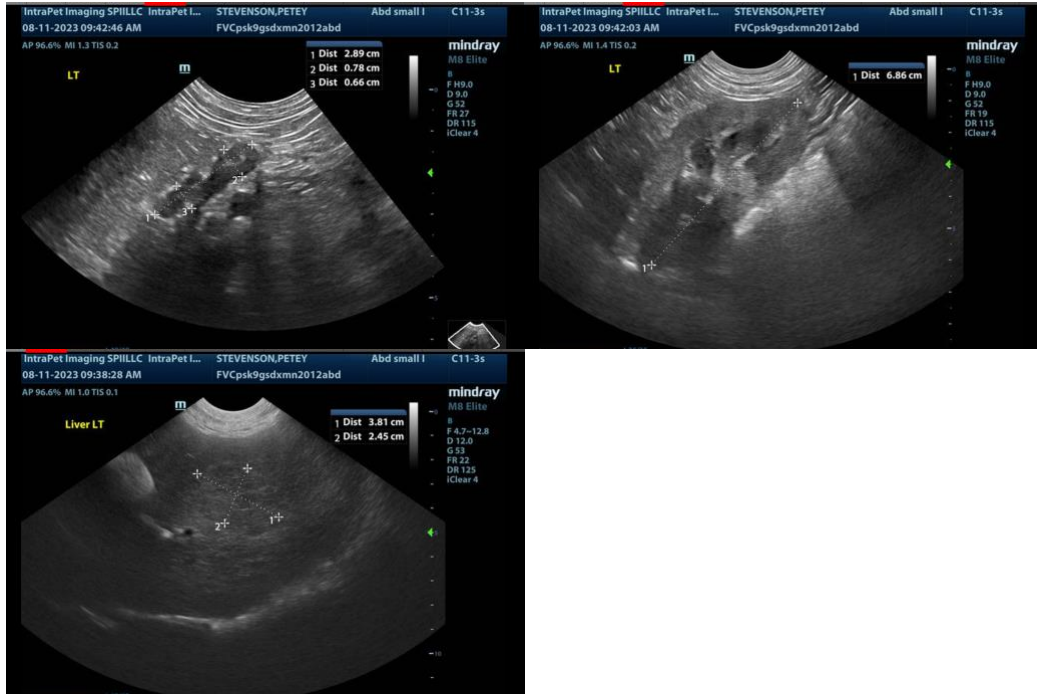
The iliac lymph nodes are visualized and are prominent, but not severely enlarged. These changes are currently most consistent with reactive lymph nodes rather than metastatic disease, although continued monitoring is warranted.

There is a subtle, ill-defined, hypoechoic nodule/small mass effect visualized within the liver. The appearance of this lesion trend toward a more benign process, although it is of significant size. Options moving forward would include continued monitoring or possibly a fine-needle aspirate (if a window for sampling can be obtained).

The hyperechoic nodule in the caudal pole of the left adrenal gland is stable from the previous exam and likely represents a benign lesion. Continued monitoring is warranted.

The significance of the gallbladder debris is uncertain at this time. Correlate with lab-work findings if liver enzyme elevations are present, consider Ursodiol therapy and continued monitoring of the gallbladder and lab-work.





The information and recommendations provided are based on the images presented by the referring veterinarian. No evaluation can be communicated regarding pathology that was not visible in the image/video clips provided.

Thank you for this referral. If the clinical or image interpretation does not parallel your findings or if I can be of any further assistance, please contact me.

Kathleen Sennello DVM, MS, Diplomate ACVIM (Small animal Internal Medicine)
info@SonoPath.com