

**PATIENT**

Chloe Banks

SPECIES

Canine

BREED

Maltese

SEX

Spayed Female

AGE

12.5 Years

WEIGHT

6.88 Pounds

INTERPRETED BYKathleen Sennello DVM,
MS, Diplomate ACVIM
(Small Animal Internal
Medicine)**IMAGING
PERFORMED BY**

Amy Mayhew, LVT

HOSPITAL NAME

SVS Imaging MI

REFERRING VET

Union Lake VH

INVOICE

40349

DATE

8/11/22

PRESENTING CLINICAL SIGNS

Recheck ultrasound (due 4-6 weeks after starting Ursodiol). Wanting to recheck splenic nodule, gallbladder, etc.

Abnormal PE/Chem/CBC/UA Results: Liver values have improved in the last two months (went down significantly).

ULTRASONOGRAPHIC EXAMINATION OF THE ABDOMEN**Urinary System**

The urinary bladder is moderately distended with anechoic urine. The Bladder wall, trigone, ureteral papillae and visible urethra (to a depth of 2cm) appear normal with no evidence of wall thickening, mucosal irregularities, masses or cystic calculi.

The left kidney has a normal shape and size (3.49 cm). Overall echogenicity is normal with adequate corticomedullary distinction and a typical 1:3 cortex:medulla ratio. There is no evidence of perinephric inflammation or effusion. There is no evidence of pyelectasia, nephroliths, infarcts or hydroureter. Renal vasculature is normal.

The right kidney has a normal shape and size (3.66 cm). Overall echogenicity is normal with adequate corticomedullary distinction and a typical 1:3 cortex:medulla ratio. There is no evidence of perinephric inflammation or effusion. There is no evidence of pyelectasia, nephroliths, infarcts or hydroureter. Renal vasculature is normal.

Adrenal Glands

The left adrenal gland is normal in size measuring 0.55 cm at the caudal pole. It is observed in its normal position cranial to the left renal artery. It is normal in appearance (uniformly hypoechoic) and shape with no evidence of a mass effect.

The right adrenal gland is normal in size measuring 0.54 cm at the caudal pole. It is observed in its normal position between the cranial aspect of the right kidney and the caudal vena cava. It is normal in appearance (uniformly hypoechoic) and shape with no evidence of a mass effect.

Spleen

The spleen is subjectively normal in size, echotexture is homogenous, and the splenic capsule is smooth with no irregularities. The blood flow through the hilus and splenic parenchyma appears normal. There is an ill-defined hyperechoic lesion visualized at the hilus that measures 0.96 cm x 1.3 cm. The appearance of this lesion is similar to the previous scan on 6/23/22. At that time, the lesion measured 0.88 cm x 1.04 cm. This is consistent with a stable/slightly larger lesion.

Liver

The liver is large in size with smooth peripheral margins. The parenchyma is hyperechoic and homogenous in echotexture. The visible portions of the vasculature and biliary tract appear normal. No focal nodules or cystic lesions are observed.

The gall bladder lumen is significantly distended. Some areas of the wall appear mildly thickened with adherent debris. There is a large amount of primarily non-organized echogenic debris present, but some of this is forming mild mucosal stranding along the wall of the gallbladder, consistent with an early mucocele. There is no evidence of bile duct dilation.

IMAGING PERFORMED BYSVS Mobile Imaging MI 734-637-7711
svsimagingmi@gmail.com**PATIENT**

Chloe Banks

SPECIES

Canine

BREED

Maltese

SEX

Spayed Female

AGE

12.5 Years

WEIGHT

6.88 Pounds

INTERPRETED BYKathleen Sennello DVM,
MS, Diplomate ACVIM
(Small Animal Internal
Medicine)**IMAGING PERFORMED BY**

Amy Mayhew, LVT

HOSPITAL NAME

SVS Imaging MI

REFERRING VET

Union Lake VH

INVOICE

40349

DATE

8/11/22

Gastrointestinal

The stomach contains minimal luminal contents. It measures at a normal thickness of <0.7cm with some variability due to the presence of rugal folds. The distinction of the gastric wall layers is adequate and there is no impression of reduced peristaltic activity. No masses or focal lesions were observed.

The visualized areas of duodenum, jejunum and ileum have a uniform diameter with minimal fluid distension. Wall thickness is normal to slightly increased. Bowel loops follow a typical curvilinear path with distinct wall layering, but some areas display a prominent muscularis layer which does not display the typical 1:3 muscularis:mucosa layer ratio. Duodenum wall measured 0.39 cm. Jejunum wall measured 0.32 cm. There is diffuse mucosal speckling evident. Visualized peristalsis appears appropriate. There were no focal lesions consistent with obstruction or a mass effect observed.

The ileocecal junction was visualized and exhibited normal intact wall layering and is subjectively of normal thickness. Sections of colon are visualized with formed fecal material and gas shadowing distally. There is no observed focal or generalized colon wall thickening or loss of layering.

Pancreas

The pancreas is normal and isoechoic to surrounding mesentery. There is no evidence of nodules or cystic lesions. There is no evidence of regional mesenteric inflammation or fluid.

Free Abdomen

Evaluation of the peritoneal cavity did not reveal any evidence of effusion, or subjective lymphadenomegaly. The Medial iliac nodes appear normal and there was no evidence of a caudal aortic thrombus at the bifurcation. The omentum is of normal uniform echogenicity.

ULTRASONOGRAPHIC FINDINGS

- Mixed echogenic, irregular, hyperechoic lesion at the hilus of the spleen – The significance of this lesion remains unknown. It appears relatively stable and measures as stable/slightly larger. Recommend reevaluation in 3 months.
- Large, hyperechoic liver – The diffuse hepatic changes are non-specific and can be seen with vacuolar hepatopathy, reactive change, nodular hyperplasia or, less likely, inflammatory/immune-mediated disease, infiltrative neoplasia, or other hepatopathy.
- Large gallbladder sludge with early peripheral organization – Concerning for an early developing gallbladder mucocele. This lesion appears stable, but not dramatically improved.
- Subjective thickening of the small intestine with mucosal speckling – Bright mucosal speckling has been proposed to represent dilated lacteals or focal accumulation of mucus, cellular debris etc.. in the mucosal crypts of the small intestine.

INTERPRETATION OF THE FINDINGS & FURTHER RECOMMENDATIONS

The two lesions being reevaluated on today's exam appear relatively stable. Unfortunately, the gallbladder does not appear dramatically improved. Per the history, liver enzyme values are improved, which is great. Options moving forward would include chronic/lifelong Ursodiol with frequent bloodwork evaluation and ultrasound recheck (3-4 months?), longer if stable for an extended period of time, or you could consider surgical cholecystectomy with a liver biopsy. This is by no means an emergency, but my suspicion is that this lesion will not go away. It is unknown if it will progress to a surgical lesion.

IMAGING PERFORMED BY

SVS Mobile Imaging MI 734-637-7711
svsimagingmi@gmail.com



EDUCATIONAL TELECONSULTATION SERVICES™
1-800-838-4268 info@sonopath.com SonoPath.com

PATIENT

Chloe Banks

The splenic lesion appears similar to the previous scan. It measures at slightly larger, but it is an irregular lesion and difficult to obtain repeatable margins.

SPECIES

Canine

Of note on today's scan was the mucosal speckling observed in the small intestine. If this patient has a history of GI signs, hypoalbuminemia, etc., this could represent underlying gastrointestinal disease. If cholecystectomy is being performed, consider obtaining GI biopsies.

BREED

Maltese

SEX

Spayed Female

AGE

12.5 Years

WEIGHT

6.88 Pounds

INTERPRETED BY

Kathleen Sennello DVM,
MS, Diplomate ACVIM
(Small Animal Internal
Medicine)

IMAGING PERFORMED BY

Amy Mayhew, LVT

HOSPITAL NAME

SVS Imaging MI

REFERRING VET

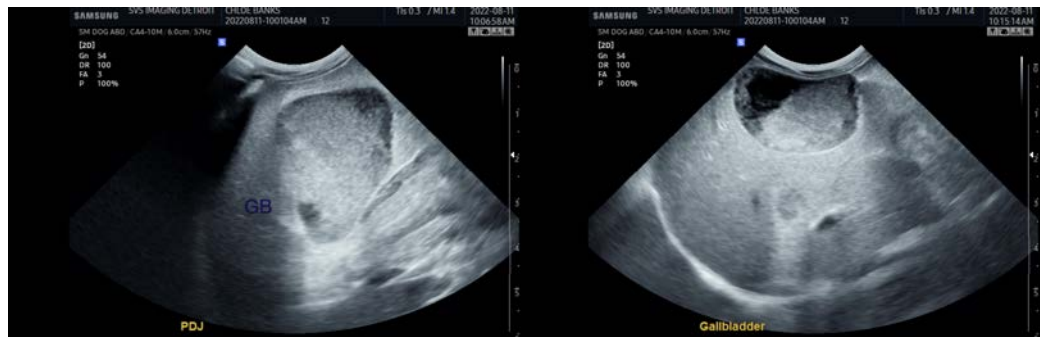
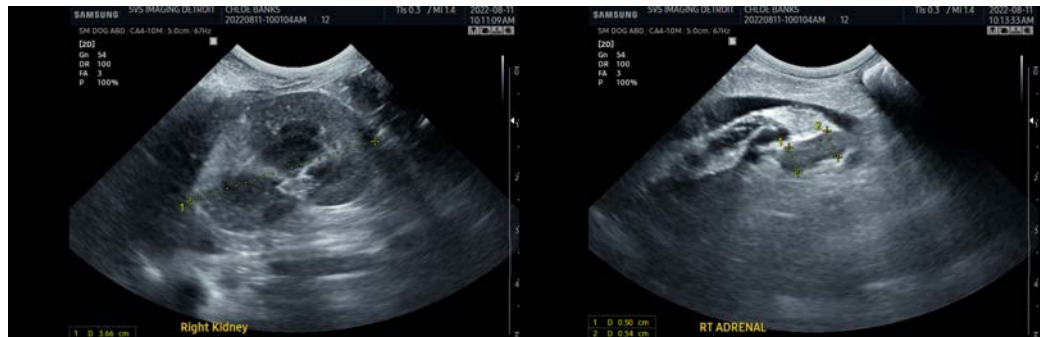
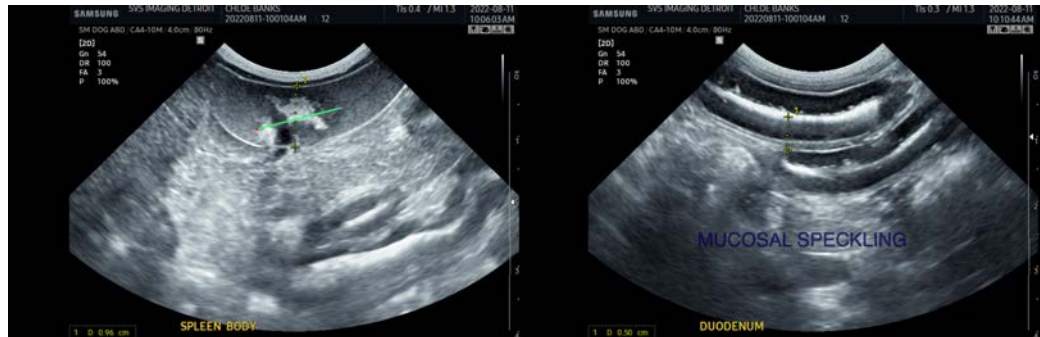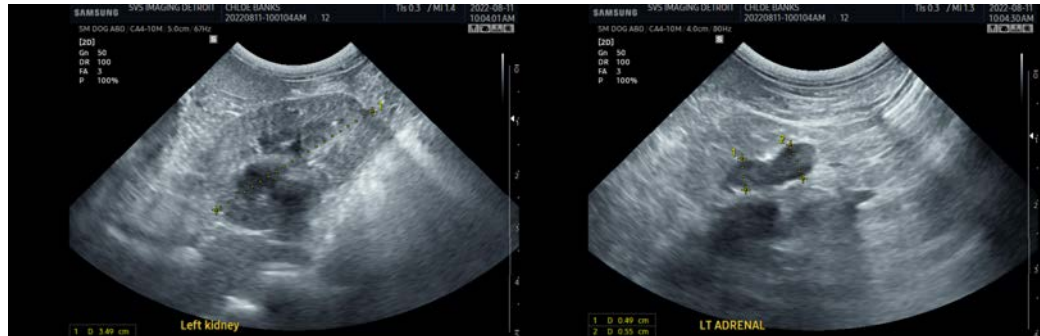
Union Lake VH

INVOICE

40349

DATE

8/11/22



IMAGING PERFORMED BY

SVS Mobile Imaging MI 734-637-7711
svsimagingmi@gmail.com



EDUCATIONAL TELECONSULTATION SERVICES™
1-800-838-4268 info@sonopath.com SonoPath.com

PATIENT

Chloe Banks

SPECIES

Canine

BREED

Maltese

SEX

Spayed Female

AGE

12.5 Years

WEIGHT

6.88 Pounds

INTERPRETED BY

Kathleen Sennello DVM,
MS, Diplomate ACVIM
(Small Animal Internal
Medicine)

**IMAGING
PERFORMED BY**

Amy Mayhew, LVT

HOSPITAL NAME

SVS Imaging MI

REFERRING VET

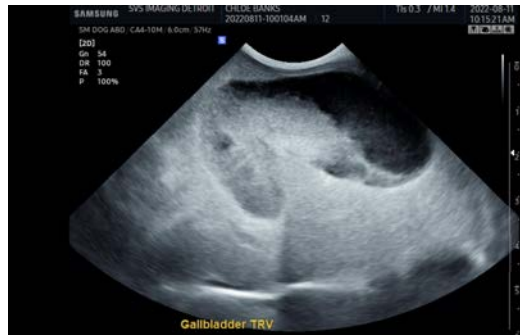Union Lake VH

INVOICE

40349

DATE

8/11/22



The information and recommendations provided are based on the images presented by the referring veterinarian/sonographer. No evaluation can be communicated regarding pathology that was not visible in the image/video clips provided.

Thank you for this referral. If the clinical or image interpretation does not parallel your findings or if I can be of any further assistance please contact me.

Kathleen Sennello DVM,MS, Diplomate ACVIM (Small animal Internal Medicine)

kathleen.sennello@sonopath.com