

**DATE**

8/11/21

**PRESENTING CLINICAL SIGNS**

History: Acute on chronic renal failure, heart murmur with LVOT and SAM with mitral disease on echo in 2020.

**PATIENT**

Rory Rose King

Current Medications: started on 8/9/10: Unasyn 22 mg/kg bid, Cerenia 1 mg/kg sid, Protonix 1 mg/kg sid, Buprenorphine 0.01 mg/kg bid, Entyce 2 mg/kg sid, and has been on LRS with KCL supplementation.

Lab Results: Marked elevation of SDMA, BUN, CREAT, PHOS, and hypokalemia.

Date of Previous IntraPet Ultrasound: Previous echo only.

Sedation: Not needed.

Stat Report: Not requested/declined.

**SPECIES**

Feline

**ULTRASONOGRAPHIC EXAMINATION OF THE ABDOMEN****BREED**

Domestic Shorthair

**Urinary System**

The urinary bladder is moderately distended with anechoic urine. The Bladder wall, trigone, ureteral papillae and visible urethra (to a depth of 2cm) appear normal with no evidence of wall thickening, mucosal irregularities, masses or cystic calculi.

**SEX**

Spayed Female

The left kidney is irregular in shape and normal/small in size (2.76 cm). Overall echogenicity is hyperechoic with poor corticomedullary distinction and a typical 1:3 cortex:medulla ratio. There is no evidence of perinephric inflammation or effusion. There is mild pyelectasia present at 0.24 cm and small, non-obstructive nephroliths that measured 0.15-0.2 cm. The irregular in shape is due to the presence of previous infarcts, but there is no evidence of hydroureter. Renal vasculature is normal.

**AGE**

2010

The left kidney is irregular in shape and normal/small in size (2.61 cm). Overall echogenicity is hyperechoic with poor corticomedullary distinction and a typical 1:3 cortex:medulla ratio. There is no evidence of perinephric inflammation or effusion. There is mild pyelectasia present at 0.24 cm and small, non-obstructive nephroliths that measured 0.12-0.15 cm. The irregular in shape is due to the presence of previous infarcts, but there is no evidence of hydroureter. Renal vasculature is normal.

**WEIGHT**

7 lbs

**INTERPRETED BY**

Kathleen Sennello  
DVM, MS, Diplomate  
ACVIM (Small Animal  
Internal Medicine)

**Adrenal Glands**

The left adrenal gland is normal in size measuring 0.4 cm at the caudal pole. It is observed in its normal position cranial to the left renal artery. It is normal in appearance (uniformly hypoechoic) and shape with no evidence of a mass effect.

**HOSPITAL NAME**

Perry Hall AH

The right adrenal gland is normal in size measuring 0.38 cm at the caudal pole. It is observed in its normal position between the cranial aspect of the right kidney and the caudal vena cava. It is normal in appearance (uniformly hypoechoic) and shape with no evidence of a mass effect.

**REFERRING VET**

Dr. Hatzigiannakis

**Spleen**

The spleen is subjectively normal in size, echotexture is homogenous, and the splenic capsule is smooth with no irregularities. The blood flow through the hilus and splenic parenchyma appears normal. No focal parenchymal abnormalities are visualized.

**INVOICE**

91143

**Liver**

The liver is subjectively normal in size, and echogenicity with smooth peripheral margins. The parenchyma is homogenous echotexture. The visible portions of the vasculature and biliary tract appear normal. No focal nodules or cystic lesions are observed. The gallbladder lumen is moderately distended. The wall of the gall bladder is not thickened and has a smooth mucosal surface. Luminal contents are primarily anechoic. The cystic and common bile ducts are normal/not visible.

### ***Gastrointestinal***

The stomach is moderately dilated with fluid and irregular shadowing material most consistent with normal ingesta and gas. It measures at a normal thickness of <0.36 cm with some variability due to the presence of rugal folds. The distinction of the gastric wall layering is adequate and there is no impression of reduced peristaltic activity. No masses or focal lesions were observed.

The visualized areas of duodenum, jejunum and ileum have a uniform diameter with minimal fluid distension. Wall thickness is normal to slightly increased. Bowel loops follow a typical curvilinear path with distinct wall layering, but some areas display a prominent muscularis layer which does not display the typical 1:3 muscularis:mucosa layer ratio. The jejunum measured 0.2 cm. Visualized peristalsis appears appropriate. There were no focal lesions consistent with obstruction or a mass effect observed.

The ileocecal junction was visualized and exhibited normal intact wall layering and is subjectively of normal thickness. Sections of colon are visualized with formed fecal material and gas shadowing distally. There is no observed focal or generalized colon wall thickening or loss of layering.

### ***Pancreas***

The pancreas is prominent and hypoechoic as compared to the surrounding isoechoic mesentery. There is no evidence of nodules or cystic lesions. There is no evidence of regional mesenteric inflammation or fluid.

### ***Free Abdomen***

Evaluation of the peritoneal cavity did not reveal any evidence of effusion, or subjective lymphadenomegaly. The Medial iliac nodes appear normal and there was no evidence of a caudal aortic thrombus at the bifurcation. The omentum is of normal uniform echogenicity.

## **ULTRASONOGRAPHIC FINDINGS**

### **PRIMARY FINDINGS:**

- Decreased corticomedullary distinction in both kidneys with evidence of previous infarcts, mild pyelectasia and non-obstructive nephroliths. Mild loss of corticomedullary distinction in both kidneys could be consistent with chronic degenerative disease or interstitial nephrosis. Pyelectasia of the left/right kidney could be consistent with pyelonephritis, chronic renal disease, secondary to PU/PD or fluid therapy (if applicable), other. The hyperechoic mineralized foci observed at the corticomedullary junction of the left/right kidney are consistent with small, non-obstructive nephroliths.
- Hypoechoic pancreas with prominent pancreatic duct. The pancreatic changes are most consistent with mild pancreatitis or a recent episode of pancreatic inflammation.

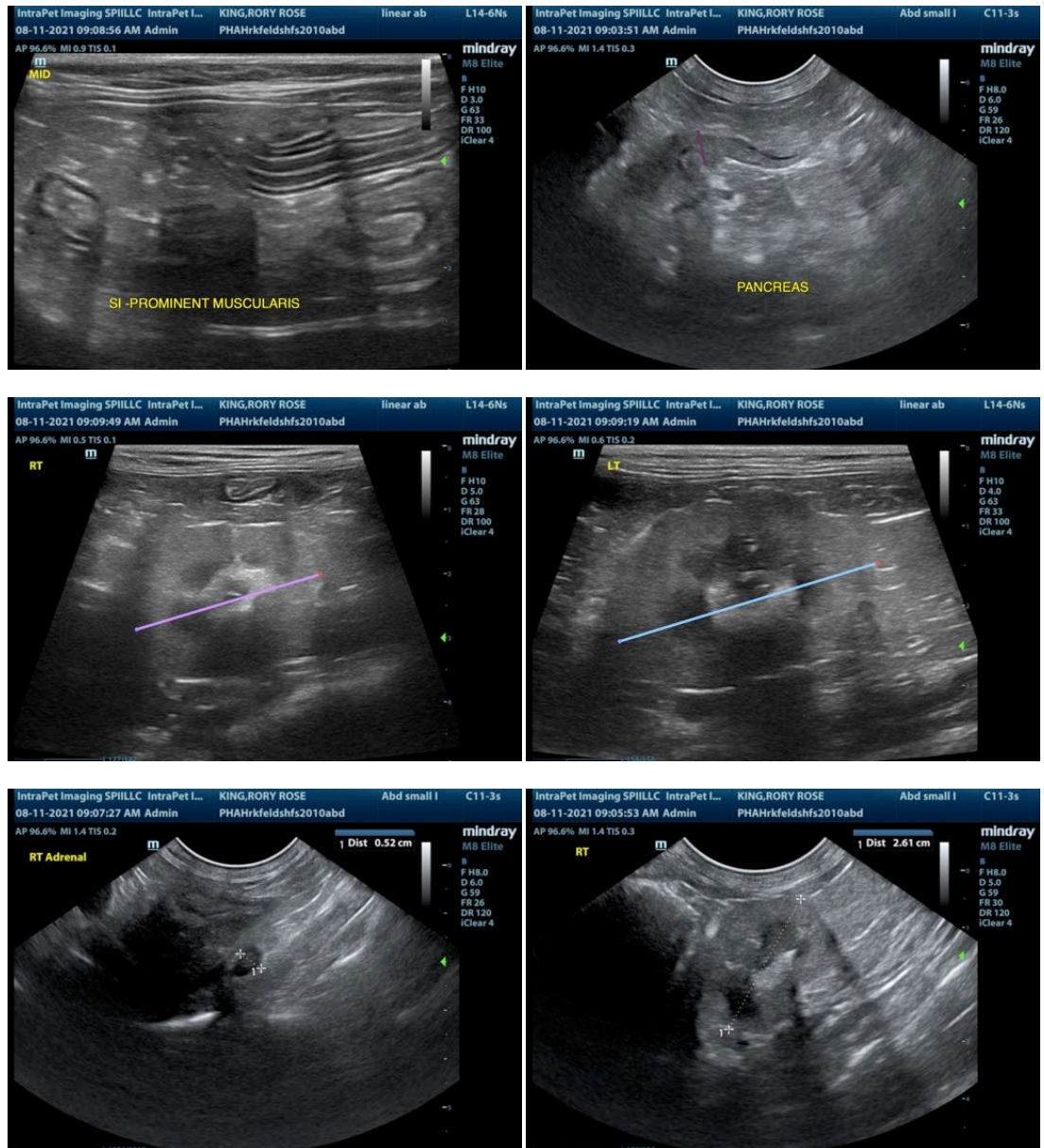
### **SECONDARY FINDINGS:**

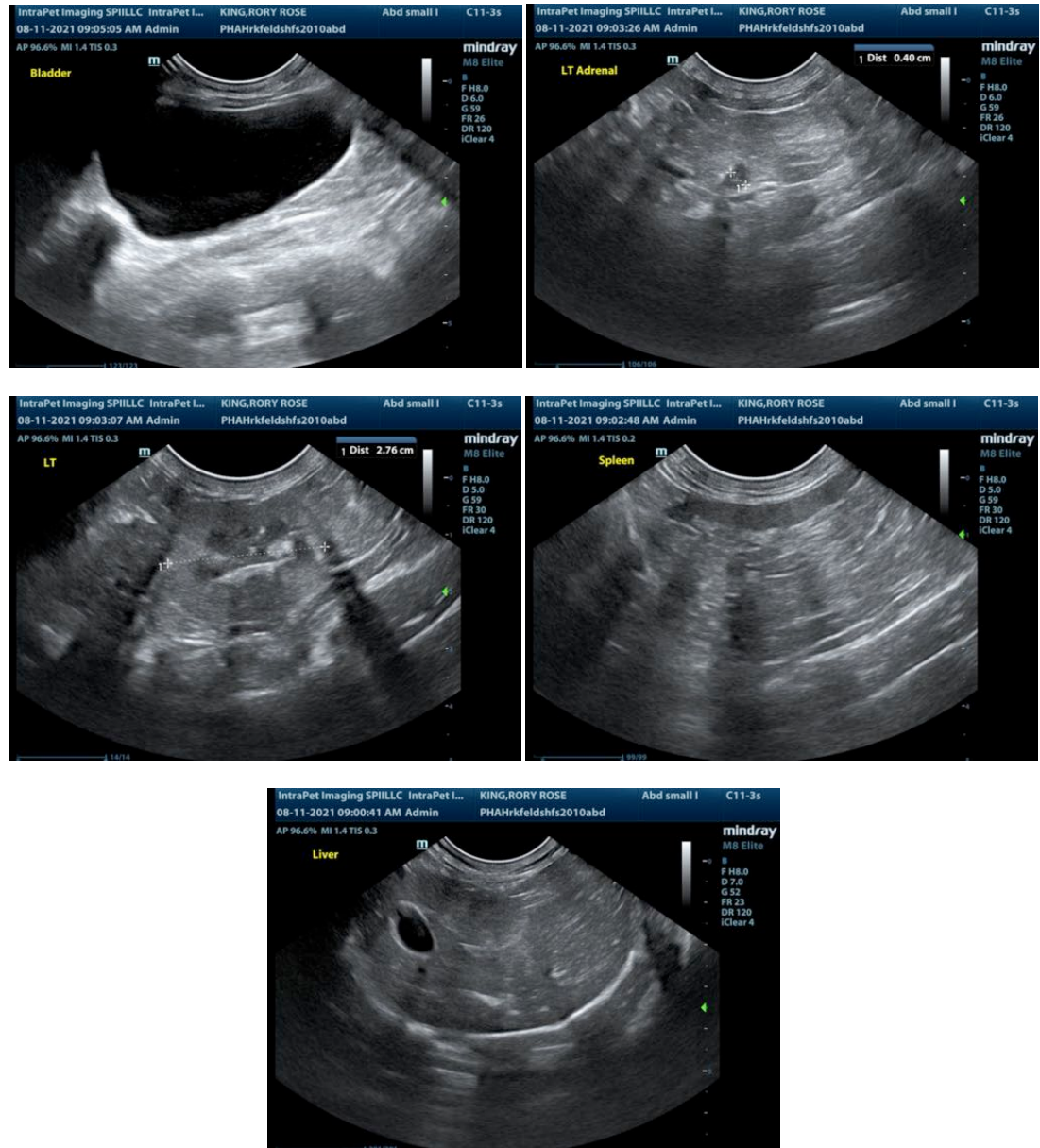
- Prominent muscularis layer of the small intestine. The small intestinal wall changes are most consistent with an inflammatory process (i.e., inflammatory bowel disease) with a low possibility of emerging lymphoma. This can be a normal finding in older cats as well.

## **INTERPRETATION OF THE FINDINGS & FURTHER RECOMMENDATIONS**

The renal changes observed are consistent with the biochemical changes reported. This patient has chronic renal disease and hopefully an acute crisis that can be stabilized? You have done a nice job stabilizing this patient. Consider things like urinalysis, culture, urine protein to creatinine ratio, blood pressure, diuresis, empirical antibiotics, nausea medications, gastroprotectants, etc. (I believe you are already doing much of this). There is no evidence of confounding issues such as obstructions, masses, etc.

The pancreatic and small intestinal changes are mild and likely incidental. I recommend to continue to monitor.





The information and recommendations provided are based on the images presented by the referring veterinarian. No evaluation can be communicated regarding pathology that was not visible in the image/video clips provided.

Thank you for this referral. If the clinical or image interpretation does not parallel your findings or if I can be of any further assistance please contact me.

Kathleen Sennello DVM,MS, Diplomate ACVIM (Small animal Internal Medicine)  
 kathleen.sennello@sonopath.com