



PATIENT

Angel Wallin

PRESENTING CLINICAL SIGNS

History: Seems uncomfortable during urination, hematuria (recurring) Physical Exam Findings/Reason for Ultrasound: Glucosuria, hematuria, discomfort when urinating, reticulocytosis Lab Work Attached for Review? yes Radiographs Attached for Review? no Additional Information: spoke w/ internist and leptospirosis on r/o list. Test submitted.
Abnormal PE/Chem/CBC/UA Results: LABS attached

SPECIES

Canine

BREED

Maltese X

ULTRASONOGRAPHIC EXAMINATION OF THE ABDOMEN

Urinary System

SEX

Spayed Female

The urinary bladder is moderately distended with anechoic urine. The Bladder wall, trigone, ureteral papillae and visible urethra (to a depth of 2cm) appear normal with no evidence of wall thickening, mucosal irregularities, masses or cystic calculi.

AGE

5 Years

The left kidney has a normal shape and is normal to slightly enlarged in size (4.58 cm). Overall echogenicity is slightly hyperechoic with poor corticomedullary distinction and a typical 1:3 cortex:medulla ratio. There are pinpoint non-obstructive nephroliths and pyelectasia measuring 0.36 cm. There is no evidence of perinephric inflammation or effusion. Renal vasculature is normal.

WEIGHT

16.2 Pounds

The right kidney has a normal shape and size (4.66 cm). Overall echogenicity is slightly hyperechoic with poor corticomedullary distinction and a typical 1:3 cortex:medulla ratio. There is no evidence of perinephric inflammation or effusion. Pyelectasis is noted at 0.42 cm and pinpoint non-obstructive nephroliths. Renal vasculature is normal.

Adrenal Glands

INTERPRETED BY

Kathleen Sennello DVM,
MS, Diplomate ACVIM
(Small Animal Internal
Medicine)

The left adrenal gland is normal in size measuring 0.39 cm at the caudal pole. It is observed in its normal position cranial to the left renal artery. It is normal in appearance (uniformly hypoechoic) and shape with no evidence of a mass effect.

The right adrenal gland is normal in size measuring 0.55 cm at the caudal pole. It is observed in its normal position between the cranial aspect of the right kidney and the caudal vena cava. It is normal in appearance (uniformly hypoechoic) and shape with no evidence of a mass effect.

IMAGING PERFORMED BY

Loetitia Saint-Jacques, RVT

Spleen

HOSPITAL NAME

Advanced PetCare of
Nevada

The spleen is large in size. The spleen echotexture is heterogenous and mottled, the splenic capsule is smooth with no irregularities. The blood flow through the hilus and splenic parenchyma appears normal. No focal parenchymal abnormalities are visualized.

Liver

REFERRING VET

Dr. Sarah Behrens

The liver is large in size, and echogenicity with smooth peripheral margins. The parenchyma is heterogenous in echotexture with subtle, indistinct focal mottling. The visible portions of the vasculature and biliary tract appear normal. No focal nodules or cystic lesions are observed.

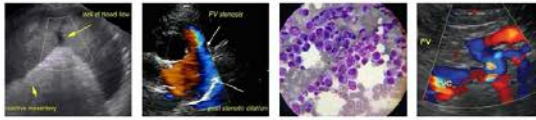
INVOICE

24591

The gallbladder lumen is moderately distended. The wall of the gall bladder is not thickened and has a smooth mucosal surface. Luminal contents are primarily anechoic. The cystic and common bile ducts are normal/not visible.

DATE

8/11/21



PATIENT

Angel Wallin

Gastrointestinal

The stomach contains minimal luminal contents. It measures at a normal thickness of <0.7cm with some variability due to the presence of rugal folds. The distinction of the gastric wall layers is adequate and there is no impression of reduced peristaltic activity. No masses or focal lesions were observed.

SPECIES

Canine

The visualized areas of duodenum, jejunum and ileum have a relatively uniform diameter with minimal fluid distension. Wall thickness is normal. Bowel loops follow a curvilinear path with distinct wall layering maintaining the typical 1:3 muscularis:mucosa layer ratio. Jejunum wall measures 0.24, 0.33 cm. Visualized peristalsis appears appropriate. There were no focal lesions consistent with obstruction or a mass effect observed.

BREED

Maltese X

SEX

Spayed Female

The ileocecal junction was visualized and exhibited normal intact wall layering and is subjectively of normal thickness. Sections of colon are visualized with formed fecal material and gas shadowing distally. There is no observed focal or generalized colon wall thickening or loss of layering.

Pancreas

AGE

5 Years

The pancreas is prominent and mottled compared to the surrounding isoechoic mesentery. There is no evidence of nodules or cystic lesions. There is no evidence of regional mesenteric inflammation or fluid.

Free Abdomen

WEIGHT

16.2 Pounds

Evaluation of the peritoneal cavity revealed scant anechoic free fluid around the spleen. No lymphadenomegaly. The Medial iliac nodes appear normal and there was no evidence of a caudal aortic thrombus at the bifurcation. The omentum appears to be of increased echogenicity in the cranial abdomen and around the spleen.

INTERPRETED BY

Kathleen Sennello DVM,
MS, Diplomate ACVIM
(Small Animal Internal
Medicine)

Other

A brief view of the heart was submitted. No pericardial effusion was seen.

IMAGING PERFORMED BY

Loetitia Saint-Jacques, RVT

ULTRASONOGRAPHIC FINDINGS

- Decreased corticomedullary distinction in both kidneys with bilateral pyelectasia and rare non-obstructive nephroliths – Mild loss of corticomedullary distinction in both kidneys could be consistent with chronic degenerative disease or interstitial nephrosis. Pyelectasia of the left/right kidney could be consistent with pyelonephritis, chronic renal disease, secondary to PU/PD or fluid therapy (if applicable), other.
- Large, mottled spleen – The diffuse splenic changes are non-specific and could be consistent with lymphoid hyperplasia, extramedullary hematopoiesis, infiltrative neoplasia, inflammation, other. Cytology or histopathology would be necessary to get a definitive diagnosis.
- Prominent, mottled pancreas with surrounding mildly hyperechoic mesentery – The pancreatic changes are most consistent with mild pancreatitis or a recent episode of pancreatic inflammation.
- Heterogeneous liver – The diffuse hepatic changes are non-specific and could be consistent with vacuolar hepatopathy, nodular hyperplasia, inflammatory/immune-mediated disease, fibrosis, extramedullary hematopoiesis, toxic hepatopathy (e.g., copper), infiltrative neoplasia (less likely) or other hepatopathy.

HOSPITAL NAME

Advanced PetCare of
Nevada

REFERRING VET

Dr. Sarah Behrens

INVOICE

24591

DATE

8/11/21



PATIENT

Angel Wallin

INTERPRETATION OF THE FINDINGS & FURTHER RECOMMENDATIONS

SPECIES

Canine

BREED

Maltese X

SEX

Spayed Female

AGE

5 Years

WEIGHT

16.2 Pounds

No obvious lesions were observed in the urinary bladder or urethra to explain the lower urinary tract signs. I'm wondering if it might be pigmenturia that is being observed, as there are relatively few red blood cells in the urinalysis.

The kidneys appear abnormal. They are somewhat plump and bright with pyelectasia. This could be seen with Leptospirosis, pyelonephritis, infiltrative neoplasia, etc. Additionally, there is glucose in the urine, which is unusual with a normal serum glucose. Recommend rechecking these values. If glucosuria persists, this is indicative of tubular disease. Urinalysis and culture should be performed in the addition to Leptospirosis testing (pending per history). If glucosuria persists, consider testing for Fanconi like syndrome at University of Pennsylvania. Also recommend urine protein/creatinine level to discern the level of proteinuria present.

The spleen and liver both appear slightly bright and swollen. Liver values are normal, so the significance of this is unclear. The CBC results are curious to me with such an elevated reticulocyte count despite a normal hematocrit and WBC count elevations. Consider pulling a fresh sample for CBC and chemistry that is fasted and free of hemolysis and lipemia (hopefully?), and have a CBC and path review done at an outside lab to try to ensure there are no atypical cells present, etc. You could consider a fine needle aspirate of the liver and spleen to look for infiltrative neoplasia, but lower urinary tract signs would be an atypical presentation for this problem.

There is a scant amount of free fluid in the abdomen, and the pancreas appears prominent. I think this is generalized inflammation with splenitis also suspected. This is an interesting case with some confusing lab work and not terribly specific ultrasonographic findings. I would confirm the abnormalities detected, and pursue those. If that is not helpful, you could consider sampling of liver and spleen, and possible testing for tick borne disease.

INTERPRETED BY

Kathleen Sennello DVM,
MS, Diplomate ACVIM
(Small Animal Internal
Medicine)

IMAGING PERFORMED BY

Loetitia Saint-Jacques, RVT

HOSPITAL NAME

Advanced PetCare of
Nevada

REFERRING VET

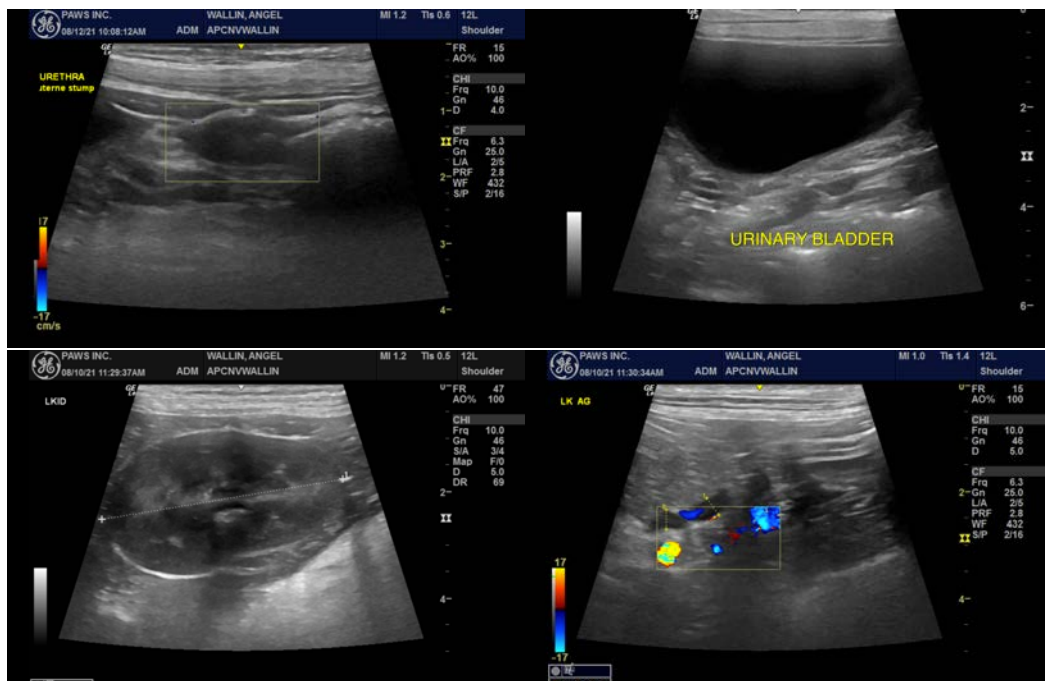
Dr. Sarah Behrens

INVOICE

24591

DATE

8/11/21





PATIENT

Angel Wallin

SPECIES

Canine

BREED

Maltese X

SEX

Spayed Female

AGE

5 Years

WEIGHT

16.2 Pounds

INTERPRETED BY

Kathleen Sennello DVM,
MS, Diplomate ACVIM
(Small Animal Internal
Medicine)

IMAGING PERFORMED BY

Loetitia Saint-Jacques, RVT

HOSPITAL NAME

Advanced PetCare of
Nevada

REFERRING VET

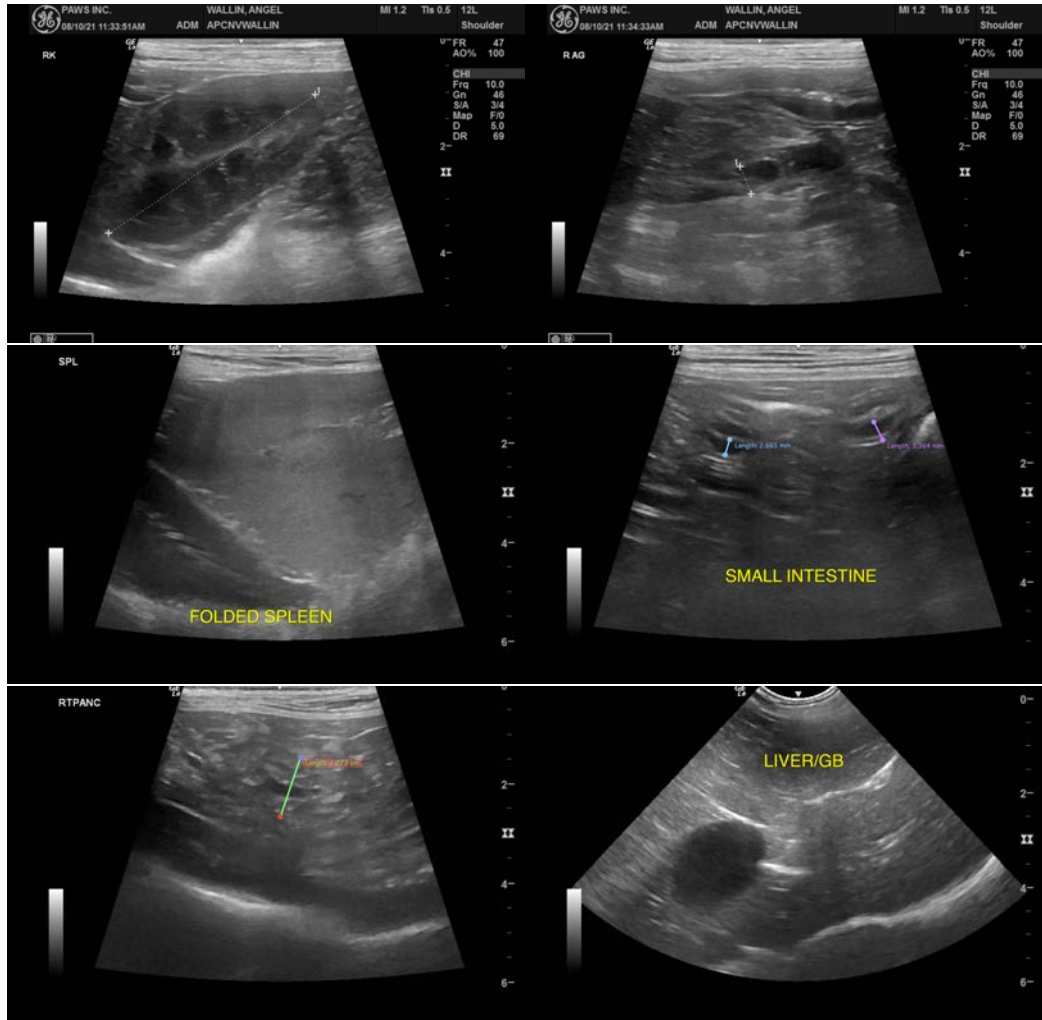
Dr. Sarah Behrens

INVOICE

24591

DATE

8/11/21



The information and recommendations provided are based on the images presented by the referring veterinarian. No evaluation can be communicated regarding pathology that was not visible in the image/video clips provided.

Thank you for this referral. If the clinical or image interpretation does not parallel your findings or if I can be of any further assistance please contact me.

Kathleen Sennello DVM,MS, Diplomate ACVIM (Small animal Internal Medicine)

kathleen.sennello@sonopath.com