

**DATE PRESENTING CLINICAL SIGNS**

8/9/23

Brought patient in for exam, HR 160, Gr II/VI systolic murmur, PMI apex, NSR, femoral pulses WNL, MM pink and moist, capillary refill <2 sec. Decided to do workup. Diffuse sig increase patchy interstitial pattern Cardiac silhouette appears rounded and mildly enlarged. No evidence of pleural effusion. All bony structures WNL. Radiographic changes consistent w/ pulmonary edema, Possible CHF

PATIENT

Henry Tierney

SPECIES

Feline

BREED

DSH

SEX

Neutered Male

AGE

4/4/12

WEIGHT

15.1 Pounds

INTERPRETED BY

Kathleen Sennello DVM,
MS, Diplomate ACVIM
(Small Animal Internal
Medicine)

HOSPITAL NAME

DocSide Vet Medical
Center

REFERRING VET

Dr. Tierney

INVOICE

44575

Current Medications: Lasix 12.5 mg 1/2 tablet q 12 hours

Lab Results: See attached.

Radiographs: See attached.

Date of Previous IntraPet Ultrasound: No previous.

Sedation: Not required to complete full diagnostic ultrasound.

Stat Report: Not requested.

Imaging Performed By: Andi Parkinson, BS, RDMS.

ULTRASONOGRAPHIC EXAMINATION OF THE ABDOMEN**Urinary System**

The urinary bladder is moderately distended with mild primarily suspended echogenic debris and some dependent shadowing/sandy debris present. The Bladder wall, trigone, ureteral papillae and visible urethra (to a depth of 2cm) appear normal with no evidence of wall thickening, mucosal irregularities, masses or calculi. Echogenic debris of this type can be associated with small crystals, sandy debris or small calculi. Correlate findings with abdominal radiographs, urinalysis and culture.

The left kidney is large (4.7 cm), slightly irregular, and hyperechoic with a prominent/thickened cortex. Corticomedullary distinction is mildly reduced. There are numerous variably sized cortical cysts visualized, one more prominent cyst measures 0.79 cm. There is no evidence of focal perinephric inflammation or effusion. There is no evidence of pyelectasia, nephroliths, infarcts or hydroureter. Renal vasculature is normal.

The right kidney is large (4.56 cm), slightly irregular, and hyperechoic with a prominent/thickened cortex. Corticomedullary distinction is mildly reduced. There are numerous variably sized cortical cysts visualized. There is no evidence of focal perinephric inflammation or effusion. There is no evidence of pyelectasia, nephroliths, infarcts or hydroureter. Renal vasculature is normal.

Adrenal Glands

The left adrenal gland is borderline "plump" measuring 0.62 cm at the caudal pole. It is observed in its normal position cranial to the left renal artery. It is normal in appearance (uniformly hypoechoic) and shape with no evidence of a mass effect.

The right adrenal gland is borderline "plump" measuring 0.59 cm at the caudal pole. It is observed in its normal position between the cranial aspect of the right kidney and the caudal vena cava. It is normal in appearance (uniformly hypoechoic) and shape with no evidence of a mass effect.

Spleen

The spleen is borderline large in size (1.2 cm), echotexture is homogenous, and the splenic capsule is smooth with no irregularities. The blood flow through the hilus and splenic parenchyma appears normal. No focal parenchymal abnormalities are visualized.

Liver

The liver is subjectively normal in size, and echogenicity with smooth peripheral margins. The parenchyma is homogenous echotexture. The visible portions of the vasculature and biliary tract appear normal. No focal nodules or cystic lesions are observed.

The gallbladder lumen is moderately distended. The wall of the gall bladder is not thickened and has a smooth mucosal surface. Luminal contents are mild and primarily anechoic. The cystic and common bile ducts are normal/not visible.

Gastrointestinal

The stomach contains minimal luminal contents. It measures at a normal thickness of <0.36cm with some variability due to the presence of rugal folds. The distinction of the gastric wall layers is adequate and there is no impression of reduced peristaltic activity. No masses or focal lesions were observed.

The visualized areas of duodenum, jejunum and ileum have a uniform diameter with minimal fluid distension. Wall thickness is normal to slightly increased. Bowel loops follow a typical curvilinear path with distinct wall layering, but some areas display a prominent muscularis layer which does not display the typical 1:3 muscularis:mucosa layer ratio. Duodenum wall measures 0.30 cm. Jejunum wall measures 0.25 cm. Visualized peristalsis appears appropriate. There were no focal lesions consistent with obstruction or a mass effect observed.

The ileocecal junction was visualized and exhibited normal intact wall layering and is subjectively of normal thickness. Sections of colon are visualized with formed fecal material and gas shadowing distally. There is no observed focal or generalized colon wall thickening or loss of layering.

Pancreas

The pancreas is prominent and mildly mottled compared to the surrounding isoechoic mesentery. There is no evidence of nodules or cystic lesions. Prominent pancreatic duct noted measuring 0.23 cm. There is no evidence of regional mesenteric inflammation or fluid.

Free Abdomen

Evaluation of the peritoneal cavity did not reveal any evidence of effusion. There are occasional visible but not overtly enlarged mesenteric lymph nodes measuring 0.30 and 0.33 cm. The omentum is generally of normal echogenicity.

Other

Ringdown artifact is visualized at the level of the diaphragm. This can be seen with pulmonary parenchymal disease.

PRIMARY FINDINGS

- Large, slightly irregular, hyperechoic kidneys with thickened renal cortices and numerous small cortical cysts – Findings are most consistent with chronic renal disease (interstitial nephritis) and benign renal cysts. Infiltrative disease cannot be ruled out but is less likely.
- Borderline large spleen – No parenchymal lesions are visualized, I suspect this is normal for this individual or secondary to congestion. A fine needle aspirate could be considered if round cell neoplasia is a significant concern.

- Prominent “ropey” small intestine with a mildly prominent muscularis layer – The small intestinal wall changes could be consistent with an underlying inflammatory process. These types of changes can sometimes be seen in normal older cats. Correlate with clinical signs.

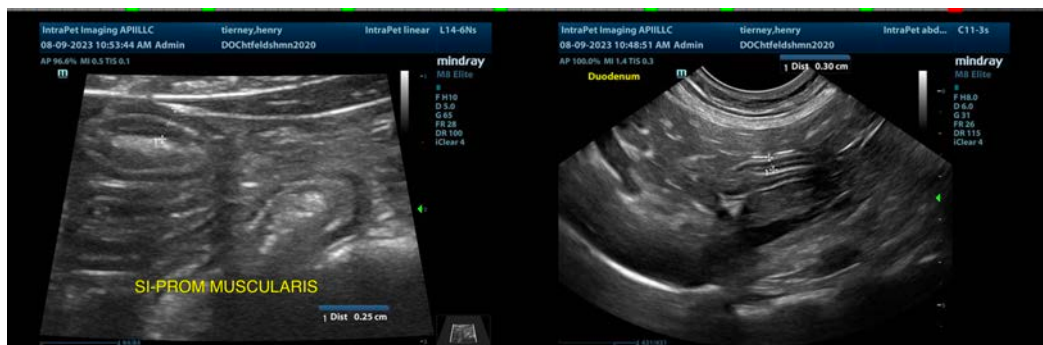SECONDARY FINDINGS

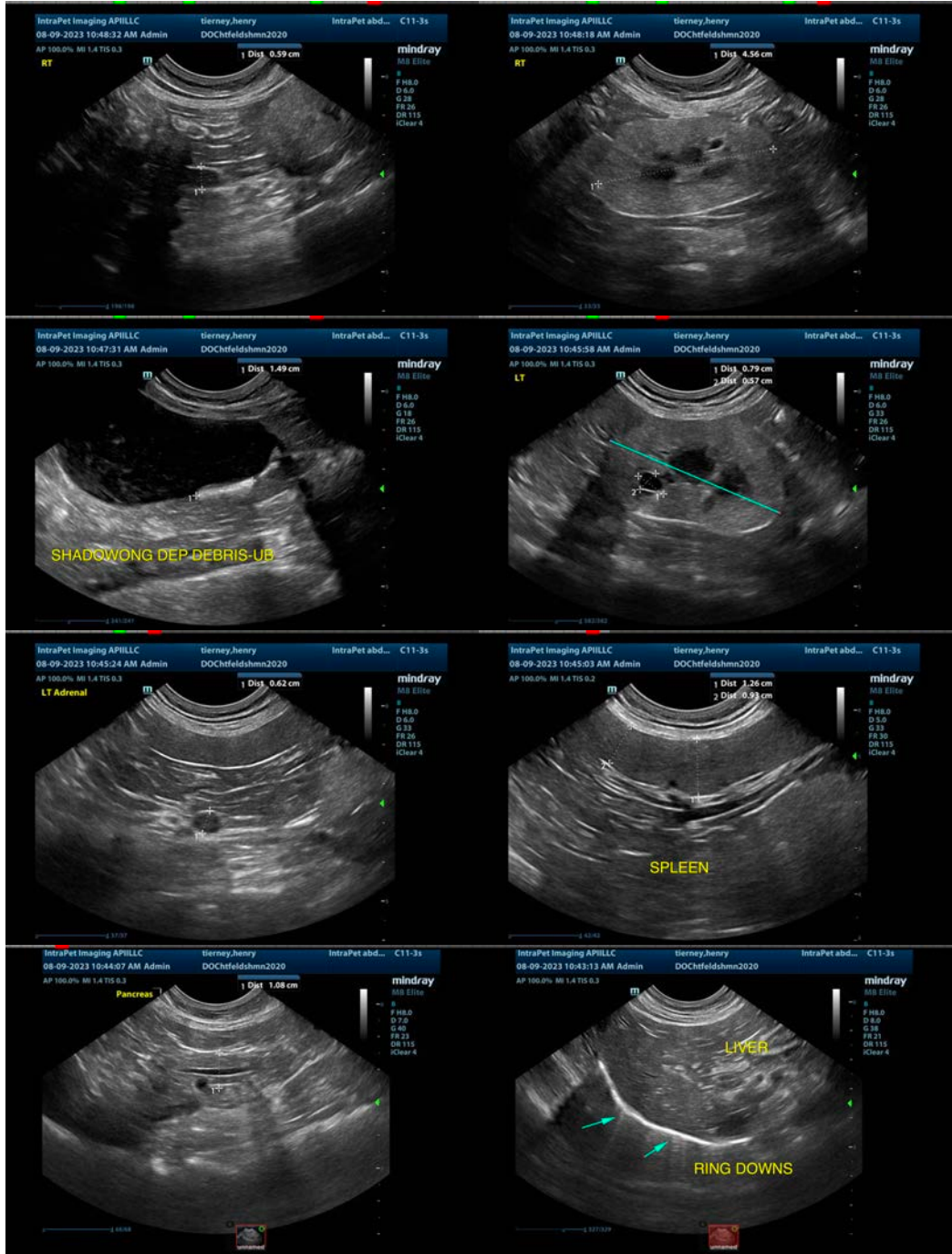
- Dependent sandy debris visualized in the urinary bladder – The echogenic dependent debris could be consistent with cells, crystals, small stones, sandy debris, etc. Recommend urinalysis and culture
- Borderline plump adrenal glands – This could be normal in a larger cat and this can also be seen in stressed geriatric patients with concurrent illness.
- Prominent, mottled pancreas with prominent pancreatic duct – The pancreatic changes are most consistent with age-related parenchymal remodeling, potentially secondary to a prior inflammatory episode, early fibrosis or chronic pancreatitis.

INTERPRETATION OF THE FINDINGS & FURTHER RECOMMENDATIONS

There are significant changes visualized associated with both kidneys. I suspect these are consistent with chronic progressive renal disease. Recommend a blood pressure, urinalysis, culture, and urine protein to creatinine ratio. Infiltrative disease is possible but seems less likely. Continued monitoring of the kidneys is warranted. If they become more irregular/enlarged, a fine needle aspirate would be more strongly considered.

No focal section of thickened bowel is identified. There is a generalized mild “ropey” appearance to the small intestine with a prominent muscularis layer and mild thickening. This could be within normal limits for this individual or could be associated with a primary enteropathy. If this patient is exhibiting symptoms consistent with chronic gastrointestinal disease, additional diagnostics and therapies could be considered, such as a novel protein diet, probiotics, a GI panel to Texas A&M, etc.





The information and recommendations provided are based on the images presented by the referring veterinarian/sonographer. No evaluation can be communicated regarding pathology that was not visible in the image/video clips provided.

Thank you for this referral. If the clinical or image interpretation does not parallel your findings or if I can be of any further assistance please contact me.

Kathleen Sennello DVM,MS, Diplomate ACVIM (Small animal Internal Medicine)
info@sonopath.com