

**PATIENT PRESENTING CLINICAL SIGNS**

Hammie  
Sammiesfriends

History \* cystic mass in area of prostate noted on u/s during routine cysto.

**SPECIES**

Canine

Abnormal PE/Chem/CBC/UA Results: Glob 3.7, SDMA 22.1, (BUN/Creat WNL BUN 22, Creat 1.6),  
USG 1.034, pH 7.5

**BREED**

Pitbull

**ULTRASONOGRAPHIC EXAMINATION OF THE ABDOMEN**

**Urinary System**

**SEX**

Neutered Male

The urinary bladder is moderately distended with anechoic urine. The Bladder wall, trigone, ureteral papillae, and visible urethra (to a depth of 2cm) appear normal with no evidence of wall thickening, mucosal irregularities, masses, or cystic calculi.

**AGE**

11y

In the region of the prostate there are numerous anechoic variably sized cystic structures with minimal solid prostatic tissue visualized. There appear to be cystic structures arising laterally in the region of the prostate two such structures measure at 2.18 cm x 4.58 cm and 5 cm x 2.99 cm. Additionally, there are smaller more loculated structures, these structures are most closely resemble prostatic or paraprostatic cysts.

**WEIGHT**

23.6kg

The left kidney has a normal shape and size (7.73 cm). Overall echogenicity is normal with adequate corticomedullary distinction and a typical 1:3 cortex:medulla ratio. There is no evidence of focal perinephric inflammation or effusion. There is no evidence of pyelectasia, nephroliths, infarcts or hydroureter. Renal vasculature is normal.

**INTERPRETED BY**

Kathleen Sennello DVM,  
MS, Diplomate ACVIM  
(Small Animal Internal  
Medicine)

The right kidney has a normal shape and size (8.11 cm). Overall echogenicity is normal with adequate corticomedullary distinction and a typical 1:3 cortex: medulla ratio. There is no evidence of focal perinephric inflammation or effusion. There is no evidence of pyelectasia, nephroliths, infarcts or hydroureter. Renal vasculature is normal.

**IMAGING PERFORMED BY**

Loetitia Saint-Jacques,  
LVT

**Adrenal Glands**

**HOSPITAL NAME**

Brighton Greens  
Veterinary Hospital

The left adrenal gland is normal in size measuring 0.53 cm at the caudal pole. It is observed in its normal position cranial to the left renal artery. It is normal in appearance (uniformly hypoechoic) and shape with no evidence of a mass effect.

The right adrenal gland is normal in size measuring 0.82 cm at the caudal pole. It is observed in its normal position between the cranial aspect of the right kidney and the caudal vena cava. It is normal in appearance (uniformly hypoechoic) and shape with no evidence of a mass effect.

**REFERRING VET**

Dr. Robin Janeway

**Spleen**

The spleen is subjectively normal in size, echotexture is homogenous, and the splenic capsule is smooth with no irregularities. The blood flow through the hilus and splenic parenchyma appears normal. No focal parenchymal abnormalities are visualized.

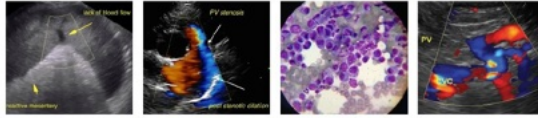
**INVOICE**

10400

**DATE**

8/10/2023

**Liver**



**PATIENT**

Hammie  
Sammiesfriends

The liver is subjectively normal in size, and echogenicity with smooth peripheral margins. The parenchyma is heterogenous in echotexture with subtle, indistinct focal mottling. The visible portions of the vasculature and biliary tract appear normal. No focal nodules or cystic lesions are observed.

**SPECIES**

Canine

The gallbladder lumen is moderately distended. The wall of the gall bladder is not thickened and has a smooth mucosal surface. Luminal contents are mild and primarily anechoic. The cystic and common bile ducts are normal/not visible.

**BREED**

**Gastrointestinal**

Pitbull

The stomach contains minimal luminal contents. It measures at a normal thickness of <0.7cm with some variability due to the presence of rugal folds. The distinction of the gastric wall layers is adequate and there is no impression of reduced peristaltic activity. No masses or focal lesions were observed.

**SEX**

Neutered Male

The visualized areas of duodenum, jejunum and ileum have a relatively uniform diameter with minimal fluid distension. Wall thickness is normal. Bowel loops follow a curvilinear path with distinct wall layering maintaining the typical 1:3 muscularis: mucosa layer ratio. The jejunum measured as normal (0.45 cm.) Visualized peristalsis appears appropriate. There were no focal lesions consistent with obstruction or a mass effect observed.

**AGE**

11y

**WEIGHT**

23.6kg

The ileocecal junction was visualized and exhibited normal intact wall layering and is subjectively of normal thickness. Sections of colon are visualized with formed fecal material and gas shadowing distally. There is no observed focal or generalized colon wall thickening or loss of layering.

**INTERPRETED BY**

Kathleen Sennello DVM,  
MS, Diplomate ACVIM  
(Small Animal Internal  
Medicine)

**Pancreas**

The pancreas is normal and isoechoic to surrounding mesentery. There is no evidence of nodules or cystic lesions. There is no evidence of regional mesenteric inflammation or fluid.

**IMAGING PERFORMED BY**

Loetitia Saint-Jacques,  
LVT

**Free Abdomen**

Evaluation of the peritoneal cavity did not reveal any evidence of effusion. Sub lumbar lymph nodes are slightly prominent the right sub lumbar lymph node measures at 0.97 cm and the left at 1.02 cm. The Medial iliac nodes appear normal and there was no evidence of a caudal aortic thrombus at the bifurcation. The omentum is of normal uniform echogenicity.

**HOSPITAL NAME**

Brighton Greens  
Veterinary Hospital

**PRIMARY FINDINGS**

**REFERRING VET**

Dr. Robin Janeway

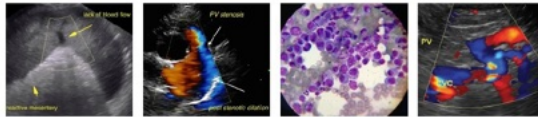
- Numerous anechoic cystic structures visualized in the region of prostate. Correlate these findings with the neutering history. If the patient was neutered late in life this could be unresolved or partially resolved paraprostatic cysts. If the patient was neutered prior to puberty this could represent a more pathologic process associated with neoplasia etc.
- Heterogenous liver. The diffuse hepatic changes are non-specific and could be consistent with vacuolar hepatopathy, nodular hyperplasia, inflammatory/immune-mediated disease, fibrosis, extramedullary hematopoiesis, toxic hepatopathy (e.g., copper), infiltrative neoplasia (less likely) or other hepatopathy. Correlate with current lab work if liver enzyme values are normal this could represent age related change.
- Prominent sub lumbar lymph nodes. The prominent abdominal lymph nodes are most consistent with reactive lymphadenitis or lymphoid hyperplasia. Neoplastic infiltration is considered less likely.

**INVOICE**

10400

**DATE**

8/10/2023



**PATIENT**

Hammie  
Sammiesfriends

**SPECIES**

Canine

**BREED**

Pitbull

**SEX**

Neutered Male

**AGE**

11y

**WEIGHT**

23.6kg

**INTERPRETED BY**

Kathleen Sennello DVM,  
MS, Diplomate ACVIM  
(Small Animal Internal  
Medicine)

**IMAGING PERFORMED BY**

Loetitia Saint-Jacques,  
LVT

**HOSPITAL NAME**

Brighton Greens  
Veterinary Hospital

**REFERRING VET**

Dr. Robin Janeway

**INVOICE**

10400

**DATE**

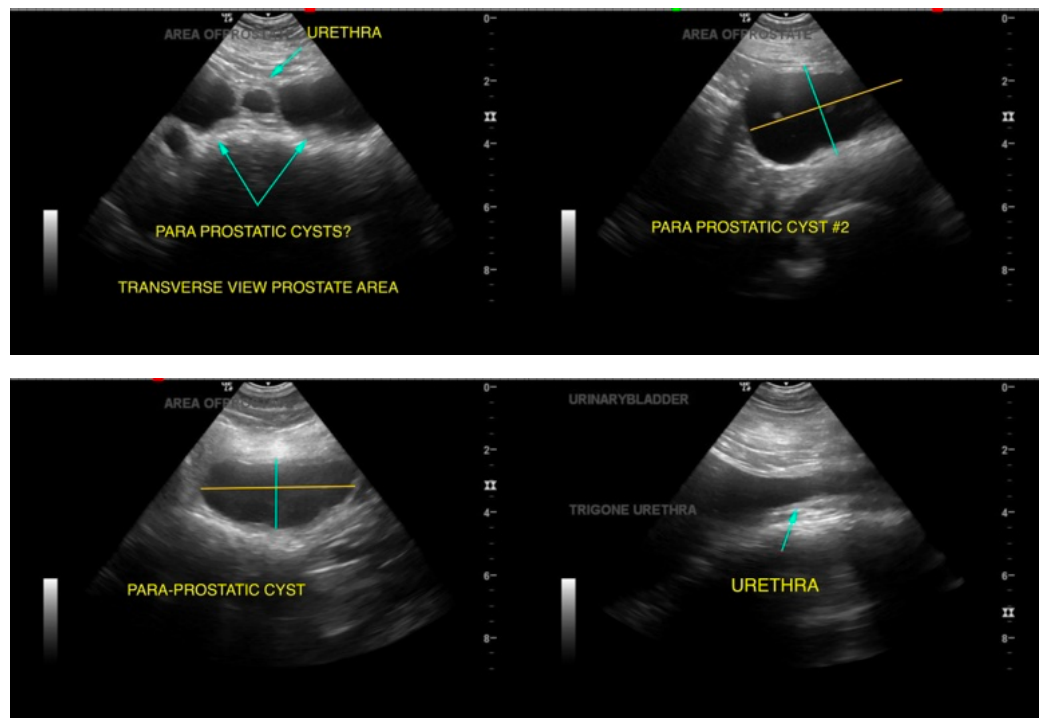
8/10/2023

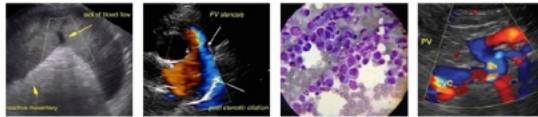
**INTERPRETATION OF THE FINDINGS & FURTHER RECOMMENDATIONS**

The age of neutering is a very important piece of information. If this patient was neutered later in life after significant prostatic disease this could represent prostatic or paraprostatic abscesses that have only partially resolved (which can be a common complication). If this patient was neutered early in life, then there would be more concern for this being a pathologic process associated with prostatic neoplasia etc. Consider drainage of several of these lesions using sterile technique for fluid analysis and cytology. Abscessation can not be ruled out but seems less likely. Additionally, consider a urine analysis and culture.

If this patient was neutered early in life, I would typically recommended a fine needle aspirate of the prostate but there is very little solid prostatic tissue visualized. I would likely still recommend drainage and evaluation of the fluid within the cystic structures, and you could consider traumatic catheterization in the region or even surgical biopsies.

The prominent lymph nodes in the sub lumbar lymph in the sub lumbar area could represent reactive lymph nodes, changes are less likely consistent with metastatic disease although this cannot be definitively ruled out.





**PATIENT**

Hammie  
Sammiesfriends

**SPECIES**

Canine

**BREED**

Pitbull

**SEX**

Neutered Male

**AGE**

11y

**WEIGHT**

23.6kg

**INTERPRETED BY**

Kathleen Sennello DVM,  
MS, Diplomate ACVIM  
(Small Animal Internal  
Medicine)

**IMAGING  
PERFORMED BY**

Loetitia Saint-Jacques,  
LVT

**HOSPITAL NAME**

Brighton Greens  
Veterinary Hospital

**REFERRING VET**

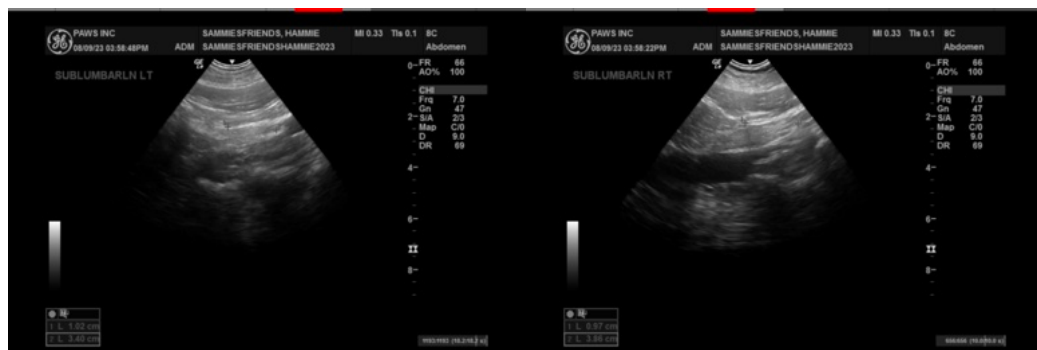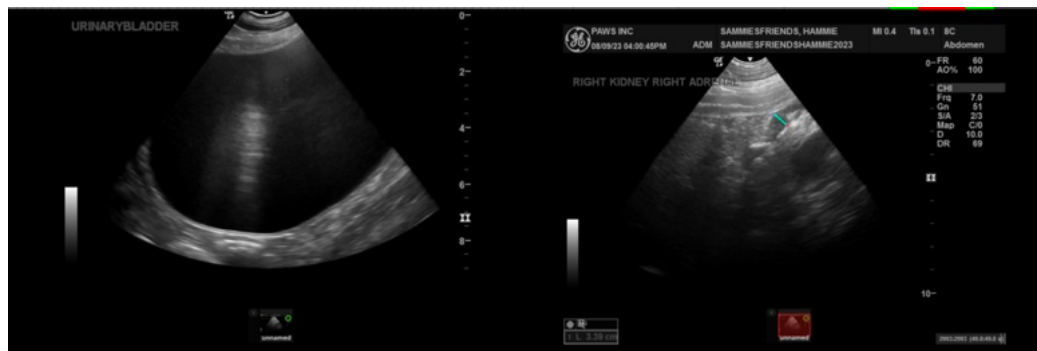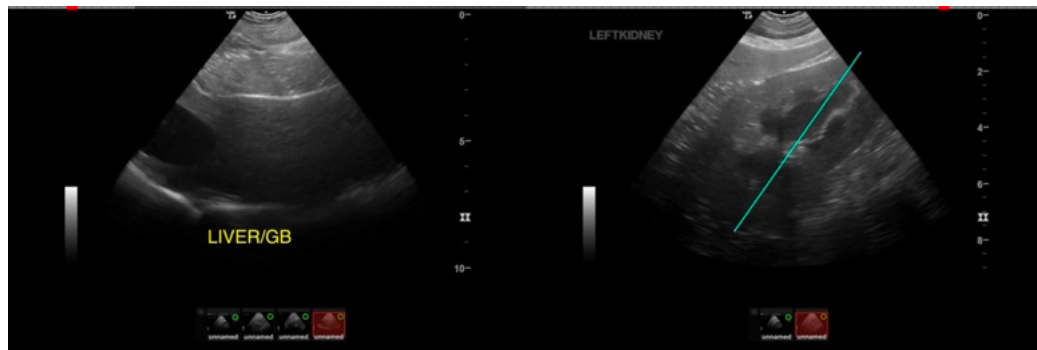
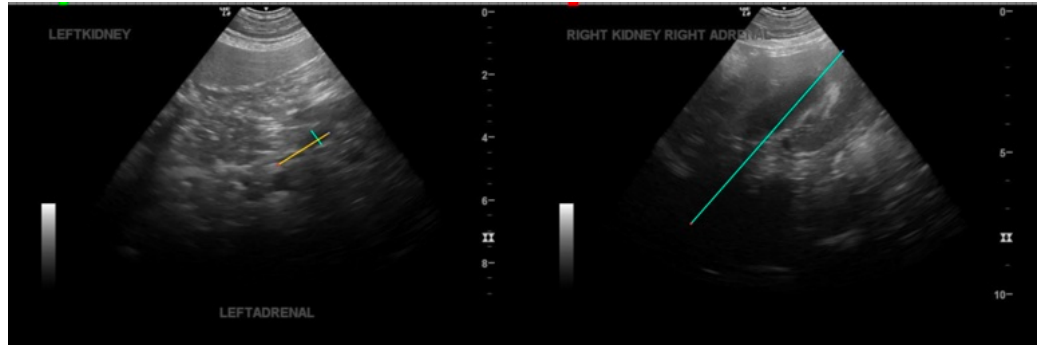
Dr. Robin Janeway

**INVOICE**

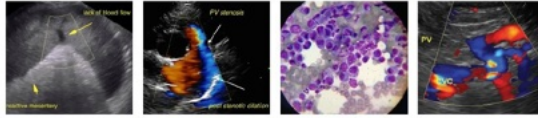
10400

**DATE**

8/10/2023



The information and recommendations provided are based on the images presented by the referring veterinarian/sonographer. No evaluation can be communicated regarding pathology that was not visible in the image/video clips provided.



**PATIENT**

Hammie  
Sammiesfriends

**SPECIES**

Canine

**BREED**

Pitbull

**SEX**

Neutered Male

**AGE**

11y

**WEIGHT**

23.6kg

**INTERPRETED BY**

Kathleen Sennello DVM,  
MS, Diplomate ACVIM  
(Small Animal Internal  
Medicine)

**IMAGING  
PERFORMED BY**

Loetitia Saint-Jacques,  
LVT

**HOSPITAL NAME**

Brighton Greens  
Veterinary Hospital

**REFERRING VET**

Dr. Robin Janeway

**INVOICE**

10400

**DATE**

8/10/2023

Thank you for this referral. If the clinical or image interpretation does not parallel your findings or if I can be of any further assistance, please contact me.

Kathleen Sennello DVM, MS, Diplomate ACVIM (Small animal Internal Medicine)

info@sonopath.com