

**DATE PRESENTING CLINICAL SIGNS**

8/10/23 Weight loss, inconsistent appetite.

PATIENT Current Medications: Sucralfate 250mg BID.

Lab Results: WNL.

Gypsy Greer Date of Previous IntraPet Ultrasound: No previous.

Sedation: Not required to complete full diagnostic ultrasound.

Stat Report: Not requested.

SPECIES Imaging Performed By: Rachel Brillhart, RDMS.

Feline

ULTRASONOGRAPHIC EXAMINATION OF THE ABDOMEN**BREED****Urinary System**

DSH

The urinary bladder is moderately distended with anechoic urine. The Bladder wall, trigone, ureteral papillae and visible urethra (to a depth of 2cm) appear normal with no evidence of wall thickening, mucosal irregularities, or masses. There is a small amount of hyperechoic shadowing debris visualized in the dependent portion of the urinary bladder, most consistent with a small stone or pile of small mineralized debris. This area measures 0.34 cm.

SEX

Spayed Female

AGE

8/20/07

The left kidney has a normal shape and size (3.61 cm) with small non-obstructive mineralizations. Overall echogenicity is slightly hyperechoic with poor corticomedullary distinction and a typical 1:3 cortex:medulla ratio. There is no evidence of focal perinephric inflammation or effusion. There is no evidence of pyelectasia, infarcts or hydroureter. Renal vasculature is normal.

WEIGHT

8.8 Pounds

The right kidney has a normal shape and size (3.6 cm) with decreased corticomedullary distinction and non-obstructive mineralizations. Overall echogenicity is normal with adequate corticomedullary distinction and a typical 1:3 cortex:medulla ratio. There is no evidence of focal perinephric inflammation or effusion. There is no evidence of pyelectasia, infarcts or hydroureter. Renal vasculature is normal.

INTERPRETED BY

Kathleen Sennello DVM,
MS, Diplomate ACVIM
(Small Animal Internal
Medicine)

Adrenal Glands

The left adrenal gland is normal in size measuring 0.49 cm at the caudal pole. It is observed in its normal position cranial to the left renal artery. It is normal in appearance (uniformly hypoechoic) and shape with no evidence of a mass effect.

HOSPITAL NAME

Bay Country VH

The right adrenal gland is normal in size measuring 0.41 cm at the caudal pole. It is observed in its normal position between the cranial aspect of the right kidney and the caudal vena cava. It is normal in appearance (uniformly hypoechoic) and shape with no evidence of a mass effect.

REFERRING VET

Dr. Smith

Spleen

The spleen is subjectively normal in size (0.73 cm), echotexture is homogenous, and the splenic capsule is smooth with no irregularities. The blood flow through the hilus and splenic parenchyma appears normal. No focal parenchymal abnormalities are visualized.

INVOICE

44571

Liver

The liver is subjectively normal in size, and echogenicity with smooth peripheral margins. The parenchyma is homogenous echotexture. The visible portions of the vasculature and biliary tract appear normal. No focal nodules or cystic lesions are observed.

The gall bladder lumen is moderately distended. The wall of the gall bladder is not thickened and has a smooth mucosal surface. There is a mild amount of non-organized echogenic debris. The cystic and common bile ducts are normal/not visible.

Gastrointestinal

The stomach contains minimal ingesta or fluid. The gastric wall appears severely thickened with complete loss of layering. In this area the gastric wall measures approximately 1.3 cm in thickness as compared to a more normal area of gastric wall with intact wall layering, which measures 0.42 cm in thickness. There is no evidence of an obstructive process at this time.

The visualized areas of duodenum, jejunum and ileum have a relatively uniform diameter with minimal fluid distension. Wall thickness is normal. Bowel loops follow a curvilinear path with distinct wall layering maintaining the typical 1:3 muscularis:mucosa layer ratio. Jejunum wall measures 0.24 cm. Visualized peristalsis appears appropriate. There were no focal lesions consistent with obstruction or a mass effect observed.

Sections of colon are visualized with formed fecal material and gas shadowing distally. There is no observed focal or generalized colon wall thickening or loss of layering.

Pancreas

The area of the pancreas is normal and isoechoic to surrounding mesentery. There is no evidence of nodules or cystic lesions. There is no evidence of regional mesenteric inflammation or fluid.

Free Abdomen

Evaluation of the peritoneal cavity did not reveal any evidence of effusion. There is a prominent gastric lymph node in the cranial abdomen measuring 0.71 cm. The omentum is hyperechoic around the hypoechoic abnormal gastric wall.

ULTRASONOGRAPHIC FINDINGS

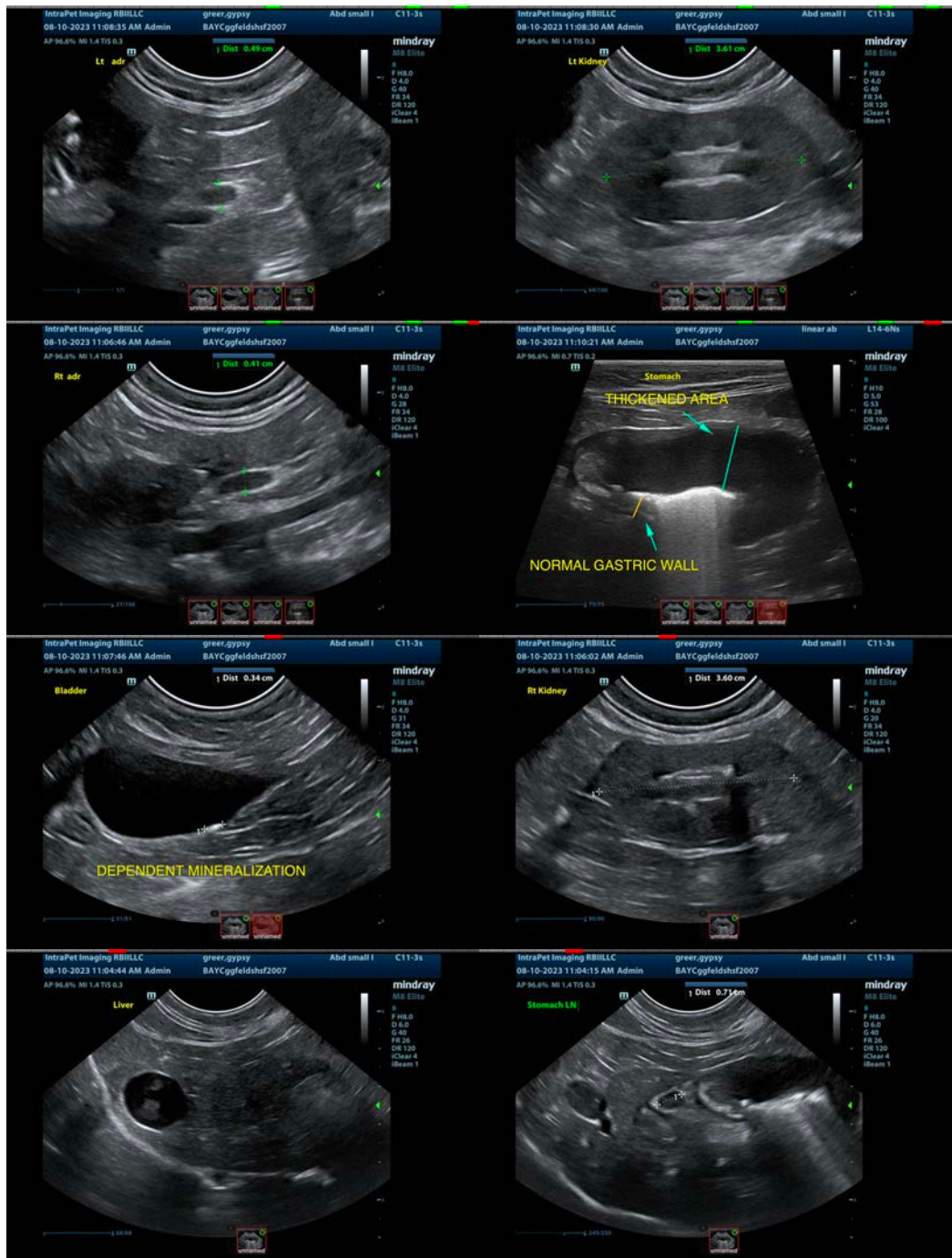
- Small area of shadowing mineralization in the dependent portion of the urinary bladder – Findings could be consistent with a small stone, sandy debris, etc. Correlate with urinalysis and abdominal radiographs.
- Decreased corticomedullary distinction in both kidneys with small mineralizations – The bilateral renal findings are consistent with age-related change.
- Focal extensive severe gastric wall thickening with complete loss of layering – Findings are highly concerning for infiltrative disease (round cell neoplasia, carcinoma, other), although severe gastritis and other differentials are possible.
- Prominent cranial abdominal lymph nodes – The prominent abdominal lymph nodes are most consistent with reactive lymphadenitis or lymphoid hyperplasia. Neoplastic infiltration is considered less likely.

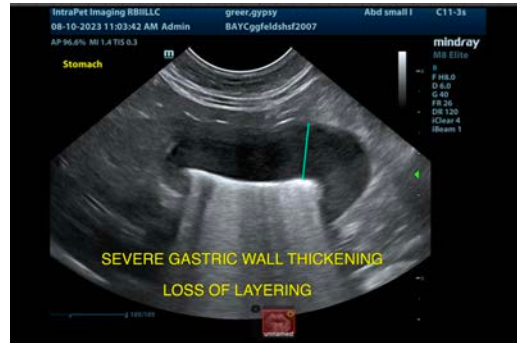INTERPRETATION OF THE FINDINGS & FURTHER RECOMMENDATIONS

A large portion of the gastric wall appears severely thickened with complete loss of wall layering. This is most consistent with an extensive gastric mass lesion. Primary differential would be round cell neoplasia, carcinoma, other. Recommend a fine needle aspirate of the gastric wall. If a cytologic diagnosis cannot be

obtained, surgical biopsies may be necessary.

Recommend three view thoracic radiographs to evaluate for possible concurrent thoracic disease/involvement.





The information and recommendations provided are based on the images presented by the referring veterinarian/sonographer. No evaluation can be communicated regarding pathology that was not visible in the image/video clips provided.

Thank you for this referral. If the clinical or image interpretation does not parallel your findings or if I can be of any further assistance please contact me.

Kathleen Sennello DVM,MS, Diplomate ACVIM (Small animal Internal Medicine)
info@sonopath.com