

PATIENT PRESENTING CLINICAL SIGNS

Avi Parker Pursuing GA for dental, overweight, loss of appetite and dental disease. Denamarin caused GI upset according to O. Elevated ALT.

SPECIES

Canine Abnormal PE/Chem/CBC/UA Results: AST 71, ALT 371 (prev 244), CHO 355, TG 378, USG 1.054, pro trace

BREED

Corgi

ULTRASONOGRAPHIC EXAMINATION OF THE ABDOMEN

SEX

Neutered Male

Urinary System

The urinary bladder is moderately distended with anechoic urine. The Bladder wall, trigone, ureteral papillae, and visible urethra (to a depth of 2cm) appear normal with no evidence of wall thickening, mucosal irregularities, masses, or cystic calculi.

AGE

6y

The prostate is normal in size (0.58 cm) and shape for this neutered male dog. The parenchyma is homogenous, and the external margins are smooth. The prostatic urethra appears normal with no evidence of irregularity, invasion, mass effect or calculi.

WEIGHT

17.5kg

The left kidney has a normal shape and size (5.47 cm). Overall echogenicity is normal with adequate corticomedullary distinction and a typical 1:3 cortex:medulla ratio. There is no evidence of focal perinephric inflammation or effusion. There is no evidence of pyelectasia, nephroliths, infarcts or hydroureter. Renal vasculature is normal.

INTERPRETED BY

Kathleen Sennello DVM,
MS, Diplomate ACVIM
(Small Animal Internal
Medicine)

The right kidney has a normal shape and size (5.74 cm). Overall echogenicity is normal with adequate corticomedullary distinction and a typical 1:3 cortex: medulla ratio. There is no evidence of focal perinephric inflammation or effusion. There is no evidence of pyelectasia, nephroliths, infarcts or hydroureter. Renal vasculature is normal.

IMAGING PERFORMED BY

Loetitia Saint-Jacques,
LVT

Adrenal Glands

The left adrenal gland is normal in size measuring 0.6 cm at the caudal pole. It is observed in its normal position cranial to the left renal artery. It is normal in appearance (uniformly hypoechoic) and shape with no evidence of a mass effect.

HOSPITAL NAME

Brighton Greens
Veterinary Hospital

The right adrenal gland is normal in size measuring 0.6 cm at the caudal pole. It is observed in its normal position between the cranial aspect of the right kidney and the caudal vena cava. It is normal in appearance (uniformly hypoechoic) and shape with no evidence of a mass effect.

REFERRING VET

Dr. Robin Janeway

Spleen

The spleen is subjectively normal in size, echotexture is homogenous, and the splenic capsule is smooth with no irregularities. The blood flow through the hilus and splenic parenchyma appears normal. No focal parenchymal abnormalities are visualized.

INVOICE

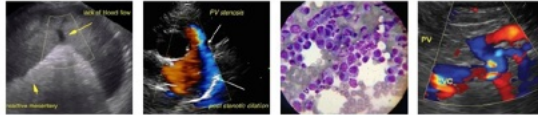
10403

Liver

DATE

8/10/2023

The liver is subjectively normal in size, and echogenicity with smooth peripheral margins. The parenchyma is homogenous echotexture. The visible portions of the vasculature and biliary tract appear normal. There are three nodules visualized on today's exam. There is a hypoechoic nodule/mass



PATIENT

Avi Parker

effect visualized adjacent to the gallbladder measuring 2.53 cm x 1.38 cm. Additionally, there is a smaller hypoechoic nodule measuring 1.84 cm and a hyperechoic nodule measuring 1.17 cm x 1.51 cm both in the cranial aspect of the liver.

SPECIES

Canine

The gallbladder lumen is moderately distended. The wall of the gall bladder is not thickened and has a smooth mucosal surface. Luminal contents are mild and primarily anechoic. The cystic and common bile ducts are normal/not visible.

BREED

Gastrointestinal

Corgi

The stomach contains minimal luminal contents. It measures at a normal thickness of <0.7cm with some variability due to the presence of rugal folds. The distinction of the gastric wall layers is adequate and there is no impression of reduced peristaltic activity. No masses or focal lesions were observed.

SEX

Neutered Male

The visualized areas of duodenum, jejunum and ileum have a relatively uniform diameter with minimal fluid distension. Wall thickness is normal. Bowel loops follow a curvilinear path with distinct wall layering maintaining the typical 1:3 muscularis: mucosa layer ratio. The jejunum measured as normal (0.38 cm.) Visualized peristalsis appears appropriate. There were no focal lesions consistent with obstruction or a mass effect observed.

AGE

6y

WEIGHT

17.5kg

Sections of colon are visualized with formed fecal material and gas shadowing distally. There is no observed focal or generalized colon wall thickening or loss of layering.

INTERPRETED BY

Kathleen Sennello DVM,
MS, Diplomate ACVIM
(Small Animal Internal
Medicine)

Pancreas

The pancreas is normal and isoechoic to surrounding mesentery. There is no evidence of nodules or cystic lesions. There is no evidence of regional mesenteric inflammation or fluid.

Free Abdomen

Evaluation of the peritoneal cavity did not reveal any evidence of effusion, or subjective lymphadenomegaly. The Medial iliac nodes appear normal and there was no evidence of a caudal aortic thrombus at the bifurcation. The omentum is of normal uniform echogenicity.

IMAGING PERFORMED BY

Loetitia Saint-Jacques,
LVT

PRIMARY FINDINGS

HOSPITAL NAME

Brighton Greens
Veterinary Hospital

- Three liver nodules visualized. The appearance of the hyperechoic trends towards a more benign process. The hypoechoic nodule in the cranial aspect of the liver has minimal criteria for malignancy but could represent a benign or neoplastic process. The larger hypoechoic nodule adjacent to the gallbladder is slightly more concerning due to its size.

REFERRING VET

Dr. Robin Janeway

INTERPRETATION OF THE FINDINGS & FURTHER RECOMMENDATIONS

INVOICE

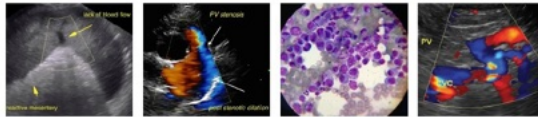
10403

There are three nodules visualized associated with the liver. The two smaller nodules are relatively benign in appearance although an underlying neoplastic process cannot be ruled out. The larger hypoechoic nodule adjacent to the gallbladder is slightly more concerning as it may be deviating the gallbladder slightly and it is a larger nodule. Unfortunately, none of these lesions are in areas which could be easily sampled, and it is unknown if these lesions are the cause for the ALT elevation or if there is diffuse hepatopathy as well.

DATE

8/10/2023

Consider the following steps for further evaluation of a general hepatopathy/ALT evaluation and consider either a contrast CT scan to further evaluate these nodules or serial ultrasound imaging



PATIENT

monitoring particularly the nodule/mass effect near the gallbladder for progression.

Avi Parker

SPECIES

Canine

BREED

Corgi

SEX

Neutered Male

AGE

6y

WEIGHT

17.5kg

INTERPRETED BY

Kathleen Sennello DVM,
MS, Diplomate ACVIM
(Small Animal Internal
Medicine)

IMAGING PERFORMED BY

Loetitia Saint-Jacques,
LVT

HOSPITAL NAME

Brighton Greens
Veterinary Hospital

REFERRING VET

Dr. Robin Janeway

INVOICE

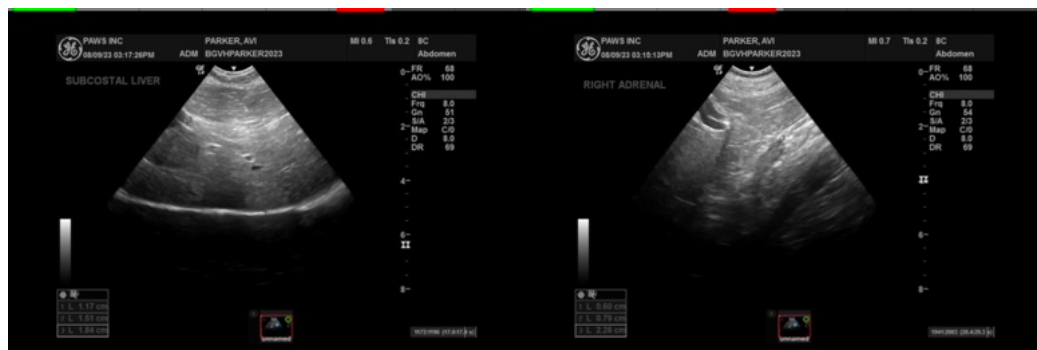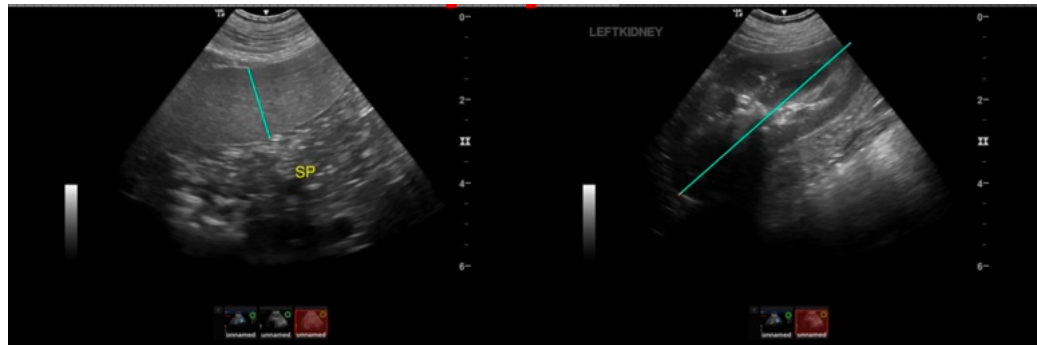
10403

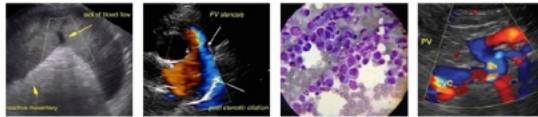
DATE

8/10/2023

- Consider close evaluation of history for possible toxic changes examine medications, diet, dietary indiscretion etc...
- Consider PCR on urine/serum for leptospirosis (if not on antibiotics)/serology if recent antibiotic history.
- If not already done, consider pre and post prandial bile acids to evaluate liver function.
- Consider Fine needle aspirate if round cell neoplasia is on your differentia list (25 g needle, normal coags)
- If no response to supportive care (denamarin, fluids, antibiotics, +/- ursodiol etc...) Consider liver biopsy with samples obtained for histopathology, culture, and copper levels.

Recommend three view thoracic radiographs to evaluate for possible concurrent thoracic disease/involvement.





PATIENT

Avi Parker

SPECIES

Canine

BREED

Corgi

SEX

Neutered Male

AGE

6y

WEIGHT

17.5kg

INTERPRETED BY

Kathleen Sennello DVM,
MS, Diplomate ACVIM
(Small Animal Internal
Medicine)

**IMAGING
PERFORMED BY**

Loetitia Saint-Jacques,
LVT

HOSPITAL NAME

Brighton Greens
Veterinary Hospital

REFERRING VET

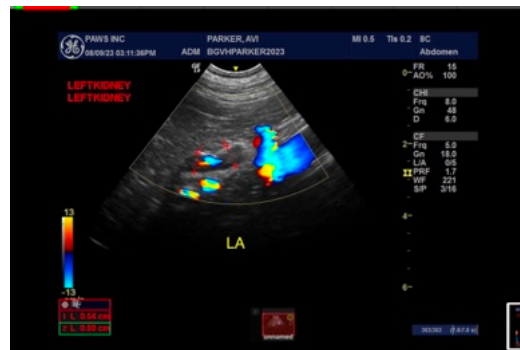
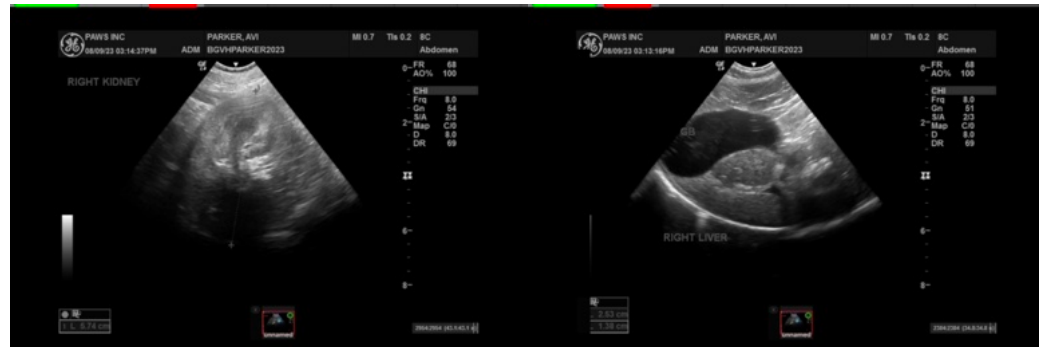
Dr. Robin Janeway

INVOICE

10403

DATE

8/10/2023



The information and recommendations provided are based on the images presented by the referring veterinarian/sonographer. No evaluation can be communicated regarding pathology that was not visible in the image/video clips provided.

Thank you for this referral. If the clinical or image interpretation does not parallel your findings or if I can be of any further assistance, please contact me.

Kathleen Sennello DVM, MS, Diplomate ACVIM (Small animal Internal Medicine)

info@sonopath.com