



PATIENT

TaterTot Tockes

PRESENTING CLINICAL SIGNS

SPECIES

Feline

BREED

DSH

Heart, Lungs and pulse: There is a right-sided machine sounding murmur grade 4/6 and is audible on left side but less prominent. Lungs auscult and femoral pulses within normal limits.
Abnormal PE/Chem/CBC/UA Results: Blood Pressure, Doppler Systolic Avg: 110 (110,112,110) Left Front #2 cuff - P in right lateral= Chemistry screen: Slight increase 11.4 and phosphorus 8.7 CBC: Slight decrease white blood cells and neutrophils Urinalysis: Increased specific gravity and pH likely causing falsely increase protein FeLV antibody tests: Negative FIV antigen test: Negative

ULTRASONOGRAPHIC EXAMINATION OF THE ABDOMEN

SEX

Male

AGE

19 Weeks

WEIGHT

4.87 Pounds

Urinary System

The urinary bladder is moderately distended with anechoic urine. The Bladder wall, trigone, ureteral papillae and visible urethra (to a depth of 2cm) appear normal with no evidence of wall thickening, mucosal irregularities, masses or cystic calculi.

The left kidney has a normal shape and size (3.26 cm). Overall echogenicity is normal with adequate corticomedullary distinction and a typical 1:3 cortex:medulla ratio. There is no evidence of perinephric inflammation or effusion. There is no evidence of pyelectasia, nephroliths, infarcts or hydroureter. Renal vasculature is normal.

The right kidney has a normal shape and size (3.46 cm). Overall echogenicity is normal with adequate corticomedullary distinction and a typical 1:3 cortex:medulla ratio. There is no evidence of perinephric inflammation or effusion. There is no evidence of pyelectasia, nephroliths, infarcts or hydroureter. Renal vasculature is normal.

INTERPRETED BY

Kathleen Sennello DVM,
MS, Diplomate ACVIM
(Small Animal Internal
Medicine)

Adrenal Glands

The left adrenal gland is normal in size measuring 0.37 cm at the caudal pole. It is observed in its normal position cranial to the left renal artery. It is normal in appearance (uniformly hypoechoic) and shape with no evidence of a mass effect.

The right adrenal gland is normal in size measuring 0.38 cm at the caudal pole. It is observed in its normal position between the cranial aspect of the right kidney and the caudal vena cava. It is normal in appearance (uniformly hypoechoic) and shape with no evidence of a mass effect.

IMAGING BY

Loetitia Saint-Jacques,
LVT

Spleen

The spleen is subjectively normal in size (0.85 cm in width at the level of the hilus), echotexture is homogenous, and the splenic capsule is smooth with no irregularities. The blood flow through the hilus and splenic parenchyma appears normal. No focal parenchymal abnormalities are visualized.

HOSPITAL NAME

South Reno VH

Liver

The liver is subjectively normal in size, and echogenicity with smooth peripheral margins. The parenchyma is homogenous echotexture. The visible portions of the vasculature and biliary tract appear normal. No focal nodules or cystic lesions are observed.

REFERRING VET

Dr. Schmitt

INVOICE

40293

DATE

8/10/22



PATIENT

TaterTot Tockes

SPECIES

Feline

BREED

DSH

SEX

Male

AGE

19 Weeks

WEIGHT

4.87 Pounds

INTERPRETED BY

Kathleen Sennello DVM,
MS, Diplomate ACVIM
(Small Animal Internal
Medicine)

IMAGING BY

Loetitia Saint-Jacques,
LVT

HOSPITAL NAME

South Reno VH

REFERRING VET

Dr. Schmitt

INVOICE

40293

DATE

8/10/22

Gastrointestinal

The stomach contains minimal luminal contents. It measures at a normal thickness of <0.36cm with some variability due to the presence of rugal folds. The distinction of the gastric wall layers is adequate and there is no impression of reduced peristaltic activity. No masses or focal lesions were observed.

The visualized areas of duodenum, jejunum and ileum have a relatively uniform diameter with minimal fluid distension. Wall thickness is normal. Bowel loops follow a curvilinear path with distinct wall layering maintaining the typical 1:3 muscularis:mucosa layer ratio. The duodenum measured as normal (between 0.13-0.38cm in wall thickness) and the jejunum measured as normal (between 0.15-0.36cm.) Visualized peristalsis appears appropriate. There were no focal lesions consistent with obstruction or a mass effect observed.

The ileocecal junction was visualized and exhibited normal intact wall layering and is subjectively of normal thickness. Sections of colon are visualized with formed fecal material and gas shadowing distally. There is no observed focal or generalized colon wall thickening or loss of layering.

Pancreas

The pancreas is prominent and hypoechoic as compared to the surrounding isoechoic mesentery. There is no evidence of nodules or cystic lesions. There is no evidence of regional mesenteric inflammation or fluid.

Free Abdomen

Evaluation of the peritoneal cavity did not reveal any evidence of effusion. There are visible mesenteric lymph nodes, one measures 0.41 cm. A sublumbar lymph node is visualized at 0.54 cm. The omentum is generally of normal echogenicity.

ULTRASONOGRAPHIC FINDINGS

- Prominent, hypoechoic pancreas – The pancreatic changes are most consistent with age-related parenchymal remodeling, potentially secondary to a prior inflammatory episode, early fibrosis or chronic pancreatitis.
- Prominent/visible mesenteric lymph nodes – The prominent abdominal lymph nodes are most consistent with reactive lymphadenitis or lymphoid hyperplasia. Neoplastic infiltration is considered less likely. Prominent lymph nodes are very common in young dogs and cats.

INTERPRETATION OF THE FINDINGS & FURTHER RECOMMENDATIONS

Today's scan appears relatively normal. There are some prominent mesenteric lymph nodes that are likely normal for this age of a pet. The pancreas is somewhat prominent. If signs of pancreatitis are present, then consider an fPLI level. If no signs of pancreatitis, then I would recommend continued monitoring.



Portable Animal Welfare Sonography, Inc.

IMAGING PERFORMED BY
pawsonography@gmail.com 530-786-8340

PATIENT

TaterTot Tockes

SPECIES

Feline

BREED

DSH

SEX

Male

AGE

19 Weeks

WEIGHT

4.87 Pounds

INTERPRETED BY

Kathleen Sennello DVM,
MS, Diplomate ACVIM
(Small Animal Internal
Medicine)

IMAGING BY

Loetitia Saint-Jacques,
LVT

HOSPITAL NAME

South Reno VH

REFERRING VET

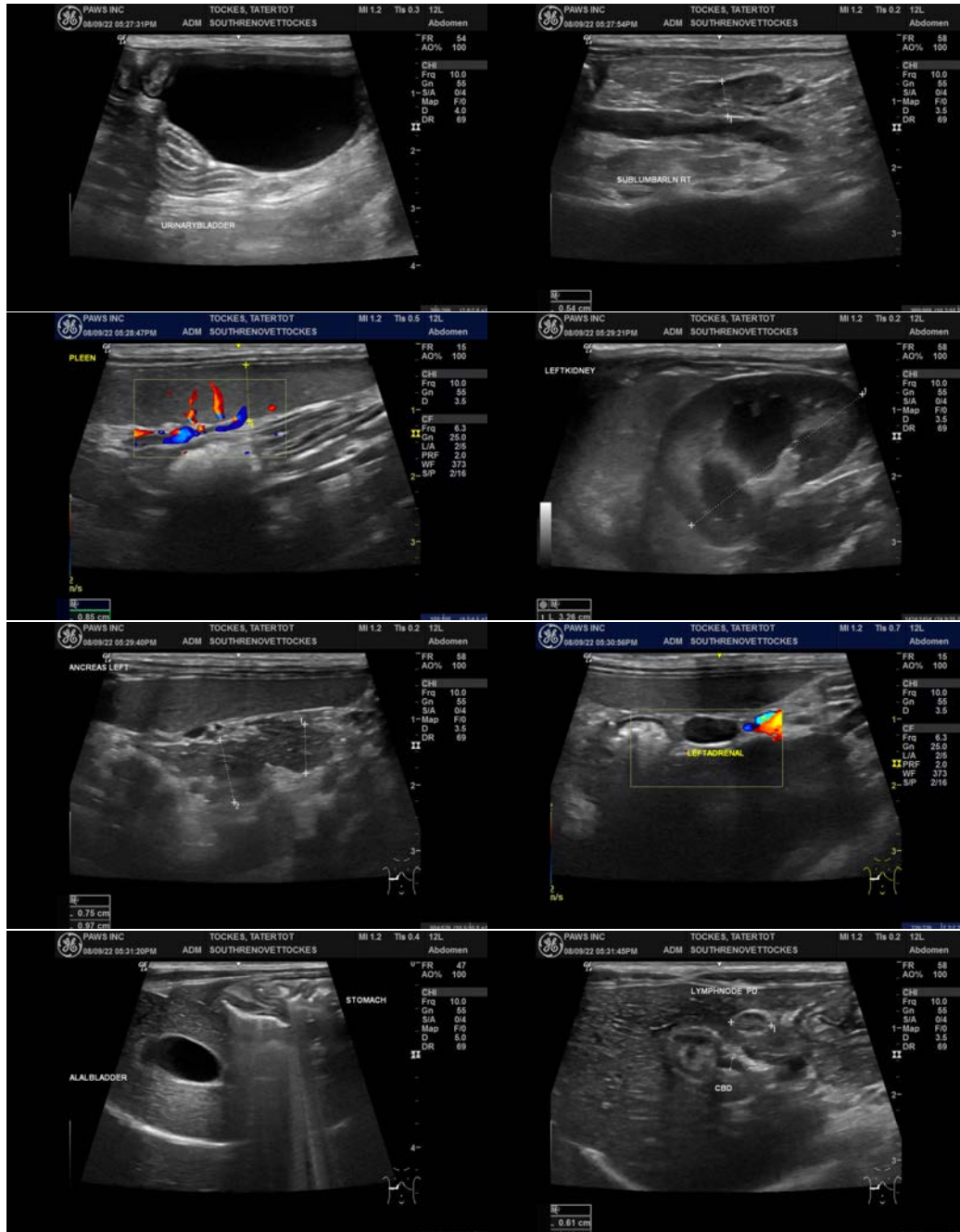
Dr. Schmitt

INVOICE

40293

DATE

8/10/22





PATIENT

TaterTot Tockes

SPECIES

Feline

BREED

DSH

SEX

Male

AGE

19 Weeks

WEIGHT

4.87 Pounds

INTERPRETED BY

Kathleen Sennello DVM,
MS, Diplomate ACVIM
(Small Animal Internal
Medicine)

IMAGING BY

Loetitia Saint-Jacques,
LVT

HOSPITAL NAME

South Reno VH

REFERRING VET

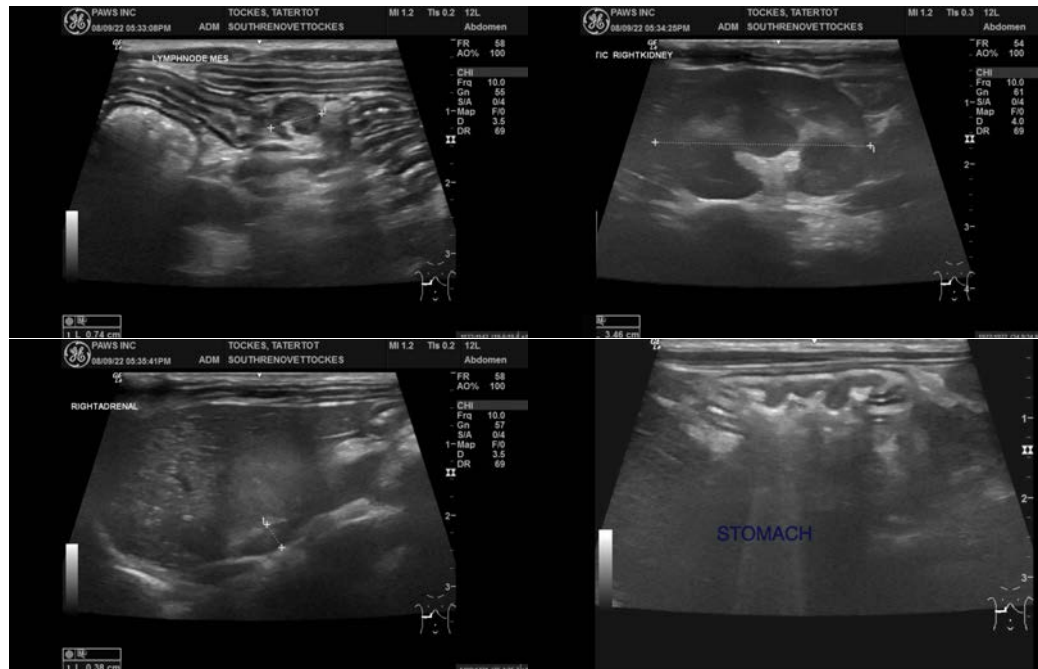
Dr. Schmitt

INVOICE

40293

DATE

8/10/22



The information and recommendations provided are based on the images presented by the referring veterinarian/sonographer. No evaluation can be communicated regarding pathology that was not visible in the image/video clips provided.

Thank you for this referral. If the clinical or image interpretation does not parallel your findings or if I can be of any further assistance please contact me.

Kathleen Sennello DVM,MS, Diplomate ACVIM (Small animal Internal Medicine)
kathleen.sennello@sonopath.com