



PATIENT PRESENTING CLINICAL SIGNS

Sydney Haycock History: No sedation. Echo prev done w/ Sonopath- 8/7/2022 Vomiting-Acute 8/7/2022 Hepatomegaly 8/7/2022 Liver Enzymes Elevated Seen on emergency. Chief Complaint: vomiting, stretching, painful

SPECIES History: presented at ER on 8/7/2022 for vomiting and abdominal pain. She ate her dinner around 4:30pm. Around 6:00pm she started downward dog stretching. She then vomited 4-5x. She has not gotten into anything that owners know of. She keeps licking herself since vomiting. heart murmur -
Canine vetmedin 1.25mg PO BID prev elevated kidney values and currently on a low protein diet.

BREED Abnormal PE/Chem/CBC/UA Results: Lymp 0.86, BUN 51, ALT 555, ALP >2000, chol 434 cPL- abnormal

Mini Schnauzer **ULTRASONOGRAPHIC EXAMINATION OF THE ABDOMEN**

SEX *Urinary System*

Spayed Female The urinary bladder is moderately distended with anechoic urine. The Bladder wall, trigone, ureteral papillae and visible urethra (to a depth of 2.0 cm) appear normal with no evidence of wall thickening, mucosal irregularities, masses or cystic calculi.

AGE The left kidney has a normal shape and size (4.16 cm). Overall echogenicity is normal with adequate corticomedullary distinction and a typical 1:3 cortex:medulla ratio. There is no evidence of perinephric inflammation or effusion. There is no evidence of pyelectasia, nephroliths, infarcts or hydroureter. Renal vasculature is normal.
11 Years

WEIGHT The right kidney has a normal shape and size (4.34 cm). Overall echogenicity is normal with adequate corticomedullary distinction and a typical 1:3 cortex:medulla ratio. There is no evidence of perinephric inflammation or effusion. There is no evidence of pyelectasia, nephroliths, infarcts or hydroureter. Renal vasculature is normal.
6 kg

INTERPRETED BY

Kathleen Sennello DVM,
MS, Diplomate ACVIM
(Small Animal Internal
Medicine)

Adrenal Glands

The left adrenal gland is normal in size measuring 0.52 cm at the caudal pole. It is observed in its normal position cranial to the left renal artery. It is normal in appearance (uniformly hypoechoic) and shape with no evidence of a mass effect.

IMAGING PERFORMED BY

Loetitia Saint-Jacques, RVT

The right adrenal gland is normal in size measuring 0.52 cm at the caudal pole. It is observed in its normal position between the cranial aspect of the right kidney and the caudal vena cava. It is normal in appearance (uniformly hypoechoic) and shape with no evidence of a mass effect.

HOSPITAL NAME *Spleen*

North Hills VC The spleen is subjectively normal in size, echotexture is homogenous, and the splenic capsule is smooth with no irregularities. The blood flow through the hilus and splenic parenchyma appears normal. There is a very small hypoechoic lesion towards the periphery of the spleen, measuring 0.5 cm and even smaller discreet hyperechoic nodules visualized, measuring 0.27 cm.

REFERRING VET

Dr. David Bagget *Liver*

INVOICE The liver is subjectively large in size, and echogenicity with smooth peripheral margins. The parenchyma is heterogenous in echotexture with subtle, indistinct focal mottling. The visible portions of the vasculature and biliary tract appear normal. There is a large, somewhat cavitated lesion
16809

DATE

8/10/22



PATIENT visualized in the left side of the liver, measuring approximately 5.12 cm x 5.28 cm. Additionally, there is a small hypoechoic nodule visualized on the right side, measuring 1.1 cm.

Sydney Haycock

SPECIES

Canine

The gallbladder lumen is significantly distended. Some areas of the wall appear mildly thickened with adherent debris. There is a large amount of primarily non-organized echogenic debris in the dependent portion of the gallbladder. There is no evidence of bile duct dilation or inflammation around the gall bladder.

BREED

Mini Schnauzer

Gastrointestinal

The stomach contains minimal luminal contents. It measures at a normal thickness of <0.7 cm with some variability due to the presence of rugal folds. The distinction of the gastric wall layers is adequate and there is no impression of reduced peristaltic activity. No masses or focal lesions were observed.

SEX

Spayed Female

The visualized areas of duodenum, jejunum and ileum have a uniform diameter with minimal fluid distension. Wall appears subjectively, mildly increased. Bowel loops follow a typical curvilinear path with distinct wall layering. Visualized peristalsis appears appropriate. There were no focal lesions consistent with obstruction or a mass effect observed. The duodenum measured 0.34 cm. The jejunum measures 0.28 cm. There is mild mucosal speckling observed.

AGE

11 Years

The ileocecal junction was visualized and exhibited normal intact wall layering and is subjectively of normal thickness. Sections of colon are visualized with formed fecal material and gas shadowing distally. There is no observed focal or generalized colon wall thickening or loss of layering.

WEIGHT

6 kg

Pancreas

The pancreas is prominent and mottled compared to the surrounding isoechoic mesentery. There is no evidence of nodules or cystic lesions. There is no evidence of regional mesenteric inflammation or fluid.

INTERPRETED BY

Kathleen Sennello DVM,
MS, Diplomate ACVIM
(Small Animal Internal
Medicine)

Free Abdomen

A scant amount of free abdominal fluid was noted. No lymphadenopathy noted. The omentum is hyperechoic in the cranial abdomen.

IMAGING PERFORMED BY

Loetitia Saint-Jacques, RVT

Other

A brief view of the heart was submitted. No pericardial effusion was seen.

HOSPITAL NAME

North Hills VC

ULTRASONOGRAPHIC FINDINGS

REFERRING VET

Dr. David Bagget

- Small hypoechoic nodule visualized within the splenic parenchyma. There is a non-cavitated, hypoechoic splenic nodule visualized. Differentials include lymphoid hyperplasia, extramedullary hematopoiesis, infiltrative neoplasia, inflammation, other. Cytology or histopathology would be necessary to get a definitive diagnosis.
- Prominent mottled pancreas. The pancreatic changes are most consistent with age-related parenchymal remodeling, potentially secondary to a prior inflammatory episode, early fibrosis or chronic pancreatitis.

INVOICE

16809

DATE

8/10/22



PATIENT

Sydney Haycock

SPECIES

Canine

BREED

Mini Schnauzer

SEX

Spayed Female

AGE

11 Years

WEIGHT

6 kg

- Large heterogeneous liver with a cavitated liver mass. The diffuse hepatic changes are non-specific and could be consistent with vacuolar hepatopathy, nodular hyperplasia, inflammatory/immune-mediated disease, fibrosis, extramedullary hematopoiesis, toxic hepatopathy (e.g., copper), infiltrative neoplasia (less likely) or other hepatopathy. This could represent a benign or neoplastic lesion with a necrotic center. Additionally, a cystic or abscessed structure could be considered.
- Large gallbladder sludge. The significance of the aggregated gallbladder debris is unclear. This could represent an early mucocele, cholestasis, or may be secondary to fasting.
- Prominent small intestine with mucosal speckling
- Scant free abdominal fluid

INTERPRETATION OF THE FINDINGS & FURTHER RECOMMENDATIONS

There is a large, somewhat cavitated lesion visualized within the liver. There is some cranial abdominal inflammation associated with this area, but the tissue around it appears relatively normal. Primary differential would be a mass effect with a necrotic center or hemorrhage. Alternate differentials would be a cystic structure or an abscess. Consider a contrast CT scan for surgical planning and to evaluate for any metastatic lesions and consider referral to a veterinary surgeon for resection of this liver lobe. If surgical intervention will not be considered, then consider a fine needle aspirate with a small gauge needle for cytology and aerobic and anaerobic cultures.

Consider three view thoracic radiographs to rule out concurrent thoracic disease/involvement.

There are two small lesions in the spleen. These would be challenging to sample at this time. I recommend continued monitoring and evaluation with a CT scan +/- surgery if this option is chosen.

There is a large amount of debris visualized within the gallbladder. The gallbladder wall appears relatively healthy, but given the chronic liver enzyme elevations, consider starting Ursodiol chronically and recommend continued monitoring of the gallbladder for progression to a surgical lesion.

I suspect the symptoms described are secondary to the mass lesion but there is some mild mucosal speckling evident in the small intestine, which could be an indicator of underlying small intestinal disease. If this is strongly suspected, then consider additional work up for primary GI disease.

INTERPRETED BY

Kathleen Sennello DVM,
MS, Diplomate ACVIM
(Small Animal Internal
Medicine)

IMAGING PERFORMED BY

Loetitia Saint-Jacques, RVT

HOSPITAL NAME

North Hills VC

REFERRING VET

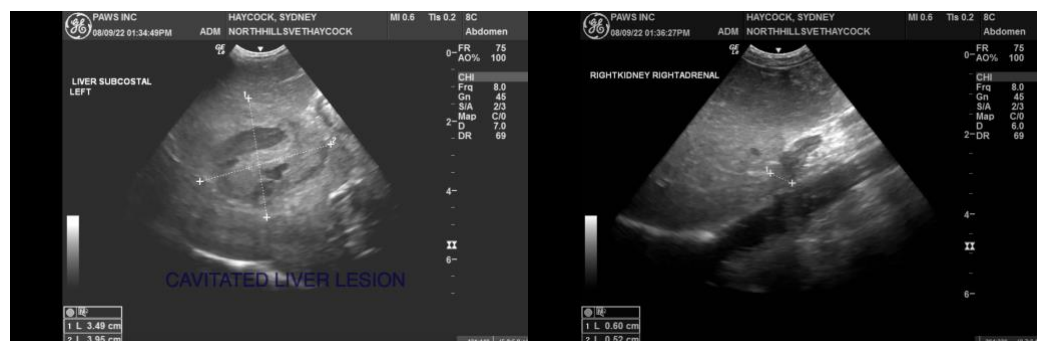
Dr. David Bagget

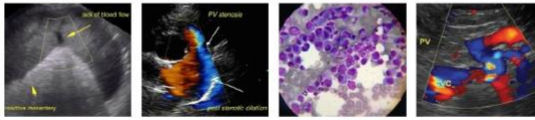
INVOICE

16809

DATE

8/10/22





PATIENT

Sydney Haycock

SPECIES

Canine

BREED

Mini Schnauzer

SEX

Spayed Female

AGE

11 Years

WEIGHT

6 kg

INTERPRETED BY

Kathleen Sennello DVM,
MS, Diplomate ACVIM
(Small Animal Internal
Medicine)

IMAGING PERFORMED BY

Loetitia Saint-Jacques, RVT

HOSPITAL NAME

North Hills VC

REFERRING VET

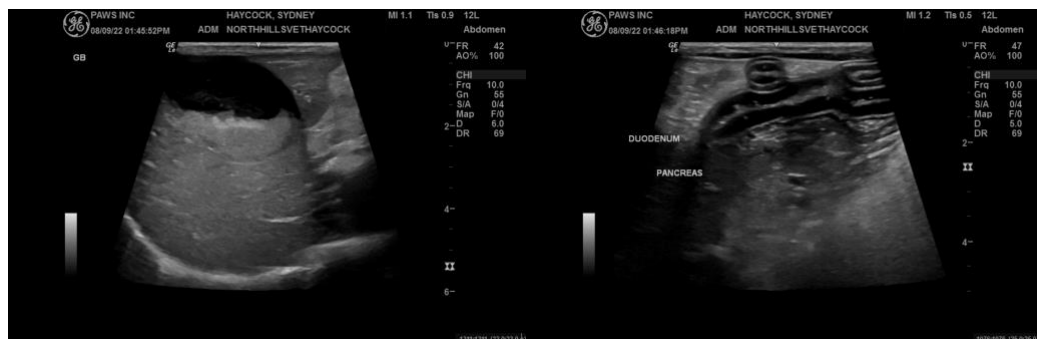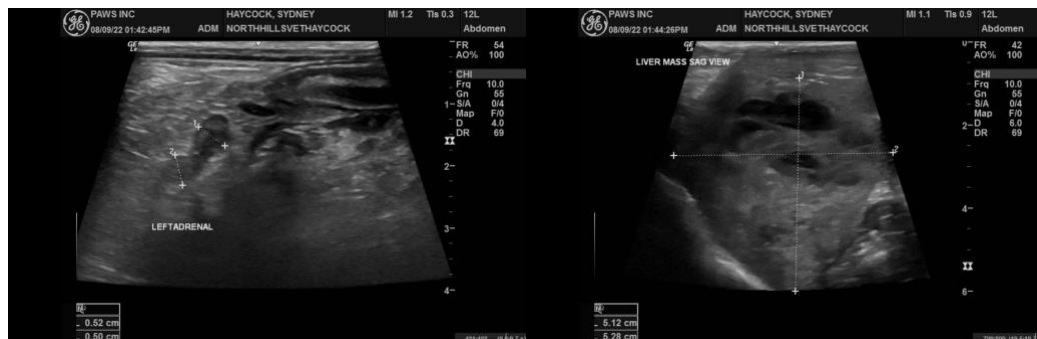
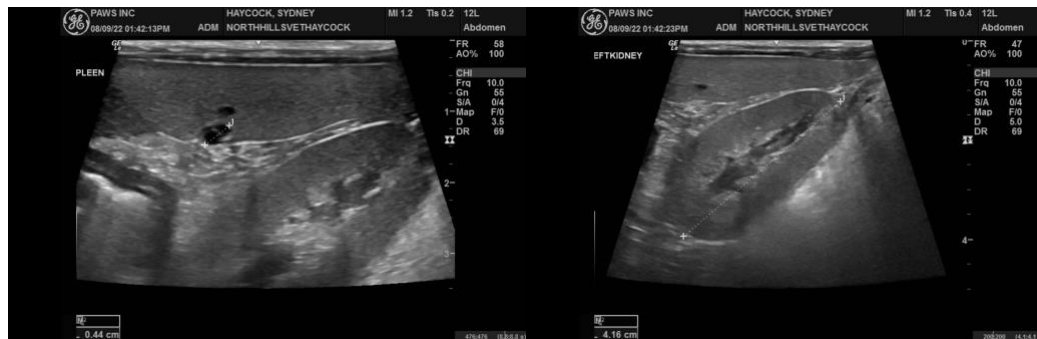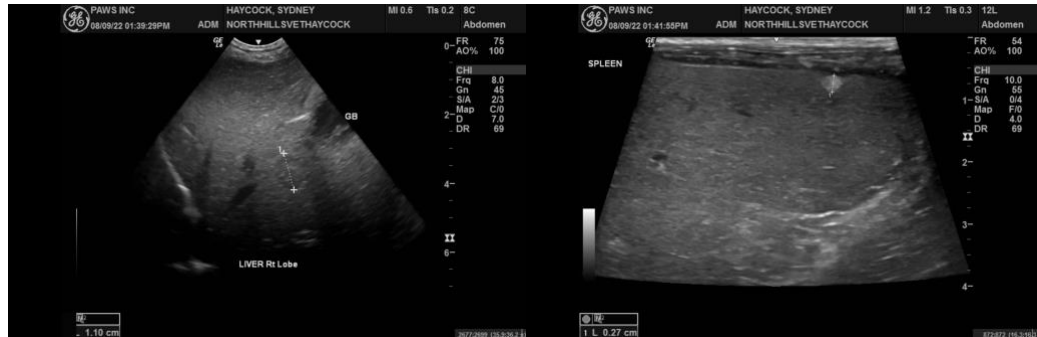
Dr. David Bagget

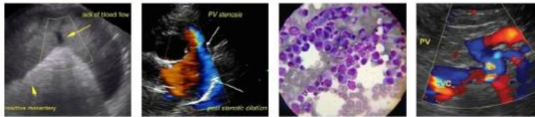
INVOICE

16809

DATE

8/10/22





PATIENT

Sydney Haycock

SPECIES

Canine

BREED

Mini Schnauzer

SEX

Spayed Female

AGE

11 Years

WEIGHT

6 kg

INTERPRETED BY

Kathleen Sennello DVM,
MS, Diplomate ACVIM
(Small Animal Internal
Medicine)

The information and recommendations provided are based on the images presented by the referring veterinarian. No evaluation can be communicated regarding pathology that was not visible in the image/video clips provided.

Thank you for this referral. If the clinical or image interpretation does not parallel your findings or if I can be of any further assistance please contact me.

Kathleen Sennello DVM,MS, Diplomate ACVIM (Small animal Internal Medicine)
kathleen.sennello@sonopath.com

IMAGING PERFORMED BY

Loetitia Saint-Jacques, RVT

HOSPITAL NAME

North Hills VC

REFERRING VET

Dr. David Bagget

INVOICE

16809

DATE

8/10/22

