



**PATIENT PRESENTING CLINICAL SIGNS**

**Lola Lemos** Ongoing regurgitation/gagging. R/O: IBD, pancreatitis, malignancy, other. New golf-ball-sized STL on neck was FNA'd recently >> RBCs only.

**SPECIES** Abnormal PE/Chem/CBC/UA Results: Recent rads of the chest: large tracheal lymph node - suspicious of lymphoma. Recent abdominal rads: appearance of GI tract consistent with non-specific gastroenteritis. Possibly pancreatitis. O has declined more blood work (GI panel) at the moment, but will return for this if indicated by sonography. Chem17/CBC/lytes on 8/3 were normal.

**Canine**

**BREED ULTRASONOGRAPHIC EXAMINATION OF THE ABDOMEN**

**Lab** *Urinary System*

The urinary bladder is moderately distended with anechoic urine. The Bladder wall, trigone, ureteral papillae and visible urethra (to a depth of 2cm) appear normal with no evidence of wall thickening, mucosal irregularities, masses or cystic calculi.

**SEX**

Spayed Female

The left kidney has a normal shape and size (5.94 cm). Overall echogenicity is slightly hyperechoic with poor corticomedullary distinction and a typical 1:3 cortex:medulla ratio. There is no evidence of perinephric inflammation or effusion. There is no evidence of pyelectasia, nephroliths, infarcts or hydroureter. Renal vasculature is normal.

**AGE**

15 Years

The right kidney has a normal shape and size (5.81 cm). Overall echogenicity is slightly hyperechoic with poor corticomedullary distinction and a typical 1:3 cortex:medulla ratio. There is no evidence of perinephric inflammation or effusion. There is no evidence of pyelectasia, nephroliths, infarcts or hydroureter. Renal vasculature is normal.

**WEIGHT**

55 Pounds

*Adrenal Glands*

**INTERPRETED BY**

Kathleen Sennello DVM,  
MS, Diplomate ACVIM  
(Small Animal Internal  
Medicine)

The left adrenal gland is normal in size measuring 0.62 cm at the caudal pole. It is observed in its normal position cranial to the left renal artery. It is normal in appearance (uniformly hypoechoic) and shape with no evidence of a mass effect.

The right adrenal gland is normal in size measuring 0.75 cm at the caudal pole. It is observed in its normal position between the cranial aspect of the right kidney and the caudal vena cava. It is normal in appearance (uniformly hypoechoic) and shape with no evidence of a mass effect.

**IMAGING PERFORMED BY**

Dr. Sorbo

*Spleen*

**HOSPITAL NAME**

Mill Brook AC

The spleen is subjectively normal in size, echotexture is homogenous, and the splenic capsule is smooth with no irregularities. The blood flow through the hilus and splenic parenchyma appears normal. No focal parenchymal abnormalities are visualized.

*Liver*

**REFERRING VET**

Dr. Sorbo

The liver is subjectively normal in size, and echogenicity with smooth peripheral margins. The parenchyma is heterogenous in echotexture with subtle, indistinct focal mottling. The visible portions of the vasculature and biliary tract appear normal. No focal nodules or cystic lesions are observed.

The gallbladder lumen is moderately distended. The wall of the gall bladder is not thickened and has a smooth mucosal surface. Luminal contents are primarily anechoic. The cystic and common bile ducts are normal/not visible.

**INVOICE**

40295

**DATE**

8/10/22



**PATIENT**

***Gastrointestinal***

Lola Lemos

The stomach contains minimal luminal contents. It measures at a normal thickness of <0.7cm with some variability due to the presence of rugal folds. The distinction of the gastric wall layers is adequate and there is no impression of reduced peristaltic activity. No masses or focal lesions were observed.

**SPECIES**

Canine

The visualized areas of duodenum, jejunum and ileum have a relatively uniform diameter with minimal fluid distension. Wall thickness is normal. Bowel loops follow a curvilinear path with distinct wall layering maintaining the typical 1:3 muscularis:mucosa layer ratio. Jejunum wall measured 0.35 cm.

**BREED**

Lab

Visualized peristalsis appears appropriate. There were no focal lesions consistent with obstruction or a mass effect observed.

**SEX**

Spayed Female

The ileocecal junction was visualized and exhibited normal intact wall layering and is subjectively of normal thickness. Sections of colon are visualized with formed fecal material and gas shadowing distally. There is no observed focal or generalized colon wall thickening or loss of layering.

***Pancreas***

**AGE**

15 Years

The pancreas is normal and isoechoic to surrounding mesentery. There is no evidence of nodules or cystic lesions. There is no evidence of regional mesenteric inflammation or fluid.

***Free Abdomen***

**WEIGHT**

55 Pounds

Evaluation of the peritoneal cavity did not reveal any evidence of effusion, or subjective lymphadenomegaly. The Medial iliac nodes appear normal and there was no evidence of a caudal aortic thrombus at the bifurcation. The omentum is of normal uniform echogenicity.

**ULTRASONOGRAPHIC FINDINGS**

- Decreased corticomedullary distinction in both kidneys – The bilateral renal findings are consistent with age-related change.
- Heterogeneous liver – The diffuse hepatic changes are non-specific and could be consistent with vacuolar hepatopathy, nodular hyperplasia, inflammatory/immune-mediated disease, fibrosis, extramedullary hematopoiesis, toxic hepatopathy (e.g., copper), infiltrative neoplasia (less likely) or other hepatopathy. These types of changes can also be seen in some normal older dogs (remodeling, regenerative nodules, etc.).

**INTERPRETED BY**

Kathleen Sennello DVM,  
MS, Diplomate ACVIM  
(Small Animal Internal  
Medicine)

**IMAGING PERFORMED BY**

Dr. Sorbo

**HOSPITAL NAME**

Mill Brook AC

**REFERRING VET**

Dr. Sorbo

**INVOICE**

40295

**DATE**

8/10/22

**INTERPRETATION OF THE FINDINGS & FURTHER RECOMMENDATIONS**

No focal lesions were visualized today associated with the gastrointestinal tract. If regurgitation and vomiting are the primary symptoms exhibited, I would consider evaluation of the cranial aspect of the GI tract, including a sedated oral/laryngeal exam, and upper GI endoscopy and fluoroscopy to evaluate the esophagus, esophageal mucosa, sphincter, and stomach. Prior to these steps, I would recommend 3-view thoracic radiographs to look for evidence of megaesophagus, pulmonary lesions, etc. Full bloodwork is recommended to evaluate for metabolic disease



**PATIENT**

Lola Lemos

**SPECIES**

Canine

**BREED**

Lab

**SEX**

Spayed Female

**AGE**

15 Years

**WEIGHT**

55 Pounds

**INTERPRETED BY**

Kathleen Sennello DVM,  
MS, Diplomate ACVIM  
(Small Animal Internal  
Medicine)

**IMAGING  
PERFORMED BY**

Dr. Sorbo

**HOSPITAL NAME**

Mill Brook AC

**REFERRING VET**

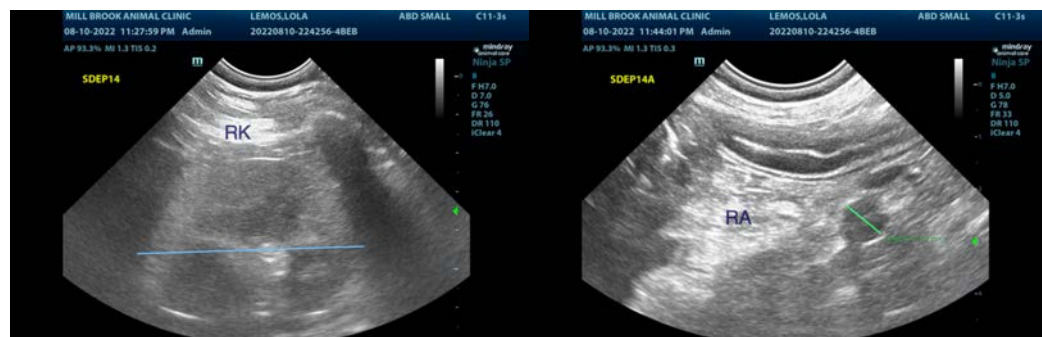
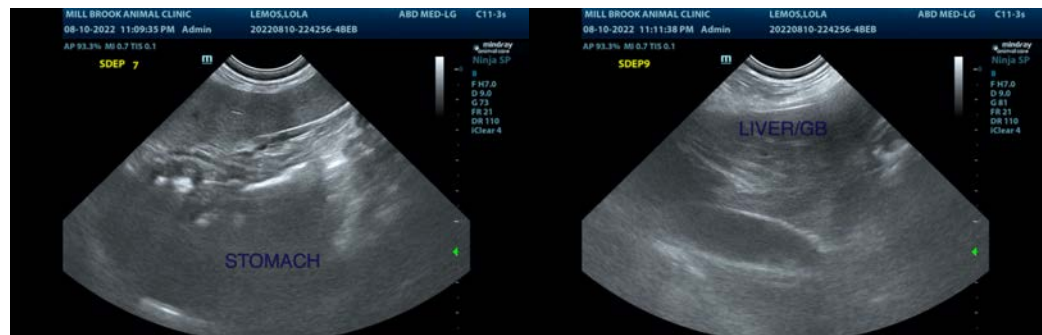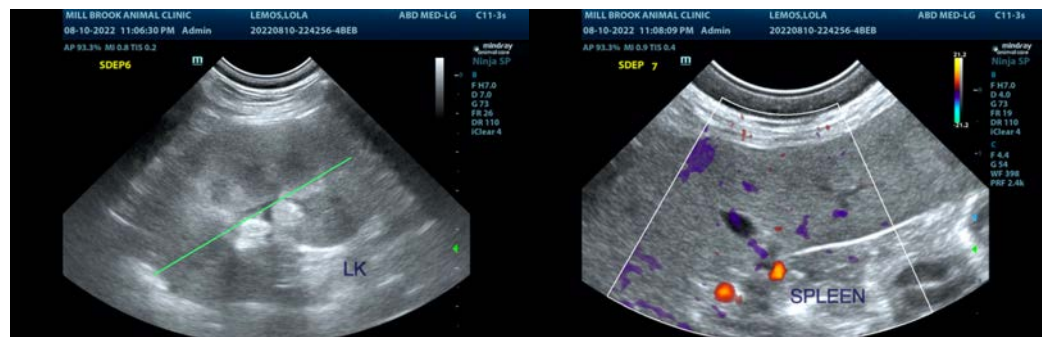
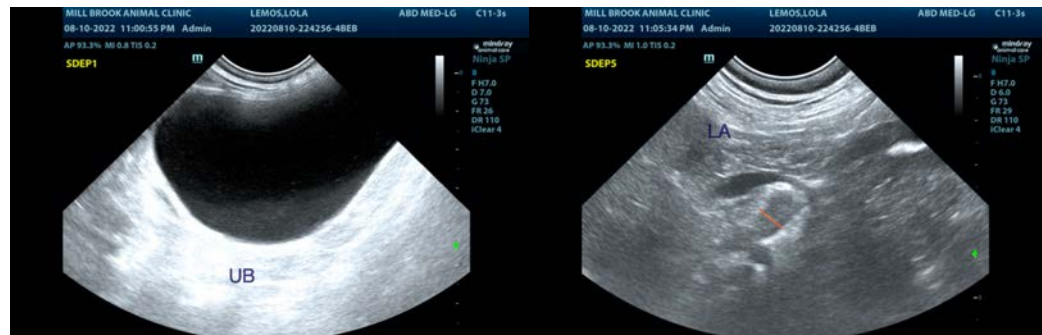
Dr. Sorbo

**INVOICE**

40295

**DATE**

8/10/22





**PATIENT**

Lola Lemos

**SPECIES**

Canine

**BREED**

Lab

**SEX**

Spayed Female

**AGE**

15 Years

**WEIGHT**

55 Pounds

**INTERPRETED BY**

Kathleen Sennello DVM,  
MS, Diplomate ACVIM  
(Small Animal Internal  
Medicine)

**IMAGING  
PERFORMED BY**

Dr. Sorbo

**HOSPITAL NAME**

Mill Brook AC

**REFERRING VET**

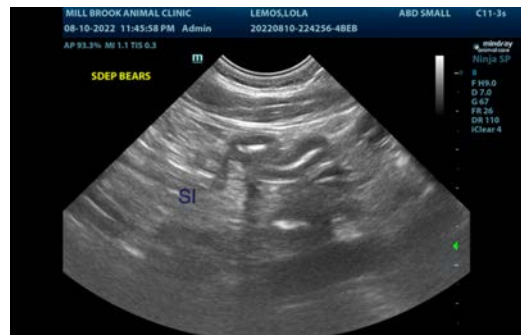Dr. Sorbo

**INVOICE**

40295

**DATE**

8/10/22



The information and recommendations provided are based on the images presented by the referring veterinarian/sonographer. No evaluation can be communicated regarding pathology that was not visible in the image/video clips provided.

Thank you for this referral. If the clinical or image interpretation does not parallel your findings or if I can be of any further assistance please contact me.

Kathleen Sennello DVM,MS, Diplomate ACVIM (Small animal Internal Medicine)

kathleen.sennello@sonopath.com