



**PATIENT**

Buster Southard

**SPECIES**

Canine

**BREED**

Lab Retriever

**SEX**

Neutered Male

**AGE**

7 Years

**WEIGHT**

97 Pounds

**INTERPRETED BY**

Kathleen Sennello DVM,  
MS, Diplomate ACVIM  
(Small Animal Internal  
Medicine)

**IMAGING  
PERFORMED BY**

Dr. Sorbo

**HOSPITAL NAME**

Mill Brook AC - VBF

**REFERRING VET**

Dr. Sorbo

**INVOICE**

40294

**DATE**

8/10/22

**PRESENTING CLINICAL SIGNS**

Recurrent v/d. Been managed with Hydrolyzed diet in the past. This scan is to try establish cause of recurring v/d episodes of seemingly unidentified cause.  
Abnormal PE/Chem/CBC/UA Results: Recent CBC/chem17/lytes all normal. Fecal parasitology normal.

**ULTRASONOGRAPHIC EXAMINATION OF THE ABDOMEN**

**Urinary System**

The urinary bladder is moderately distended with anechoic urine. The Bladder wall, trigone, ureteral papillae and visible urethra (to a depth of 2cm) appear normal with no evidence of wall thickening, mucosal irregularities, masses or cystic calculi.

The prostate is normal in size (0.86 cm) and shape for this neutered male dog. The parenchyma is homogenous and the external margins are smooth. The prostatic urethra appears normal with no evidence of irregularity, invasion, mass effect or calculi.

The left kidney has a normal shape and size (6.44 cm). Overall echogenicity is normal with adequate corticomedullary distinction and a typical 1:3 cortex:medulla ratio. There is no evidence of perinephric inflammation or effusion. There is no evidence of pyelectasia, nephroliths, infarcts or hydroureter. Renal vasculature is normal.

The right kidney has a normal shape and size (5.89 cm). Overall echogenicity is normal with adequate corticomedullary distinction and a typical 1:3 cortex:medulla ratio. There is no evidence of perinephric inflammation or effusion. There is no evidence of pyelectasia, nephroliths, infarcts or hydroureter. Renal vasculature is normal.

**Adrenal Glands**

The left adrenal gland is normal in size measuring 0.56 cm at the caudal pole. It is observed in its normal position cranial to the left renal artery. It is normal in appearance (uniformly hypoechoic) and shape with no evidence of a mass effect.

The region of the right adrenal (between right cranial kidney and vena cava) is unremarkable, but the adrenal is not distinctly visualized. No evidence of a mass effect.

**Spleen**

The spleen is subjectively normal in size, echotexture is homogenous, and the splenic capsule is smooth with no irregularities. The blood flow through the hilus and splenic parenchyma appears normal. No focal parenchymal abnormalities are visualized.

**Liver**

The liver is subjectively normal in size, and echogenicity with smooth peripheral margins. The parenchyma is homogenous echotexture. The visible portions of the vasculature and biliary tract appear normal. No focal nodules or cystic lesions are observed.

The gallbladder lumen is moderately distended. The wall of the gall bladder is not thickened and has a smooth mucosal surface. Luminal contents are primarily anechoic. The cystic and common bile ducts are normal/not visible.



**PATIENT**

Buster Southard

**SPECIES**

Canine

**BREED**

Lab Retriever

**SEX**

Neutered Male

**AGE**

7 Years

**WEIGHT**

97 Pounds

**INTERPRETED BY**

Kathleen Sennello DVM,  
MS, Diplomate ACVIM  
(Small Animal Internal  
Medicine)

**IMAGING  
PERFORMED BY**

Dr. Sorbo

**HOSPITAL NAME**

Mill Brook AC - VBF

**REFERRING VET**

Dr. Sorbo

**INVOICE**

40294

**DATE**

8/10/22

**Gastrointestinal**

The stomach contains minimal luminal contents. It measures at a normal thickness of <0.7cm with some variability due to the presence of rugal folds. The distinction of the gastric wall layers is adequate and there is no impression of reduced peristaltic activity. No masses or focal lesions were observed.

The visualized areas of duodenum, jejunum and ileum have a relatively uniform diameter with minimal fluid distension. Wall thickness is normal. Bowel loops follow a curvilinear path with distinct wall layering maintaining the typical 1:3 muscularis:mucosa layer ratio. Jejunum wall measured 0.42 cm. Visualized peristalsis appears appropriate. There were no focal lesions consistent with obstruction or a mass effect observed.

The ileocecal junction was visualized and exhibited normal intact wall layering and is subjectively of normal thickness. Sections of colon are visualized with formed fecal material and gas shadowing distally. There is no observed focal or generalized colon wall thickening or loss of layering.

**Pancreas**

The pancreas is normal and isoechoic to surrounding mesentery. There is no evidence of nodules or cystic lesions. There is no evidence of regional mesenteric inflammation or fluid.

**Free Abdomen**

Evaluation of the peritoneal cavity did not reveal any evidence of effusion, or subjective lymphadenomegaly. The Medial iliac nodes appear normal and there was no evidence of a caudal aortic thrombus at the bifurcation. The omentum is of normal uniform echogenicity.

**ULTRASONOGRAPHIC FINDINGS**

- No significant ultrasonographic lesions observed

**INTERPRETATION OF THE FINDINGS & FURTHER RECOMMENDATIONS**

Today's scan appears relatively normal. No focal lesions were visualized associated with the gastrointestinal tract to explain the vomiting and diarrhea episodes reported. Unfortunately, this is not unusual, as there are many causes for vomiting and diarrhea that cannot be diagnosed by ultrasound alone.

Based on the history provided, baseline lab work is normal, making routine metabolic disease unlikely. Consider an ACTH stimulation test or a baseline cortisol to screen for Addison's disease.

If metabolic disease is thought unlikely, then consider primary GI disease such as food allergy/dietary intolerance, dysbiosis, dietary indiscretion, IBD, and less likely intestinal neoplasia.

- Consider a novel protein/hydrolyzed protein prescription diet. It's noted in the history that this patient is already on a hydrolyzed diet. Consider an alternative diet or confirm the strictness of the current diet plan.
- Consider a GI panel to Texas A&M for a qualitative PLI, TLI, cobalamin and folate to look for evidence of dysbiosis, B12 deficiency, exocrine pancreatic insufficiency, etc.
- Recommend chronic probiotic therapy.
- If symptoms are persisting despite modifications, consider obtaining GI biopsies.



**PATIENT**

Buster Southard

**SPECIES**

Canine

**BREED**

Lab Retriever

**SEX**

Neutered Male

**AGE**

7 Years

**WEIGHT**

97 Pounds

**INTERPRETED BY**

Kathleen Sennello DVM,  
MS, Diplomate ACVIM  
(Small Animal Internal  
Medicine)

**IMAGING  
PERFORMED BY**

Dr. Sorbo

**HOSPITAL NAME**

Mill Brook AC - VBF

**REFERRING VET**

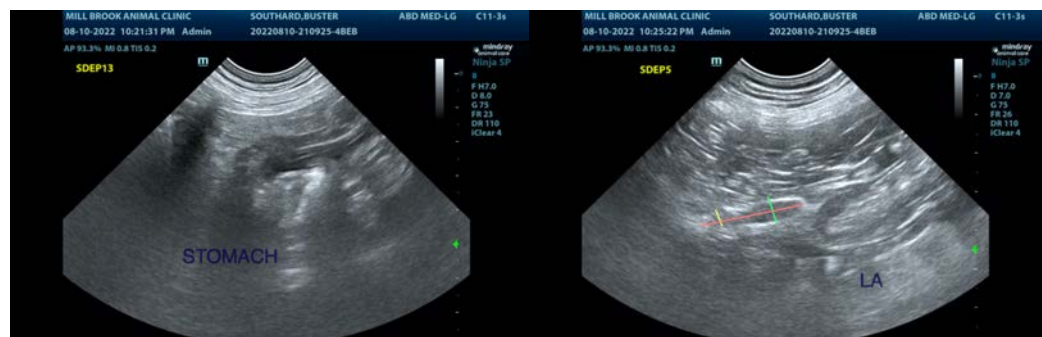
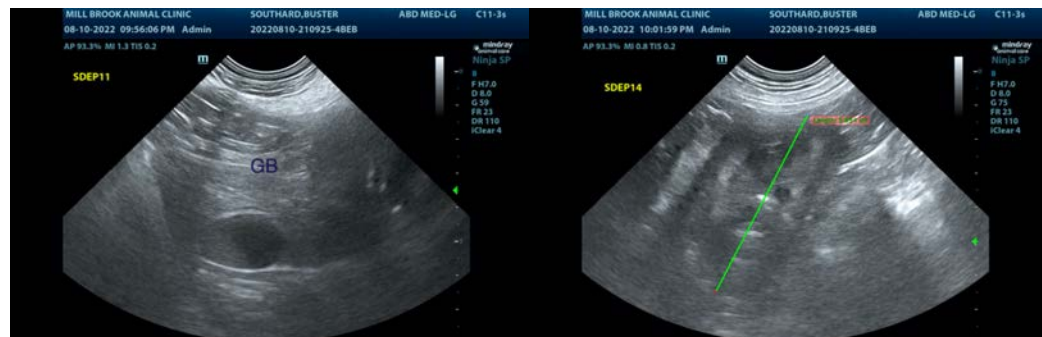
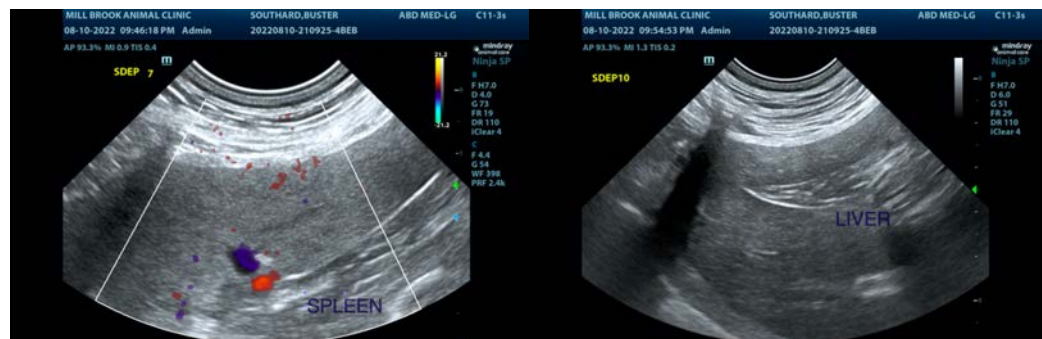
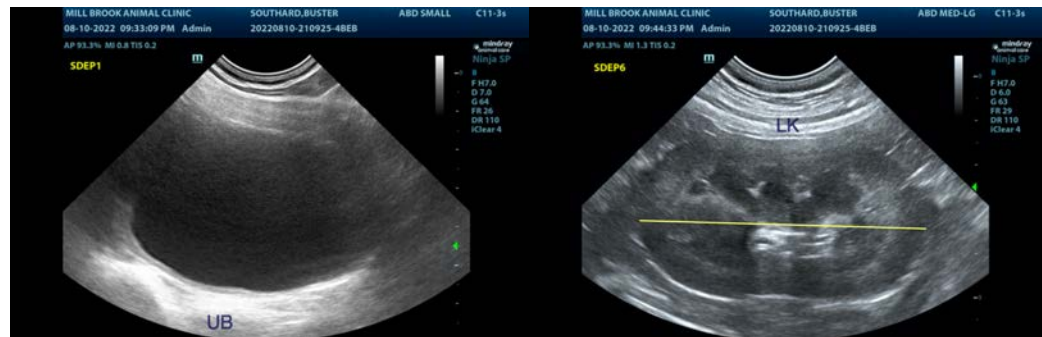
Dr. Sorbo

**INVOICE**

40294

**DATE**

8/10/22



The information and recommendations provided are based on the images presented by the referring veterinarian/sonographer. No evaluation can be communicated regarding pathology that was not visible in the image/video clips provided.

Thank you for this referral. If the clinical or image interpretation does not parallel your findings or if I can be of any further assistance please contact me.

Kathleen Sennello DVM,MS, Diplomate ACVIM (Small animal Internal Medicine)  
kathleen.sennello@sonopath.com