

**PATIENT PRESENTING CLINICAL SIGNS**

Bizzi Frost went to after hours clinic for seizure, anorexia, vomiting meds: clavamox, famotidine, metoclopramide

Abnormal PE/Chem/CBC/UA Results: amylase-unmeasurably high

**SPECIES**

Canine

**ULTRASONOGRAPHIC EXAMINATION OF THE ABDOMEN**

**Urinary System**

**BREED**

Schnauzer

The urinary bladder is moderately distended with anechoic urine. The Bladder wall, trigone, ureteral papillae and visible urethra (to a depth of 2cm) appear normal with no evidence of wall thickening, mucosal irregularities, masses or cystic calculi.

**SEX**

Spayed Female

The left kidney has a normal shape and size (2.86 cm) with mild pyelectasia at 0.17 cm. Overall echogenicity is slightly hyperechoic with mildly reduced corticomedullary distinction and a typical 1:3 cortex:medulla ratio. There is no evidence of perinephric inflammation or effusion. There is no evidence of nephroliths, infarcts or hydroureter. Renal vasculature is normal.

**AGE**

13 Years

The right kidney has a normal shape and size (5.03 cm) with mild pyelectasia at 0.16 cm. Overall echogenicity is slightly hyperechoic with poor corticomedullary distinction and a typical 1:3 cortex:medulla ratio. There is no evidence of perinephric inflammation or effusion. There is no evidence of nephroliths, infarcts or hydroureter. Renal vasculature is normal.

**WEIGHT**

7.1 kg

**Adrenal Glands**

The left adrenal gland is normal in size measuring 0.52 cm at the caudal pole. It is observed in its normal position cranial to the left renal artery. It is normal in appearance (uniformly hypoechoic) and shape with no evidence of a mass effect.

**INTERPRETED BY**

Kathleen Sennello DVM,  
MS, Diplomate ACVIM  
(Small Animal Internal  
Medicine)

The right adrenal gland is normal in size measuring 0.72 cm at the caudal pole. It is observed in its normal position between the cranial aspect of the right kidney and the caudal vena cava. It is normal in appearance (uniformly hypoechoic) and shape with no evidence of a mass effect.

**IMAGING PERFORMED BY**

Kelly Reschny

**Spleen**

The spleen is subjectively normal in size, echotexture is homogenous, and the splenic capsule is smooth with no irregularities. The blood flow through the hilus and splenic parenchyma appears normal. No focal parenchymal abnormalities are visualized.

**HOSPITAL NAME**

Erin Folk AH

**Liver**

The liver is large in size, and normal in echogenicity with smooth peripheral margins. The parenchyma is heterogenous in echotexture with subtle, indistinct focal mottling. The visible portions of the vasculature and biliary tract appear normal. No focal nodules or cystic lesions are observed.

**REFERRING VET**

Dr. Soliman

The gallbladder lumen is moderately distended. The wall of the gall bladder is not thickened and has a smooth mucosal surface. Luminal contents are primarily anechoic. The cystic and common bile ducts are normal/not visible.

**INVOICE**

40313

**Gastrointestinal**

The stomach contains minimal luminal contents. It measures at a normal thickness of <0.7cm with some variability due to the presence of rugal folds. The distinction of the gastric wall layers is adequate and there is no impression of reduced peristaltic activity. No masses or focal lesions were observed.

**DATE**

8/10/22



**PATIENT**

Bizzi Frost

The visualized areas of duodenum, jejunum and ileum have a relatively uniform diameter with minimal fluid distension. Wall thickness is normal. Bowel loops follow a curvilinear path with distinct wall layering maintaining the typical 1:3 muscularis:mucosa layer ratio. Jejunum wall measured 0.31 cm. Visualized peristalsis appears appropriate. There were no focal lesions consistent with obstruction or a mass effect observed.

**SPECIES**

Canine

The ileocecal junction was visualized and exhibited normal intact wall layering and is subjectively of normal thickness. Sections of colon are visualized with formed fecal material and gas shadowing distally. There is no observed focal or generalized colon wall thickening or loss of layering.

**BREED**

Schnauzer

***Pancreas***

The pancreas is prominent and mildly hypoechoic as compared to the surrounding isoechoic mesentery. There is no evidence of nodules or cystic lesions. There is no evidence of regional mesenteric inflammation or fluid.

**SEX**

Spayed Female

***Free Abdomen***

Evaluation of the peritoneal cavity did not reveal any evidence of effusion, or subjective lymphadenomegaly. The Medial iliac nodes appear normal and there was no evidence of a caudal aortic thrombus at the bifurcation. The omentum is of normal uniform echogenicity.

**AGE**

13 Years

**ULTRASONOGRAPHIC FINDINGS**

**WEIGHT**

7.1 kg

- Large, heterogeneous liver – The diffuse hepatic changes are non-specific and could be consistent with vacuolar hepatopathy, nodular hyperplasia, inflammatory/immune-mediated disease, fibrosis, extramedullary hematopoiesis, toxic hepatopathy (e.g., copper), infiltrative neoplasia (less likely) or other hepatopathy.

**INTERPRETED BY**

Kathleen Sennello DVM,  
MS, Diplomate ACVIM  
(Small Animal Internal  
Medicine)

- Prominent, hypoechoic pancreas – The pancreatic changes are most consistent with mild pancreatitis or a recent episode of pancreatic inflammation.
- Decreased corticomedullary distinction in both kidneys with mild pyelectasia – The bilateral renal findings are consistent with age-related change. Pyelectasia of the left/right kidney could be consistent with pyelonephritis, chronic renal disease, secondary to PU/PD or fluid therapy (if applicable), other.

**IMAGING PERFORMED BY**

Kelly Reschny

**INTERPRETATION OF THE FINDINGS & FURTHER RECOMMENDATIONS**

The liver appears somewhat heterogeneous. This is a non-specific finding. If liver enzyme values are normal, then the significance of this is questionable. If liver enzyme elevations are present, consider a liver function test +/- fine needle aspirate.

**HOSPITAL NAME**

Erin Folk AH

The pancreas is difficult to visualize. There is a small section that appears somewhat hypoechoic and mildly prominent. If not already done, consider a quantitative PLI. If elevated, consider treatment for mild pancreatitis.

**REFERRING VET**

Dr. Soliman

Both kidneys have decreased corticomedullary distinction and mild pyelectasia. Much of this is likely age related change, but consider urinalysis and culture as well as a blood pressure evaluation for the pyelectasia noted.

**INVOICE**

40313

An obvious cause for the seizure activity is not visualized. Recommend blood pressure evaluation. Consider possible exposure to medications, toxins, etc. If symptoms persist, consider evaluation by a neurologist.

**DATE**

8/10/22



**PATIENT**

Bizzi Frost

**SPECIES**

Canine

**BREED**

Schnauzer

**SEX**

Spayed Female

**AGE**

13 Years

**WEIGHT**

7.1 kg

**INTERPRETED BY**

Kathleen Sennello DVM,  
MS, Diplomate ACVIM  
(Small Animal Internal  
Medicine)

**IMAGING  
PERFORMED BY**

Kelly Reschny

**HOSPITAL NAME**

Erin Folk AH

**REFERRING VET**

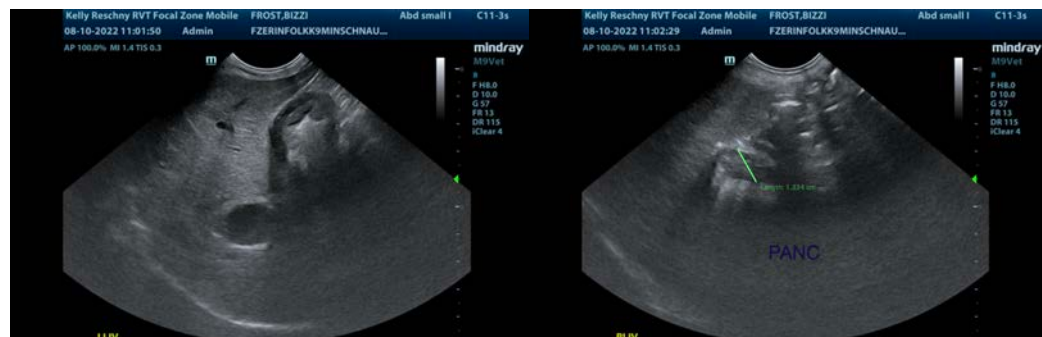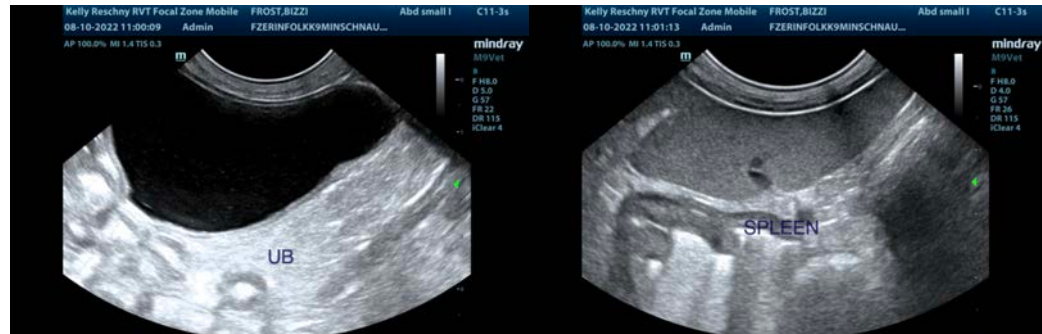
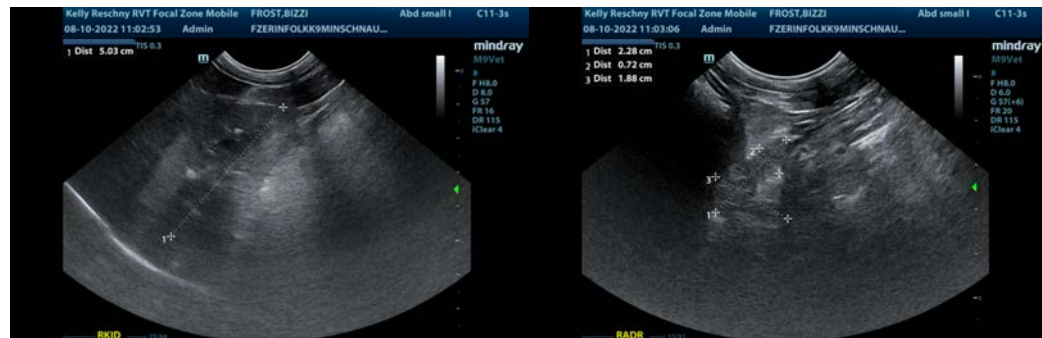
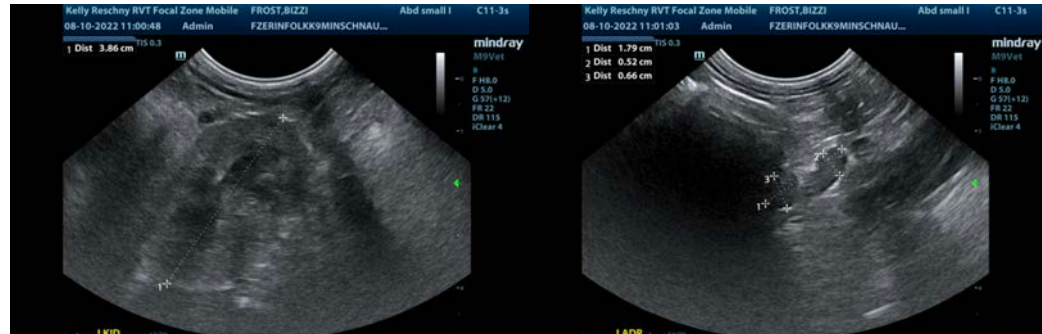Dr. Soliman

**INVOICE**

40313

**DATE**

8/10/22





**PATIENT**

Bizzi Frost

The information and recommendations provided are based on the images presented by the referring veterinarian/sonographer. No evaluation can be communicated regarding pathology that was not visible in the image/video clips provided.

**SPECIES**

Canine

Thank you for this referral. If the clinical or image interpretation does not parallel your findings or if I can be of any further assistance please contact me.

Kathleen Sennello DVM,MS, Diplomate ACVIM (Small animal Internal Medicine)

kathleen.sennello@sonopath.com

**BREED**

Schnauzer

**SEX**

Spayed Female

**AGE**

13 Years

**WEIGHT**

7.1 kg

**INTERPRETED BY**

Kathleen Sennello DVM,  
MS, Diplomate ACVIM  
(Small Animal Internal  
Medicine)

**IMAGING  
PERFORMED BY**

Kelly Reschny

**HOSPITAL NAME**

Erin Folk AH

**REFERRING VET**

Dr. Soliman

**INVOICE**

40313

**DATE**

8/10/22