

**DATE**

8/10/21

**PRESENTING CLINICAL SIGNS**

Vomiting, Diarrhea, Not Eating, Incontinence – Urinary.

History: Date: 08-10-2021 Notes: Not eating, Vomiting Bloody urine Elevated liver values. Referral from RDVM.

**PATIENT**

Stitch Bradbury

Date of Previous IntraPet Ultrasound: No previous

Sedation: IV sedation utilized for AUS

Stat Report: not requested

**SPECIES**

Canine

**ULTRASONOGRAPHIC EXAMINATION OF THE ABDOMEN****Urinary System**

The urinary bladder is moderately distended with anechoic urine. The Bladder wall, trigone, ureteral papillae and visible urethra (to a depth of 2cm) appear normal with no evidence of wall thickening, mucosal irregularities, masses or cystic calculi.

**BREED**

Husky Mix

The prostate is normal in size (1.0 cm) and shape for this neutered male dog. The parenchyma is homogenous and the external margins are smooth. The prostatic urethra appears normal with no evidence of irregularity, invasion, mass effect or calculi.

**SEX**

Neutered male

The left kidney has a normal shape and size (6.15cm). Overall echogenicity is normal with adequate corticomedullary distinction and a typical 1:3 cortex:medulla ratio. There is no evidence of perinephric inflammation or effusion. There is no evidence of pyelectasia, nephroliths, infarcts or hydroureter. Renal vasculature is normal.

**AGE**

2019

**WEIGHT**

55.1 lbs

The right kidney has a normal shape and size (5.27 cm). Overall echogenicity is normal with adequate corticomedullary distinction and a typical 1:3 cortex:medulla ratio. There is no evidence of perinephric inflammation or effusion. There is no evidence of pyelectasia, nephroliths, infarcts or hydroureter. Renal vasculature is normal.

**INTERPRETED BY**

Kathleen Sennello  
DVM, MS, Diplomate  
ACVIM (Small Animal  
Internal Medicine)

**Adrenal Glands**

The left adrenal gland is normal in size measuring 0.63 cm at the caudal pole It is observed in its normal position cranial to the left renal artery. It is normal in appearance (uniformly hypoechoic) and shape with no evidence of a mass effect.

**HOSPITAL NAME**

Animal Emergency  
Hospital

The right adrenal gland is normal in size measuring 0.55 cm at the caudal pole It is observed in its normal position between the cranial aspect of the right kidney and the caudal vena cava. It is normal in appearance (uniformly hypoechoic) and shape with no evidence of a mass effect.

**Spleen****REFERRING VET**

Dr. Ruby

The spleen is subjectively normal in size The spleen echotexture is heterogenous and mottled, the splenic capsule is smooth with no irregularities. The blood flow through the hilus and splenic parenchyma appears normal. No focal parenchymal abnormalities are visualized.

**INVOICE**

91115

**Liver**

The liver is subjectively normal in size, and echogenicity with smooth peripheral margins. The parenchyma is heterogenous in echotexture and hypoechoic with subtle, indistinct focal mottling. The visible portions of the vasculature tract and biliary tract appear normal, but portal markings are prominent. No focal nodules or cystic lesions are observed. The gallbladder lumen is moderately distended. The wall of the gall bladder is not thickened and has a smooth mucosal surface. Luminal contents are primarily anechoic. The cystic and common bile ducts are normal/not visible.

### ***Gastrointestinal***

The stomach contains minimal luminal contents. It measures at a normal thickness of <0.7cm with some variability due to the presence of rugal folds. The distinction of the gastric wall layers is adequate and there is no impression of reduced peristaltic activity. No masses or focal lesions were observed.

The visualized areas of duodenum, jejunum and ileum have a relatively uniform diameter with minimal fluid distension. Wall thickness is normal. Bowel loops follow a curvilinear path with distinct wall layering maintaining the typical 1:3 muscularis:mucosa layer ratio. The duodenum measured as normal (between 0.3-0.5cm in wall thickness) and the jejunum measured as normal (between 0.2-0.47cm.) Visualized peristalsis appears appropriate. There were no focal lesions consistent with obstruction or a mass effect observed.

The ileocecal junction was visualized and exhibited normal intact wall layering and is subjectively of normal thickness. Sections of colon are visualized with formed fecal material and gas shadowing distally. There is no observed focal or generalized colon wall thickening or loss of layering.

### ***Pancreas***

The pancreas is prominent and heterogenous in echotexture and hypoechoic as compared to the surrounding isoechoic mesentery. There is no evidence of nodules or cystic lesions. There is no evidence of regional mesenteric inflammation or fluid.

### ***Free Abdomen***

Evaluation of the peritoneal cavity did not reveal any evidence of effusion, or subjective lymphadenomegally. The Medial iliac nodes appear normal and there was no evidence of a caudal aortic thrombus at the bifurcation. The omentum is of normal uniform echogenicity.

## **ULTRASONOGRAPHIC FINDINGS**

### **PRIMARY FINDINGS:**

- Hypoechoic, heterogenous liver. The diffuse hepatic changes are non-specific and could be consistent with vacuolar hepatopathy, nodular hyperplasia, inflammatory/immune-mediated disease, fibrosis, extramedullary hematopoiesis, toxic hepatopathy (e.g., copper), infiltrative neoplasia (less likely) or other hepatopathy. Signalment and appearance favor an inflammatory or infectious hepatopathy.

### **SECONDARY FINDINGS:**

- Prominent, hypoechoic pancreas with surrounding, hyperechoic mesentery. The pancreatic changes are most consistent with mild pancreatitis or a recent episode of pancreatic inflammation.
- Mildly mottled spleen. The diffuse splenic changes are non-specific and could be consistent with lymphoid hyperplasia, extramedullary hematopoiesis, infiltrative neoplasia, inflammation, other. Cytology or histopathology would be necessary to get a definitive diagnosis.

## INTERPRETATION OF THE FINDINGS & FURTHER RECOMMENDATIONS

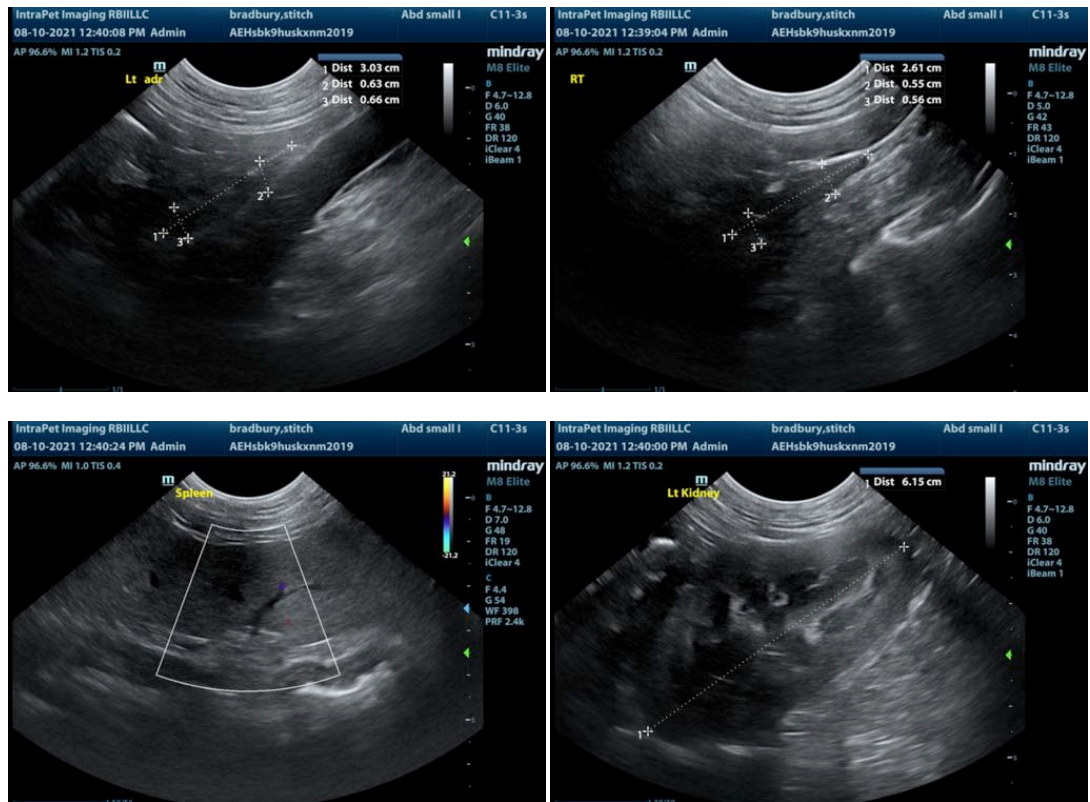
The ultrasonographic abnormalities noted are relatively mild, subtle and non-specific. Based on the history of a significant bilirubin elevation and the absence of any biliary abnormalities or anemia this is likely a primary hepatopathy. Your idea of testing for Leptospirosis is an excellent one.

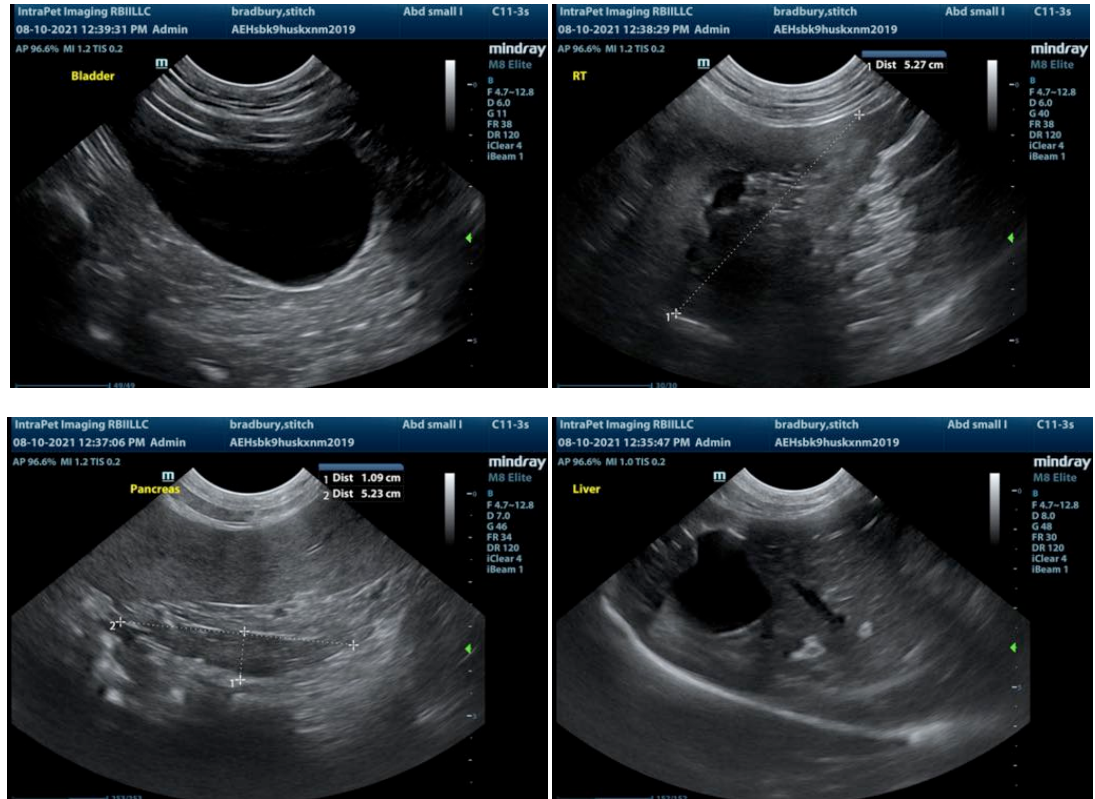
Consider the following:

- Consider close evaluation of history for possible toxic changes examine medications, diet, dietary indiscretion etc...
- Consider PCR on urine/serum for leptospirosis (if not on antibiotics)/serology if recent antibiotic history
- Consider Fine needle aspirate if round cell neoplasia is on your differentia list (25 g needle, normal coags)
- If no response to supportive care (denamarin, fluids, antibiotics,+/- ursodiol etc...) Consider liver biopsy with samples obtained for histopathology, culture, and copper levels.

The changes in the spleen and pancreas are relatively mild. You can consider PLI testing to get more information regarding the pancreas and if a liver aspirate is performed consider aspirating the spleen at the same time providing clotting parameters are normal.

While waiting for test results I recommend treatment for acute liver injury, IV fluids, anti-emetics, Denamarin, Ursodiol and antibiotics (Ampicillin?).





The information and recommendations provided are based on the images presented by the referring veterinarian. No evaluation can be communicated regarding pathology that was not visible in the image/video clips provided.

Thank you for this referral. If the clinical or image interpretation does not parallel your findings or if I can be of any further assistance please contact me.

Kathleen Sennello DVM,MS, Diplomate ACVIM (Small animal Internal Medicine)  
kathleen.sennello@sonopath.com