**DATE**

8/10/2023

PRESENTING CLINICAL SIGNS

Chronic pancreatitis -clinically refractory to treatment and supportive care. Hx of liver mass

PATIENTMister
Stinebaugh

Current Medications: Hydracare 1 pouch SID-BID, Cerenia 16m - 1/4 tab PO SID PRN, Buprenorphine 0.6mg/ml - 0.12 cc OTM PRN for pain monthly solensia inj.

Lab Results: See attached.

Radiographs: See attached.

Date of Previous IntraPet Ultrasound: 9/13/21.

Sedation: Not required to complete full diagnostic ultrasound.

Stat Report: Not requested.

Imaging Performed By: Rachel Brillhart, RDMS.

SPECIES

Feline

BREED

DSH

SEX

Neutered Male

AGE

1/1/2010

WEIGHT

13lbs

INTERPRETED BYKathleen
Sennello DVM,
MS, Diplomate
ACVIM (Small
Animal Internal
Medicine)**HOSPITAL NAME**Noah's Ark
Veterinary and
Boarding
Resort**REFERRING VET**Dr. Harrison-
Jackson**INVOICE**

10404

ULTRASONOGRAPHIC EXAMINATION OF THE ABDOMEN**Urinary System**

The urinary bladder is moderately distended with anechoic urine. The Bladder wall, trigone, ureteral papillae, and visible urethra (to a depth of 2cm) appear normal with no evidence of wall thickening, mucosal irregularities, masses, or cystic calculi.

The left kidney has a normal shape and size (3.97 cm). Overall echogenicity is normal with adequate corticomedullary distinction and a typical 1:3 cortex: medulla ratio. There is no evidence of focal perinephric inflammation or effusion. There is no evidence of pyelectasia, nephroliths, infarcts or hydroureter. Renal vasculature is normal.

The right kidney has a normal shape and size (3.78 cm). Overall echogenicity is normal with adequate corticomedullary distinction and a typical 1:3 cortex: medulla ratio. There is no evidence of focal perinephric inflammation or effusion. There is no evidence of pyelectasia, nephroliths, infarcts or hydroureter. Renal vasculature is normal.

Adrenal Glands

The left adrenal gland is normal in size measuring 0.48 cm at the caudal pole. It is observed in its normal position cranial to the left renal artery. It is normal in appearance (uniformly hypoechoic) and shape with no evidence of a mass effect.

The right adrenal gland is normal in size measuring 0.42 cm at the caudal pole. It is observed in its normal position between the cranial aspect of the right kidney and the caudal vena cava. It is normal in appearance (uniformly hypoechoic) and shape with no evidence of a mass effect.

Spleen

The spleen is subjectively normal in size (0.88 cm), echotexture is homogenous, and the splenic capsule is smooth with no irregularities. The blood flow through the hilus and splenic parenchyma appears normal. No focal parenchymal abnormalities are visualized.

Liver

The liver is subjectively normal in size, and echogenicity with smooth peripheral margins. The parenchyma is mildly heterogenous in echotexture with subtle, indistinct focal mottling. The visible portions of the

vasculature and biliary tract appear normal. There are two slightly irregular cystic structures visualized within the parenchyma one measures 0.72 cm the other is 1.49 cm in diameter. There is additionally a small ill-defined hyperechoic nodule visualized within the parenchyma measuring 0.72 cm and the cystic lesions described are 0.99 cm and 1.49 cm. Additionally, there is a large irregular hyperechoic mass effect in the right side of liver measuring 4.14 cm x 3.31 cm (previous measurement 9/2021 was 2.16 cm x 2.11 cm).

The gallbladder lumen is moderately distended. The wall of the gall bladder is not thickened and has a smooth mucosal surface. Luminal contents are mild and primarily anechoic. The cystic and common bile ducts are normal/not visible.

Gastrointestinal

The stomach contains minimal luminal contents. It measures at a normal thickness of <0.36cm with some variability due to the presence of rugal folds. The distinction of the gastric wall layers is adequate and there is no impression of reduced peristaltic activity. No masses or focal lesions were observed.

The visualized areas of duodenum, jejunum and ileum have a uniform diameter with minimal fluid distension. Wall thickness is normal to slightly increased. Bowel loops follow a typical curvilinear path with distinct wall layering, but some areas display a prominent muscularis layer which does not display the typical 1:3 muscularis: mucosa layer ratio. The jejunum measured 0.28 cm in diameter. Visualized peristalsis appears appropriate. There were no focal lesions consistent with obstruction or a mass effect observed.

The ileocecal junction was visualized and exhibited normal intact wall layering and is subjectively of normal thickness. Sections of colon are visualized with formed fecal material and gas shadowing distally. There is no observed focal or generalized colon wall thickening or loss of layering.

Pancreas

The pancreas is large, prominent, and hypoechoic with mildly reactive mesentery. There is no evidence of nodules or cystic lesions. There is evidence of regional mesenteric inflammation. Consistent with mild pancreatitis.

Free Abdomen

Evaluation of the peritoneal cavity did not reveal any evidence of effusion. There are occasional prominent mesenteric lymph nodes visualized examples measure 0.37 cm and 0.36 cm. Additionally, there is a cluster of small prominent lymph nodes near the ileocecal junction with some associated hyperechoic mesentery measuring 0.2 cm and 0.25 cm. The omentum is generally of normal echogenicity but there is some reactivity noted around the ileocecal junction and the pancreas.

PRIMARY FINDINGS

- Prominent hypoechoic pancreas with prominent pancreatic duct and surrounding reactive mesentery. The pancreatic changes are most consistent with mild pancreatitis/pancreatic infiltration. Recommend fPLI testing and continued monitoring for improvement or possible development of a pancreatic abscess. Consider fine needle aspirate if not improving.
- Mildly heterogenous liver with occasional small cystic lesions and a large right sided mass effect. This mass was previously visualized 9/2021 and it appears to have increased in size.

- Subjectively thickened small intestine with prominent muscularis layer. The small intestinal wall changes could be consistent with an underlying inflammatory process. These types of changes can sometimes be seen in normal older cats. Correlate with clinical signs.
- Prominent/mildly enlarged mesentery lymph nodes. The prominent abdominal lymph nodes are most consistent with reactive lymphadenitis or lymphoid hyperplasia. Neoplastic infiltration is considered less likely.

INTERPRETATION OF THE FINDINGS & FURTHER RECOMMENDATIONS

Many of the changes observed on today's scan are similar to those previously described in 2021. The pancreatic changes are still significant although the clinical significances of this is unclear. Classically this appearance would be most consistent with active mild pancreatitis.

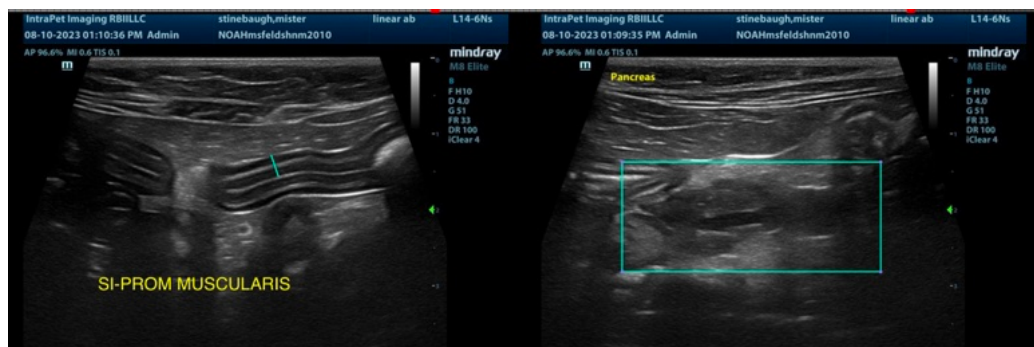
The changes in the liver have progressed but the moderate change over a two-year time period is most consistent with a benign mass lesion. Although, symptoms may be present due to its space occupying nature.

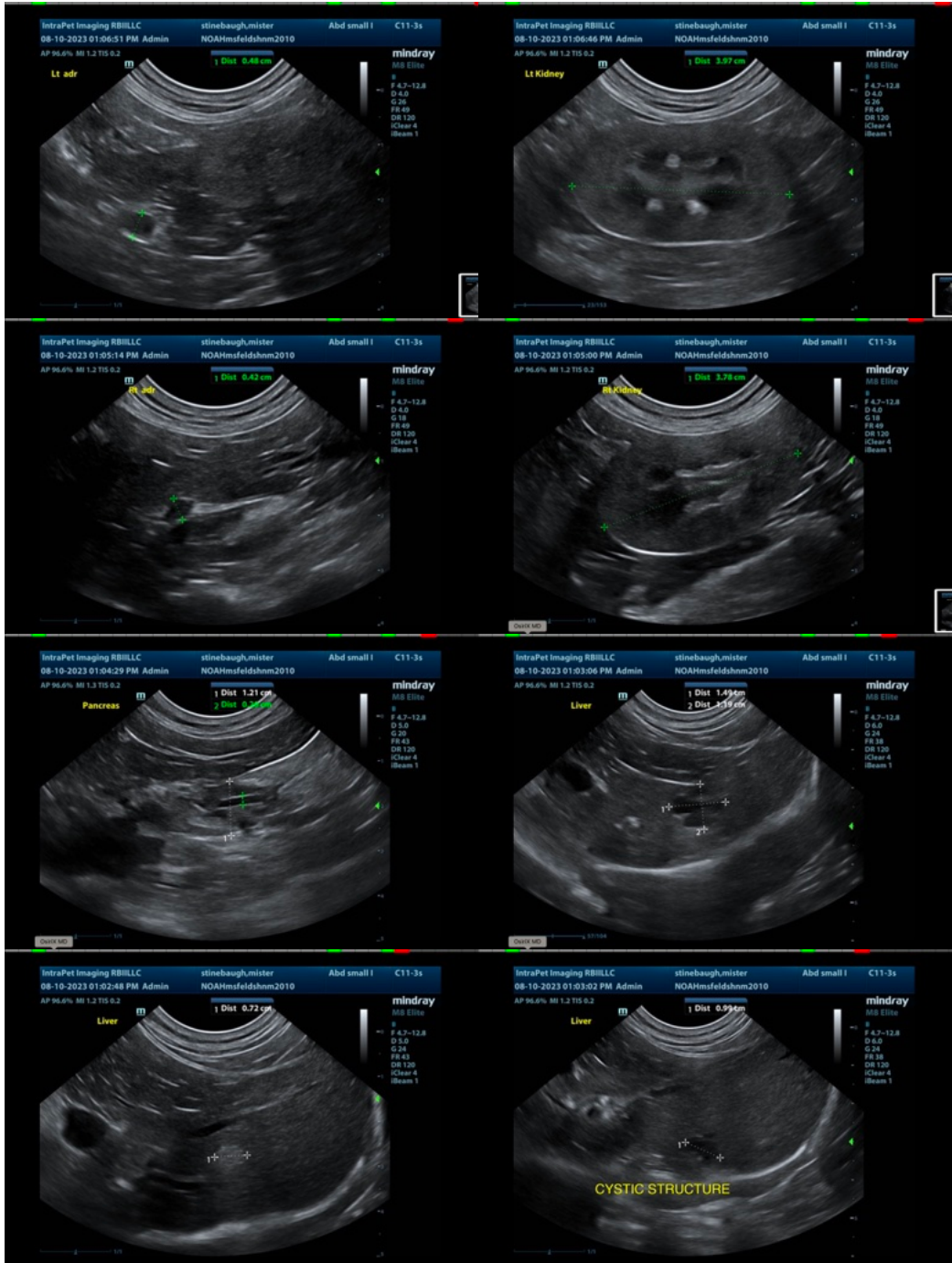
The small bowel appears persistently thickened with prominent muscularis layer with prominent mesenteric lymph nodes. It is unclear what measures have been taken to address this consider the following:

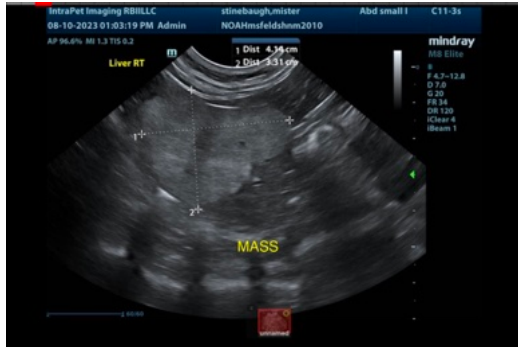
- Consider a novel protein/hydrolyzed protein diet (exclusively at least 4-6 weeks)
- Consider a GI panel to Texas A&M for evaluation of B12 levels, folate, PLI/TLI etc. to further evaluate for pancreatic/small intestinal disease.
- Recommend chronic probiotic therapy.

If this patient is not eating well, has GI signs etc. GI biopsies may be warranted as a concurrent a primary enteropathy is possible.

Recommend three view thoracic radiographs to evaluate for possible concurrent thoracic disease/involvement.







The information and recommendations provided are based on the images presented by the referring veterinarian/sonographer. No evaluation can be communicated regarding pathology that was not visible in the image/video clips provided.

Thank you for this referral. If the clinical or image interpretation does not parallel your findings or if I can be of any further assistance, please contact me.

Kathleen Sennello DVM, MS, Diplomate ACVIM (Small animal Internal Medicine)
info@sonopath.com