

**DATE PRESENTING CLINICAL SIGNS**

7/8/22 Vomiting, ascites, dull to obtunded.

**PATIENT** Current Medications: None listed.Bella Funk Date of Previous IntraPet Ultrasound: No previous.  
Sedation: Not required to complete full diagnostic ultrasound.  
Stat Report: Not requested.**SPECIES ULTRASONOGRAPHIC EXAMINATION OF THE ABDOMEN**

Canine

**Urinary System****BREED**

The urinary bladder is minimally distended with anechoic urine. The Bladder wall, trigone, ureteral papillae and visible urethra (to a depth of 2cm) appear normal with no evidence of wall thickening, mucosal irregularities, masses or cystic calculi.

Labrador Retriever

**SEX**

The left kidney has a normal shape and size (6.72 cm) with mild pyelectasia at 0.21 cm. Overall echogenicity is slightly hyperechoic with poor corticomedullary distinction and a typical 1:3 cortex:medulla ratio. There is no evidence of perinephric inflammation or effusion. There is no evidence of nephroliths, infarcts or hydronephrosis. Renal vasculature is normal.

Spayed Female

**AGE**

The right kidney has a normal shape and size (7.62 cm) with pyelectasia at 0.18 cm. Overall echogenicity is slightly hyperechoic with poor corticomedullary distinction and a typical 1:3 cortex:medulla ratio. There is no evidence of perinephric inflammation or effusion. There is no evidence of nephroliths, infarcts or hydronephrosis. Renal vasculature is normal.

7/8/11

**WEIGHT**

64.2 Pounds

**Adrenal Glands****INTERPRETED BY**

The left adrenal gland is large in size measuring 2.28 cm at the cranial pole, 1.59 cm at the caudal pole, and 4.4 cm in length. It is observed in its normal position cranial to the left renal artery. It is somewhat abnormal in appearance in that it is enlarged and heterogeneous. There is no obvious evidence of vascular invasion.

Kathleen Sennello DVM,  
MS, Diplomate ACVIM  
(Small Animal Internal  
Medicine)

The region of the right adrenal (between right cranial kidney and vena cava) is unremarkable, but the adrenal is not distinctly visualized. No evidence of a mass effect.

**IMAGING PERFORMED BY****Spleen**

The spleen is not observed (previous splenectomy).

Rachel Brilhart RDMS

**Liver****HOSPITAL NAME**

The liver is subjectively normal in size, and echogenicity with smooth peripheral margins. The parenchyma is heterogeneous in echotexture with subtle, indistinct focal mottling. The visible portions of the vasculature and biliary tract appear normal. No focal nodules or cystic lesions are observed.

Animal Emergency  
Hospital**REFERRING VET**

The gall bladder lumen is moderately distended. The wall of the gall bladder is not thickened and has a smooth mucosal surface. There is a moderate amount of non-organized echogenic debris. The cystic and common bile ducts are normal/not visible.

Dr. Thompson

**Gastrointestinal****INVOICE**

The stomach contains a large amount of fluid. It measures at a normal thickness of &lt;0.7cm with some variability due to the presence of rugal folds. The distinction of the gastric wall layers is adequate and there is no impression of reduced peristaltic activity. While no focal gastric lesions are visualized, there is the likelihood of a mass effect visualized at the proximal duodenum/gastroduodenal junction.

39351

The visualized areas of duodenum, jejunum and ileum have a uniform diameter with minimal fluid distension. Wall thickness is increased. Bowel loops follow a typical curvilinear path. Some areas have reduced detail of wall layering. Jejunum wall measured 0.36 cm. Visualized peristalsis appears appropriate. There are some focal areas of small intestine that appear to have thickening and reduced detail of layering. There is a more focal discrete mass effect visualized in the proximal duodenum with a wall thickness of 1.37 cm, a diameter of 3.44 cm, and complete loss of layering. It is suspected that this mass effect is causing a pyloric outflow tract obstruction.

The ileocecal junction was visualized and exhibited normal intact wall layering and is subjectively of normal thickness. Sections of colon are visualized with formed fecal material and gas shadowing distally. There is no observed focal or generalized colon wall thickening or loss of layering.

### ***Pancreas***

The pancreas is large and hypoechoic to surrounding mesentery. There is a large mixed echogenic heterogeneous and mineralized mass effect arising from the area of the spleen, measuring approximately 5.57 cm x 5.11 cm. This is most consistent with a pancreatic mass lesion +/- concurrent abscessation/cystic regions. There is evidence of regional mesenteric inflammation. Consistent with severe pancreatitis and a mass lesion.

### ***Free Abdomen***

There is a moderate amount of free abdominal fluid. No significant lymphadenopathy is noted. The omentum is of increased echogenicity around the duodenal and pancreatic mass.

## **PRIMARY FINDINGS**

- Large left adrenal gland – Left adrenomegaly could be consistent with neoplasia (e.g., adenoma, carcinoma, pheochromocytoma), hyperplasia, inflammation, other.
- Mineralized, irregular, mixed echogenic mass in the pancreatic region – most consistent with pancreatic mass +/- concurrent abscessation/cystic areas.
- Severely fluid dilated stomach with a proximal area of small intestine with complete loss of layering and increased wall thickness – most consistent with a proximal duodenal mass and a gastric outflow tract obstruction. Likely differentials would include round cell neoplasia, carcinoma, adenoma, other.
- Diffuse small bowel thickening – The bowel wall thickening could be consistent with inflammation, edema, or infiltrative neoplasia.
- Small amount of free abdominal fluid.

## **SECONDARY FINDINGS**

- Decreased corticomedullary distinction in both kidneys with mild pyelectasia – The bilateral renal findings are consistent with age-related change.
- Surgically absent spleen
- Heterogeneous liver – The hepatic changes are consistent with age-related parenchymal remodeling and are not considered clinically significant at this time.
- Moderate gallbladder debris – The significance of the aggregated gallbladder sludge is unclear. This could represent an early mucocele, cholestasis, or may be secondary to fasting.

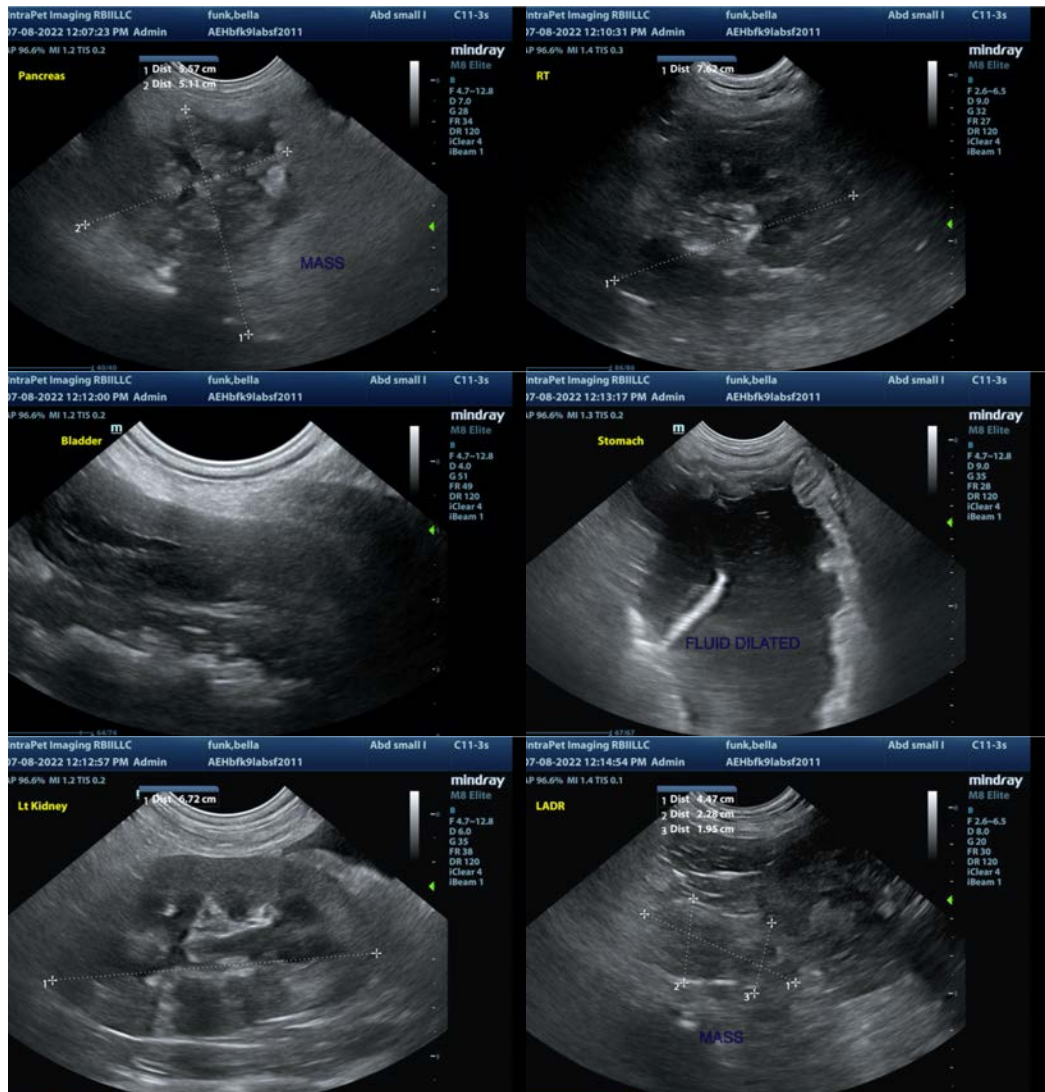
## INTERPRETATION OF THE FINDINGS & FURTHER RECOMMENDATIONS

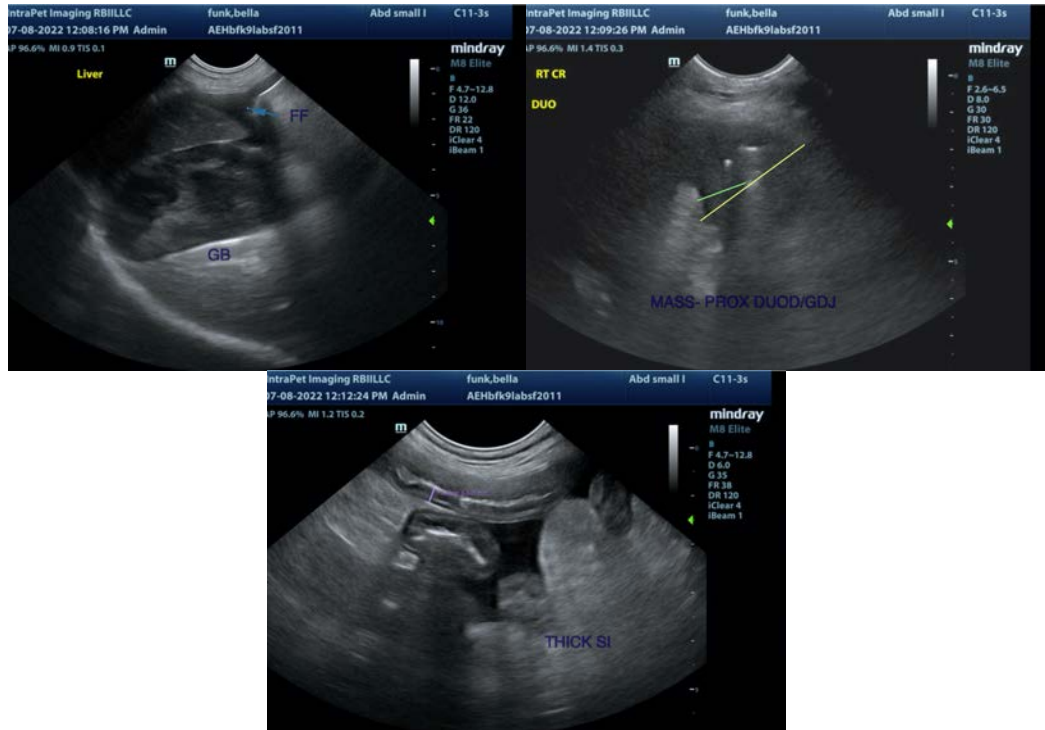
There is a mineralized mass effect in the region of the pancreas in addition to a proximal duodenal mass causing a gastric outflow tract obstruction, and diffusely abnormal small intestine. These findings are concerning for possible carcinoma, round cell neoplasia, etc.

Additionally, there is an enlarged left adrenal gland. This could be consistent with a benign or neoplastic lesion.

The concern for an underlying neoplastic process is very high in this individual. Next potential steps for diagnosis and treatment would likely include cytologic evaluation of the abnormal areas and consultation with a veterinary oncologist, as there is concern for diffuse possible metastatic disease.

Consider three view thoracic radiographs to rule out concurrent thoracic disease/involvement.





The information and recommendations provided are based on the images presented by the referring veterinarian/sonographer. No evaluation can be communicated regarding pathology that was not visible in the image/video clips provided.

Thank you for this referral. If the clinical or image interpretation does not parallel your findings or if I can be of any further assistance please contact me.

Kathleen Sennello DVM,MS, Diplomate ACVIM (Small animal Internal Medicine)  
kathleen.sennello@sonopath.com