

**DATE PRESENTING CLINICAL SIGNS**

7/7/23

PATIENT

Taz Vinson

History: Presented on 07/06 for past 2 weeks - P having diarrhea, not E/D for the past week & half. Vomiting EOD past week, lethargic. Urinating outside the litterbox. 2lbs weight loss since April. No known dietary indiscretion or FB ingestion. PE: BCS 3/9, mm: pink and tacky 7% dehydration, increased skin turgor, abd- potbelly appearance painful on palpation.

SPECIES

Feline

Current Medications: 7/6 cerenia 2.4mg IV, buprenorphine 0.04mg SC, metronidazole, elura 5mg PO

Lab Results: CBC- neutrophils (H) 11.42. CHEM 17- Alb (L) 1.8, glob wnl 5, snap fpl wnl

Date of Previous IntraPet Ultrasound: No previous.

Sedation: Not required to complete full diagnostic ultrasound.

BREED

DSH

Stat Report: Requested by DVM.

Imaging Performed By: Andi Parkinson, RDMS

SEX

Neutered Male

ULTRASONOGRAPHIC EXAMINATION OF THE ABDOMEN**Urinary System**

The urinary bladder is moderately distended with anechoic urine. The bladder wall, trigone, ureteral papillae and visible urethra (to a depth of 2.0 cm) appear normal with no evidence of wall thickening, mucosal irregularities, masses or cystic calculi.

AGE

8/5/22

WEIGHT

5.4 Pounds

The left kidney has a normal shape and size (3.77 cm) with prominent corticomedullary rim sign. Overall echogenicity is normal with adequate corticomedullary distinction and a typical 1:3 cortex:medulla ratio. There is no evidence of perinephric inflammation or effusion. There is no evidence of pyelectasia, nephroliths, infarcts or hydroureter. Renal vasculature is normal.

INTERPRETED BY

The right kidney has a normal shape and size (3.89 cm) with prominent corticomedullary rim sign. Overall echogenicity is normal with adequate corticomedullary distinction and a typical 1:3 cortex:medulla ratio. There is no evidence of perinephric inflammation or effusion. There is no evidence of pyelectasia, nephroliths, infarcts or hydroureter. Renal vasculature is normal.

Adrenal Glands

The left adrenal gland is normal in size measuring 0.28 cm at the caudal pole. It is observed in its normal position cranial to the left renal artery. It is normal in appearance (uniformly hypoechoic) and shape with no evidence of a mass effect.

HOSPITAL NAME

Perry Hall AH

The right adrenal gland is normal in size measuring 0.5 cm at the caudal pole. It is observed in its normal position between the cranial aspect of the right kidney and the caudal vena cava. It is normal in appearance (uniformly hypoechoic) and shape with no evidence of a mass effect.

REFERRING VET

Dr. Baer

Spleen**INVOICE**

23180

The spleen is borderline plump (measuring 1.3 cm), echotexture is homogenous, and the splenic capsule is smooth with no irregularities. The blood flow through the hilus and splenic parenchyma appears normal. No focal parenchymal abnormalities are visualized.

Liver

The liver is subjectively normal in size, and echogenicity with smooth peripheral margins. The parenchyma is homogenous echotexture. The visible portions of the vasculature and biliary tract appear normal. No focal nodules or cystic lesions are observed.

The gall bladder lumen is moderately distended. The wall of the gall bladder is not thickened and has a smooth mucosal surface. Luminal contents are primarily anechoic. The cystic and common bile ducts are normal/not visible.

Gastrointestinal

The stomach contains minimal luminal contents. It measures at a normal thickness of <0.36 cm with some variability due to the presence of rugal folds. The distinction of the gastric wall layers is adequate and there is no impression of reduced peristaltic activity. No masses or focal lesions were observed.

The visualized areas of duodenum, jejunum and ileum have a uniform diameter with minimal fluid distension. The duodenum measured 0.65 cm in wall thickness, and the jejunum measured 0.32 cm. Bowel loops follow a typical curvilinear path. Some areas have reduced detail of wall layering. Visualized peristalsis appears appropriate. There were no focal lesions consistent with obstruction or a mass effect observed.

The ileocecal junction was visualized and exhibited normal intact wall layering and is subjectively of normal thickness. Sections of colon are visualized with formed fecal material and gas shadowing distally. There is no observed focal or generalized colon wall thickening or loss of layering.

Pancreas

The pancreas is normal and isoechoic to surrounding mesentery. There is no evidence of nodules or cystic lesions. There is no evidence of regional mesenteric inflammation or fluid.

Free Abdomen

There is a large amount of anechoic free fluid and no significant lymphadenopathy. The omentum is diffusely hyperechoic.

ULTRASONOGRAPHIC FINDINGS

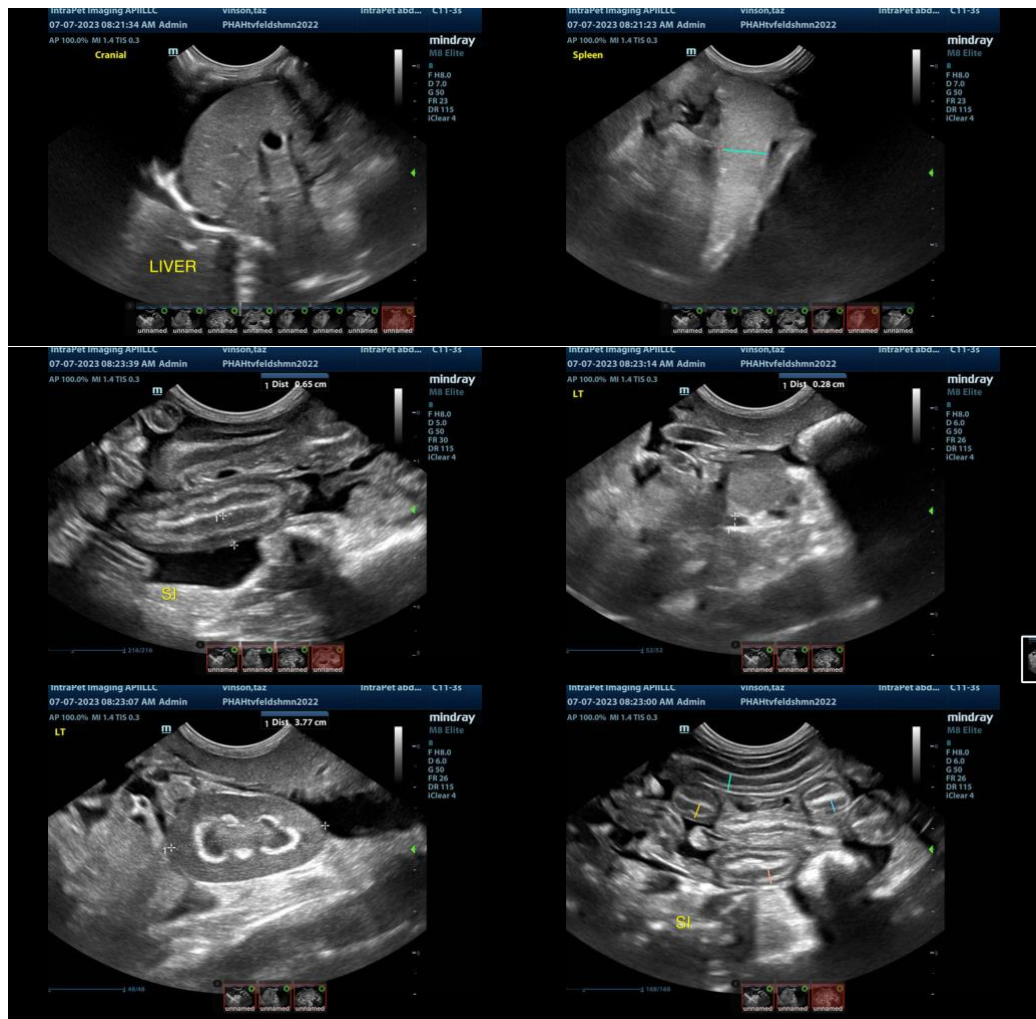
- Prominent corticomedullary rim sign visualized, associated with both kidneys. Clinical significance uncertain, can be seen in normal patients and in cases of ethylene glycol toxicity, FIP, chronic interstitial nephritis, and leptospirosis.
- Borderline large spleen. Differentials could include congestion, anatomic variation, infiltrative disease, etc.
- Moderate small intestinal thickening. The bowel wall thickening could be consistent with inflammation, edema, or infiltrative neoplasia.
- Large/moderate volume anechoic abdominal fluid. Recommend fluid analysis and cytology.

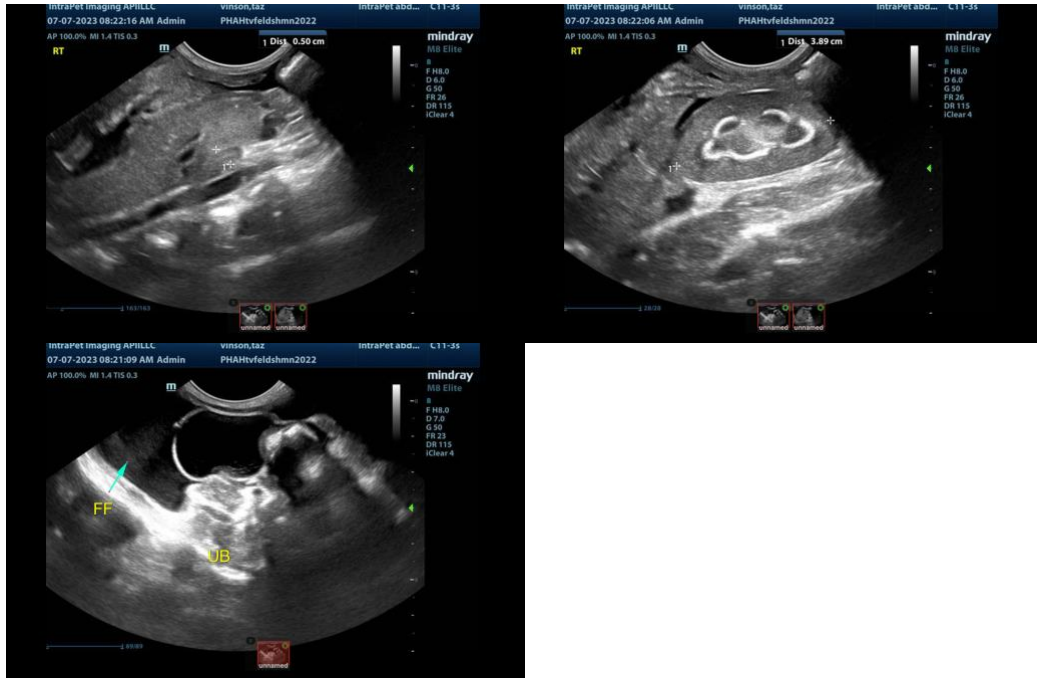
INTERPRETATION OF THE FINDINGS & FURTHER RECOMMENDATIONS

No large focal mass lesions are visualized on today's exam, and no focal lesions are visualized associated

with organ structures. Based on the low albumin levels reported, this is likely associated with the fluid present. Recommend fluid sampling for fluid analysis and cytology (I believe this is already pending). Additionally, consider a liver function test (pre-and post-prandial bile acids) and a urine protein to creatinine ratio, as well as a urinalysis, looking for evidence of underlying liver or renal disease contributing to the hypoalbuminemia. If these levels are normal, I would be concerned about possible GI protein loss due to a protein losing enteropathy (primary differentials would be IBD, lymphangiectasia, neoplasia, etc.). This would be unusual in such a young cat.

Additionally, I would recommend three view thoracic radiographs and cardiac ultrasound if there is any clinical suspicion of underlying cardiac disease.





The information and recommendations provided are based on the images presented by the referring veterinarian. No evaluation can be communicated regarding pathology that was not visible in the image/video clips provided.

Thank you for this referral. If the clinical or image interpretation does not parallel your findings or if I can be of any further assistance please contact me.

Kathleen Sennello DVM,MS, Diplomate ACVIM (Small animal Internal Medicine)
info@sonopath.com