

**DATE PRESENTING CLINICAL SIGNS**

7/6/23

Was seen on 6/27 for decreased appetite. Had been going on for 2-3 weeks prior. Lab work noted high calcium, radiographs had no significant findings. Despite mirtazapine pet is still not eating well. Repeat labs today (7/5) still showed significant elevation in calcium.

**PATIENT**

Gunnar Friedel

Current Medications: Mirtazapine 15mg

Lab Results: Calcium > 16.

Date of Previous IntraPet Ultrasound: No previous.

**SPECIES**

Canine

Sedation: IV: Dexdomitor.

Stat Report: Not requested.

Imaging Performed By: Rachel Brillhart, RDMS.

**BREED**

Pit bull X

**ULTRASONOGRAPHIC EXAMINATION OF THE ABDOMEN****SEX**

Neutered Male

**Urinary System**

The urinary bladder is moderately distended with anechoic urine. The Bladder wall, trigone, ureteral papillae and visible urethra (to a depth of 2cm) appear normal with no evidence of wall thickening, mucosal irregularities, or masses. There is a small amount of dependent shadowing debris in the urinary bladder, most consistent with a small amount of sandy debris.

**AGE**

11/2/18

The visualized areas of prostate and surrounding tissue appear normal. Unfortunately, the prostate is not fully visualized likely due to its intrapelvic location. Correlate with rectal exam findings.

**WEIGHT**

75.2 Pounds

The left kidney has a normal shape and size (7.96 cm). Overall echogenicity is normal with adequate corticomedullary distinction and a typical 1:3 cortex:medulla ratio. There is no evidence of focal perinephric inflammation or effusion. There is no evidence of pyelectasia, nephroliths, infarcts or hydroureter. Renal vasculature is normal.

**INTERPRETED BY**

Kathleen Sennello DVM,  
MS, Diplomate ACVIM  
(Small Animal Internal  
Medicine)

The right kidney has a normal shape and size (7.21 cm). Overall echogenicity is normal with adequate corticomedullary distinction and a typical 1:3 cortex:medulla ratio. There is no evidence of focal perinephric inflammation or effusion. There is no evidence of pyelectasia, nephroliths, infarcts or hydroureter. Renal vasculature is normal.

**HOSPITAL NAME**

Animal Care Center

**Adrenal Glands**

The left adrenal gland is normal in size measuring 0.67 cm at the caudal pole. It is observed in its normal position cranial to the left renal artery. It is normal in appearance (uniformly hypoechoic) and shape with no evidence of a mass effect.

**REFERRING VET**

Dr. Beavers

The right adrenal gland is normal in size measuring 0.54 cm at the caudal pole. It is observed in its normal position between the cranial aspect of the right kidney and the caudal vena cava. It is normal in appearance (uniformly hypoechoic) and shape with no evidence of a mass effect.

**INVOICE**

43833

**Spleen**

The spleen is subjectively normal in size, echotexture is homogenous, and the splenic capsule is smooth with no irregularities. The blood flow through the hilus and splenic parenchyma appears normal. No focal parenchymal abnormalities are visualized.

### **Liver**

The liver is subjectively normal in size, and hypoechoic with smooth peripheral margins. The parenchyma is heterogenous in echotexture with subtle, indistinct focal mottling. The visible portions of the vasculature and biliary tract appear normal. No focal nodules or cystic lesions are observed.

The gall bladder lumen is moderately distended. The wall of the gall bladder is not thickened and has a smooth mucosal surface. There is a moderate amount of non-organized echogenic debris. The cystic and common bile ducts are normal/not visible.

### **Gastrointestinal**

The stomach contains minimal luminal contents. It measures at a normal thickness of <0.7cm with some variability due to the presence of rugal folds. The distinction of the gastric wall layers is adequate and there is no impression of reduced peristaltic activity. No masses or focal lesions were observed.

The visualized areas of duodenum, jejunum and ileum have a relatively uniform diameter with minimal fluid distension. Wall thickness is normal. Bowel loops follow a curvilinear path with distinct wall layering maintaining the typical 1:3 muscularis:mucosa layer ratio. The duodenum measured as normal (between 0.3-0.5cm in wall thickness) and the jejunum measured as normal (between 0.2-0.47cm.) Visualized peristalsis appears appropriate. There were no focal lesions consistent with obstruction or a mass effect observed.

The ileocecal junction was visualized and exhibited normal intact wall layering and is subjectively of normal thickness. Sections of colon are visualized with formed fecal material and gas shadowing distally. There is no observed focal or generalized colon wall thickening or loss of layering.

### **Pancreas**

The pancreas is normal and isoechoic to surrounding mesentery. There is no evidence of nodules or cystic lesions. There is no evidence of regional mesenteric inflammation or fluid.

### **Free Abdomen**

Evaluation of the peritoneal cavity did not reveal any evidence of effusion. There is a significant mesenteric lymphadenopathy present with large hypoechoic lymph nodes at the mesenteric root measuring 1.3 cm and 1.25 cm in diameter. There is a sublumbar lymph node measuring 1.83 cm x 4.05 cm. A gastric lymph node is noted measuring 2.63 cm x 2.19 cm. Additionally, in the portal region there is a large, irregularly shaped lymph node measuring 4.7 cm x 2.08 cm. The omentum is hyperechoic around the enlarged lymph nodes.

### **PRIMARY FINDINGS**

- Heterogeneous, hypoechoic liver – The diffuse hepatic changes are non-specific and could be consistent with vacuolar hepatopathy, nodular hyperplasia, inflammatory/immune-mediated disease, fibrosis, extramedullary hematopoiesis, toxic hepatopathy (e.g., copper), infiltrative neoplasia (less likely) or other hepatopathy.
- Moderate to severe mesenteric lymphadenopathy – The moderate mesenteric lymphadenopathy could be concerning for a neoplastic process, although you can see significant lymphadenopathy in some cases of autoimmune/inflammatory disease, infectious disease (tick born disease-such as bartonella, fungal infections, FIP (cats)) etc. A fine needle aspirate with cytology is recommended for further evaluation.

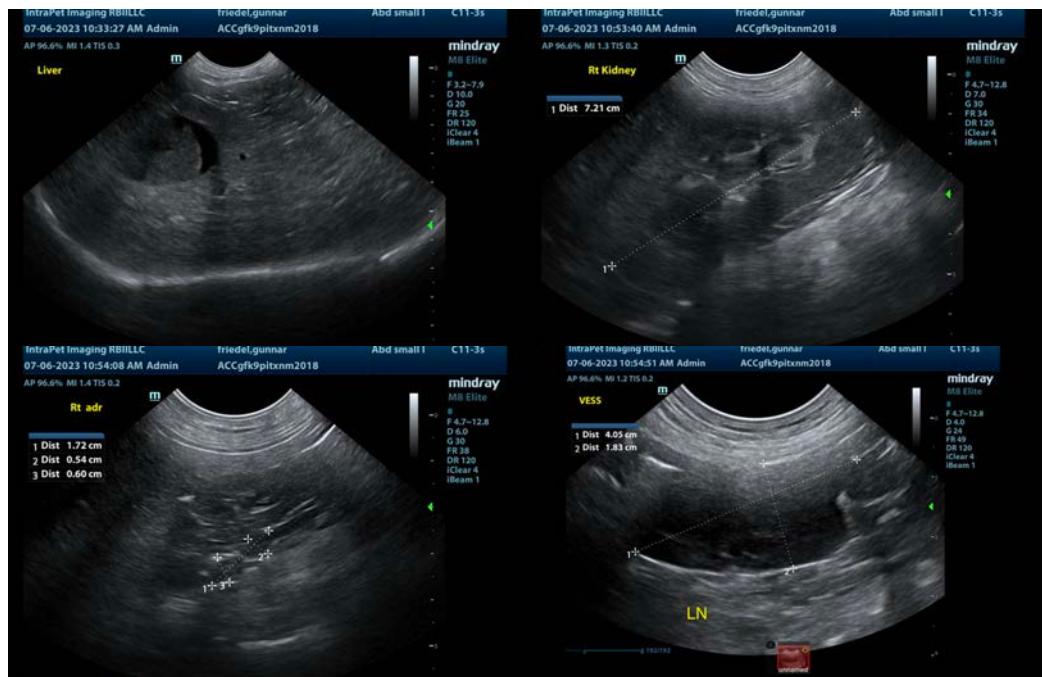
## SECONDARY FINDINGS

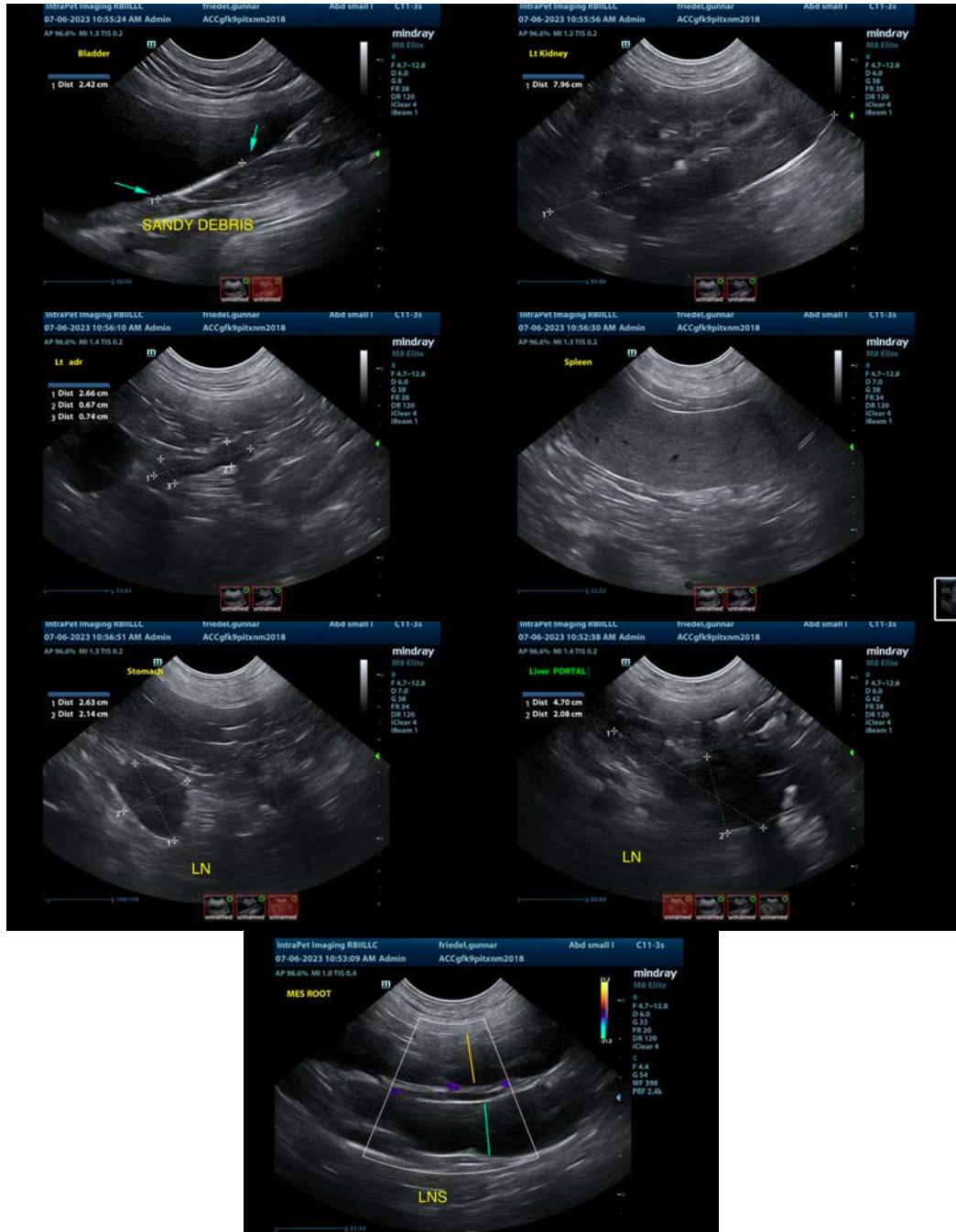
- Small amount of sandy debris in the dependent portion of the urinary bladder – Recommend urinalysis and culture.
- Moderate gallbladder debris – The significance of the aggregated gallbladder debris is unclear. This could represent an early mucocele, cholestasis, or may be secondary to fasting but seems unlikely to be causing a current issue. Recommend continued monitoring.

## INTERPRETATION OF THE FINDINGS & FURTHER RECOMMENDATIONS

There is a significant lymphadenopathy on today's exam. Based on the hypercalcemia reported there would be concern for a possible paraneoplastic syndrome. Recommend a fine needle aspirate of a mesenteric lymph node. Additionally, recommend a hypercalcemia of malignancy panel to obtain an ionized calcium, PTH, and PTHrP level. If a diagnosis cannot be obtained based on a mesenteric lymph node aspirate (or peripheral lymph node aspirate), then consider a fine needle aspirate of the liver, as infiltrative neoplasia would be a differential (round cell neoplasia).

Recommend three view thoracic radiographs to evaluate for possible concurrent thoracic disease/involvement.





The information and recommendations provided are based on the images presented by the referring veterinarian/sonographer. No evaluation can be communicated regarding pathology that was not visible in the image/video clips provided.

Thank you for this referral. If the clinical or image interpretation does not parallel your findings or if I can be of any further assistance please contact me.

Kathleen Sennello DVM,MS, Diplomate ACVIM (Small animal Internal Medicine)  
 info@sonopath.com