

**PATIENT PRESENTING CLINICAL SIGNS**

Fenway Silvia Coughs when anxious; otherwise, doing well. Grade I/VI systolic murmur. ProBNP 1435. ALP 1292. BP: 160-170 mmHg. Having bi-cavity exams.

**SPECIES ULTRASONOGRAPHIC EXAMINATION OF THE ABDOMEN**

Canine

**Urinary System**

**BREED**

Pomeranian

The urinary bladder is moderately distended with anechoic urine. The Bladder wall, trigone, ureteral papillae and visible urethra (to a depth of 2cm) appear normal with no evidence of wall thickening, mucosal irregularities, or masses. There is dependent shadowing hyperechoic debris visualized in the trigone extending into the proximal urethra, most consistent with sandy debris/small stones.

**SEX**

Neutered Male

The prostate is normal in size (0.84 cm) and shape for this neutered male dog. The parenchyma is homogenous and the external margins are smooth. The prostatic urethra appears normal with no evidence of irregularity, invasion, mass effect or calculi.

**AGE**

11 Years

The left kidney has a normal shape and size (4.68 cm) with a very small cortical cyst measuring 0.24 cm and small non-obstructive cortical mineralizations. Overall echogenicity is normal with adequate corticomedullary distinction and a typical 1:3 cortex:medulla ratio. There is no evidence of focal perinephric inflammation or effusion. There is no evidence of pyelectasia, infarcts or hydroureter. Renal vasculature is normal.

**WEIGHT**

12.96 Pounds

The right kidney has a normal shape and size (4.38 cm) with small non-obstructive cortical mineralizations. Overall echogenicity is normal with adequate corticomedullary distinction and a typical 1:3 cortex:medulla ratio. There is no evidence of focal perinephric inflammation or effusion. There is no evidence of pyelectasia, infarcts or hydroureter. Renal vasculature is normal.

**INTERPRETED BY**

Kathleen Sennello DVM,  
MS, Diplomate ACVIM  
(Small Animal Internal  
Medicine)

**Adrenal Glands**

The left adrenal gland is normal/borderline "plump" at 0.63 cm. It is observed in its normal position cranial to the left renal artery. It is normal in appearance (uniformly hypoechoic) and shape with no evidence of a mass effect.

**IMAGING PERFORMED BY**

Pamela Harrigan, RDCS

The right adrenal gland is normal/borderline "plump" at 0.54 cm. It is observed in its normal position between the cranial aspect of the right kidney and the caudal vena cava. It is normal in appearance (uniformly hypoechoic) and shape with no evidence of a mass effect.

**HOSPITAL NAME**

Anchor AH

**Spleen**

The spleen is subjectively normal in size, echotexture is homogenous, and the splenic capsule is smooth with no irregularities. The blood flow through the hilus and splenic parenchyma appears normal. There is a very small ill-defined hypoechoic nodule visualized in the caudal aspect of the spleen measuring 0.33 cm.

**REFERRING VET**

Dr. Nicole Mulready

**Liver**

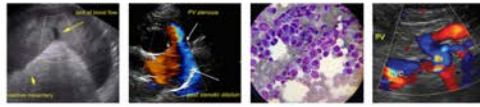
**INVOICE**

43820

The liver is large in size, and normal in echogenicity with smooth peripheral margins. The parenchyma is heterogenous in echotexture with subtle, indistinct focal mottling. The visible portions of the vasculature and biliary tract appear normal. There is a multiloculated cystic lesion visualized measuring 1.4 cm x 1.32 cm.

**DATE**

7/6/23



**PATIENT**

Fenway Silvia

The gall bladder lumen is moderately distended. The wall of the gall bladder is not thickened and has a smooth mucosal surface. There is a moderate/large amount of non-organized echogenic debris. The cystic and common bile ducts are normal/not visible.

**SPECIES**

Canine

**Gastrointestinal**

The stomach contains mild fluid. It measures at a normal thickness of <0.7cm with some variability due to the presence of rugal folds. The distinction of the gastric wall layers is adequate and there is no impression of reduced peristaltic activity. No masses or focal lesions were observed.

**BREED**

Pomeranian

The visualized areas of duodenum, jejunum and ileum have a relatively uniform diameter with minimal fluid distension. Wall thickness is normal. Bowel loops follow a curvilinear path with distinct wall layering maintaining the typical 1:3 muscularis:mucosa layer ratio. Duodenum wall measures 0.34 cm. Jejunum wall measures 0.30 cm. Visualized peristalsis appears appropriate. There were no focal lesions consistent with obstruction or a mass effect observed.

**SEX**

Neutered Male

The ileocecal junction was visualized and exhibited normal intact wall layering and is subjectively of normal thickness. Sections of colon are visualized with formed fecal material and gas shadowing distally. There is no observed focal or generalized colon wall thickening or loss of layering.

**AGE**

11 Years

**Pancreas**

The pancreas is normal and isoechoic to surrounding mesentery. There is no evidence of nodules or cystic lesions. There is no evidence of regional mesenteric inflammation or fluid.

**WEIGHT**

12.96 Pounds

**Free Abdomen**

Evaluation of the peritoneal cavity did not reveal any evidence of effusion, or subjective lymphadenomegaly. The Medial iliac nodes appear normal and there was no evidence of a caudal aortic thrombus at the bifurcation. The omentum is of normal uniform echogenicity.

**INTERPRETED BY**

Kathleen Sennello DVM,  
MS, Diplomate ACVIM  
(Small Animal Internal  
Medicine)

**ULTRASONOGRAPHIC FINDINGS**

- Hyperechoic shadowing debris visualized in the trigone and proximal urethra – Findings are most consistent with sandy debris and small stones. Correlate with abdominal radiographs, urinalysis and culture.
- Borderline “plump” adrenal glands – Both adrenals are normal in size but are hypoechoic and somewhat prominent. Continued monitoring is warranted.
- Small, hypoechoic nodule visualized in the caudal third of the spleen – There is a non-cavitated, hypoechoic splenic nodule visualized. Differentials include lymphoid hyperplasia, extramedullary hematopoiesis, infiltrative neoplasia, inflammation, other. Cytology or histopathology would be necessary to get a definitive diagnosis.
- Large, hyperechoic, heterogeneous liver with a cystic lesion – The diffuse hepatic changes are non-specific and could be consistent with vacuolar hepatopathy, nodular hyperplasia, inflammatory/immune-mediated disease, fibrosis, extramedullary hematopoiesis, toxic hepatopathy (e.g., copper), infiltrative neoplasia (less likely) or other hepatopathy. The multiloculated cystic lesion is most consistent with a cystadenoma. Recommend continued monitoring.
- Moderate/large gallbladder debris – The significance of the aggregated gallbladder debris is unclear. This could represent an early mucocele, cholestasis, or may be secondary to fasting but seems unlikely to be causing a current issue. Recommend continued monitoring.

**IMAGING PERFORMED BY**

Pamela Harrigan, RDCS

**HOSPITAL NAME**

Anchor AH

**REFERRING VET**

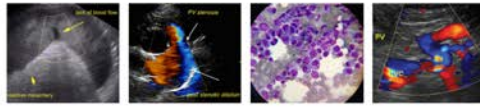
Dr. Nicole Mulready

**INVOICE**

43820

**DATE**

7/6/23



**PATIENT**

Fenway Silvia

**SPECIES**

Canine

**BREED**

Pomeranian

**SEX**

Neutered Male

**AGE**

11 Years

**WEIGHT**

12.96 Pounds

**INTERPRETED BY**

Kathleen Sennello DVM,  
 MS, Diplomate ACVIM  
 (Small Animal Internal  
 Medicine)

**IMAGING  
 PERFORMED BY**

Pamela Harrigan, RDCS

**HOSPITAL NAME**

Anchor AH

**REFERRING VET**

Dr. Nicole Mulready

**INVOICE**

43820

**DATE**

7/6/23

**INTERPRETATION OF THE FINDINGS & FURTHER RECOMMENDATIONS**

The liver is large and heterogeneous. These changes are most consistent with a vacuolar hepatopathy and early Cushing's disease, but other differentials are possible. Consider the following evaluation for a primary ALP elevation:

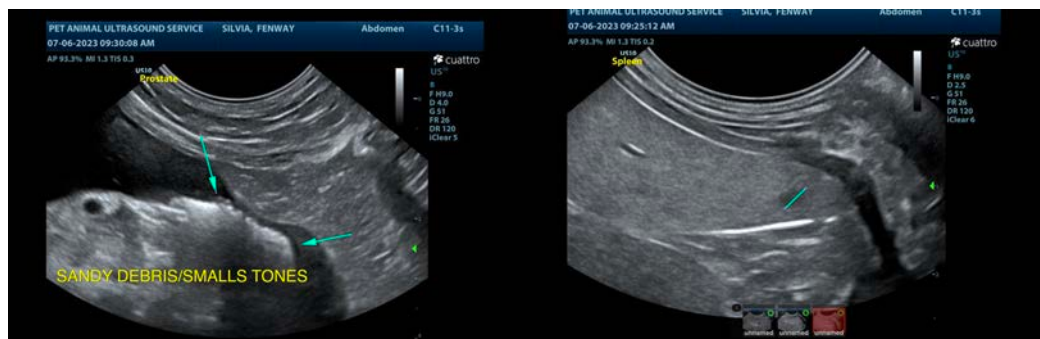- Induction phenomena are the most common cause for an elevation in ALP. These are systemic illnesses that 'turn on' the liver enzyme. Causes of this include Cushing's disease, dental disease, arthritis, and numerous others. In many cases the exact cause is unclear but as long as ultrasound and bile acids tests are normal most patients do not have progressive changes in their liver. While liver biopsy is not routinely performed, vacuolar hepatopathy, is noted on most biopsies. This is often non-progressive but in rare cases can be more severe and lead to liver failure.
- If signs of cushings disease are present recommend endocrine function testing to evaluate for cushings disease.
- Consider fine needle aspirate to rule out round cell neoplasia -if this is a concern.
- If a cause for the ALP elevation is not identified: I recommend recheck general blood work every 6 months, ultrasound once per year, and bile acids test every 1-2 years based on other results. If the ALP continues to climb a biopsy could be considered.
- Consider long term use of denamarin, and monitoring for the signs of cushings developing.
- A primary vacuolar hepatopathy can be breed related and is seen in Scottish Terriers, Schnauzers, Cocker spaniels etc..

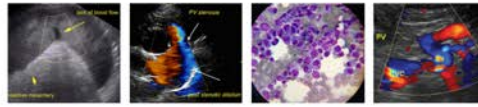
There is a moderate to large amount of debris visualized within the gallbladder lumen. Options moving forward would include continued monitoring of the gallbladder for progression or starting Ursodiol therapy and continued monitoring of liver values and the ultrasonographic appearance of the gallbladder.

There is sandy debris/small stones visualized in the urinary bladder and proximal urethra. Correlate these findings with a urinalysis, culture, and radiographs. Continued monitoring may be reasonable provided no infection is present.

There is a very small hypoechoic lesion visualized associated with the spleen. I suspect this is too small to easily sample. Consider continued monitoring with ultrasound (recheck in 3-4 months).

Recommend three view thoracic radiographs to evaluate for possible concurrent thoracic disease/involvement.





**PATIENT**

Fenway Silvia

**SPECIES**

Canine

**BREED**

Pomeranian

**SEX**

Neutered Male

**AGE**

11 Years

**WEIGHT**

12.96 Pounds

**INTERPRETED BY**

Kathleen Sennello DVM, MS, Diplomate ACVIM (Small Animal Internal Medicine)

**IMAGING PERFORMED BY**

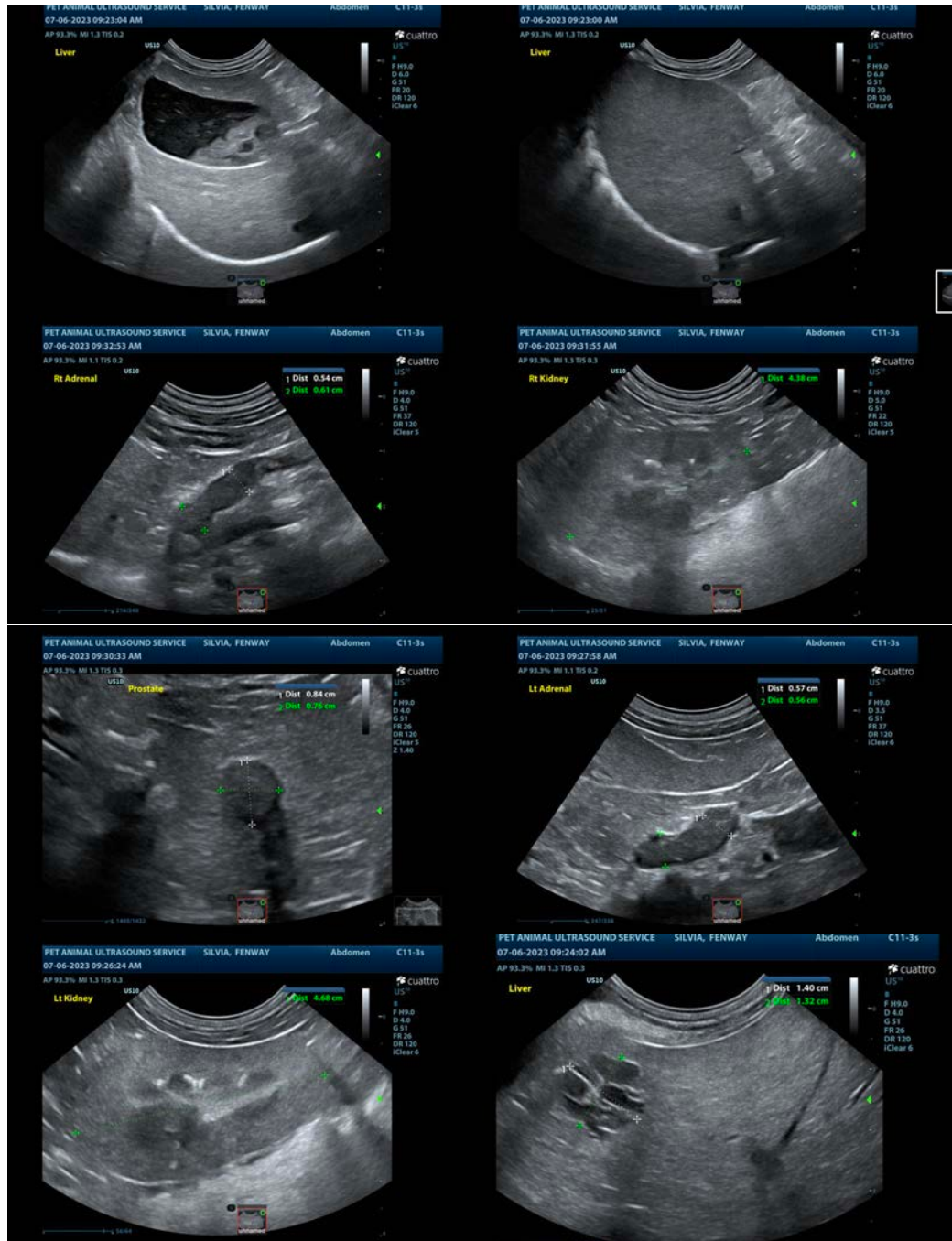
Pamela Harrigan, RDCS

**HOSPITAL NAME**

Anchor AH

**REFERRING VET**

Dr. Nicole Mulready



**INVOICE**

43820

**DATE**

7/6/23

The information and recommendations provided are based on the images presented by the referring veterinarian/sonographer. No evaluation can be communicated regarding pathology that was not visible in the image/video clips provided.

Thank you for this referral. If the clinical or image interpretation does not parallel your findings or if I can be of any further assistance please contact me.

Kathleen Sennello DVM,MS, Diplomate ACVIM (Small animal Internal Medicine)

info@sonopath.com