



PATIENT

Apollo Cordisco

PRESENTING CLINICAL SIGNS

SPECIES

Canine

BREED

Golden Retriever

SEX

Neutered Male

Current Problem List: Hyperbilirubinemia Mild anemia Hyporexia - resolved Lethargy - improving Diarrhea - new DDx: IMHA (1' vs 2'), pancreatitis, GI hemorrhage, other Presenting Complaint: Patient initially presented on Friday 7/1/22 for several weeks history of lethargy and intermittent hyporexia and intermittent soft stools. Px appeared to possibly have slightly icteric sclera. Labs showed hyperbilirubinemia and slight anemia (34%). 3 view chest rads obtained and unremarkable. Px started on Prednisone, Cerenia, SQF, Entyce PRN. Patient presented today Tuesday 7/5/22 for recheck. Hyporexia resolved, lethargy improved significantly. Started with diarrhea this morning. Recheck CBC and HCT is slightly lower at 32%.
Abnormal PE/Chem/CBC/UA Results: Pertinent Diagnostic Results: 7/5/22 WBC 25.48 NEU 22.44 HCT 33.79% RBC 4.75(L) HGB 8.7 (L) MCH 18.4 (L) MCHC 25.8(L) PLT 299 MPV 16.3 (H) GLU 144, remainder of chem unremarkable 7/1/22: WBC 20.6 PMNs 17 RBC 5.12 HGB 9.2 HCT 35.53% MCH 18.1 MCHC 26 PLTs 33 -- blood film revealed adequate, large PLTs TBIL 1 RADS: negative for gross evidence of pulmonary metastatic disease.

ULTRASONOGRAPHIC EXAMINATION OF THE ABDOMEN

AGE

6.9 Years

Urinary System

The urinary bladder is moderately distended with anechoic urine. The Bladder wall, trigone, ureteral papillae and visible urethra (to a depth of 2cm) appear normal with no evidence of wall thickening, mucosal irregularities, masses or cystic calculi.

WEIGHT

95.2 Pounds

The prostate is normal in size (1.03 cm) and shape for this neutered male dog. The parenchyma is homogenous and the external margins are smooth. The prostatic urethra appears normal with no evidence of irregularity, invasion, mass effect or calculi.

INTERPRETED BY

Kathleen Sennello DVM,
MS, Diplomate ACVIM
(Small Animal Internal
Medicine)

The left kidney has a normal shape and size (8.04 cm). Overall echogenicity is normal with adequate corticomedullary distinction and a typical 1:3 cortex:medulla ratio. There is no evidence of perinephric inflammation or effusion. There is no evidence of pyelectasia, nephroliths, infarcts or hydroureter. Renal vasculature is normal.

IMAGING BY

Loetitia Saint-Jacques,
LVT

The right kidney has a normal shape and size (7.71 cm). Overall echogenicity is normal with adequate corticomedullary distinction and a typical 1:3 cortex:medulla ratio. There is no evidence of perinephric inflammation or effusion. There is no evidence of pyelectasia, nephroliths, infarcts or hydroureter. Renal vasculature is normal.

HOSPITAL NAME

Truckee Meadows VH

Adrenal Glands

The left adrenal gland is normal in size measuring 0.50 cm at the caudal pole. It is observed in its normal position cranial to the left renal artery. It is normal in appearance (uniformly hypoechoic) and shape with no evidence of a mass effect.

REFERRING VET

Dr. Rachel Kuester

The right adrenal gland is normal in size measuring 0.49 cm at the caudal pole. It is observed in its normal position between the cranial aspect of the right kidney and the caudal vena cava. It is normal in appearance (uniformly hypoechoic) and shape with no evidence of a mass effect.

INVOICE

39232

DATE

7/6/22



PATIENT

Apollo Cordisco

SPECIES

Canine

BREED

Golden Retriever

SEX

Neutered Male

AGE

6.9 Years

WEIGHT

95.2 Pounds

INTERPRETED BY

Kathleen Sennello DVM,
MS, Diplomate ACVIM
(Small Animal Internal
Medicine)

IMAGING BY

Loetitia Saint-Jacques,
LVT

HOSPITAL NAME

Truckee Meadows VH

REFERRING VET

Dr. Rachel Kuester

INVOICE

39232

DATE

7/6/22

Spleen

The spleen is subjectively normal in size, echotexture is homogenous, and the splenic capsule is smooth with no irregularities. The blood flow through the hilus and splenic parenchyma appears normal. There is a very small, hypoechoic lesion visualized within the parenchyma measuring 0.54 cm in diameter.

Liver

The liver is subjectively normal in size, and echogenicity with smooth peripheral margins. The parenchyma is heterogenous in echotexture with subtle, indistinct focal mottling. The visible portions of the vasculature and biliary tract appear normal. No focal nodules or cystic lesions are observed.

Gastrointestinal

The stomach contains minimal luminal contents. It measures at a normal thickness of <0.7cm with some variability due to the presence of rugal folds. The distinction of the gastric wall layers is adequate and there is no impression of reduced peristaltic activity. No masses or focal lesions were observed.

The visualized areas of duodenum, jejunum and ileum have a relatively uniform diameter with minimal fluid distension. Wall thickness is normal. Bowel loops follow a curvilinear path with distinct wall layering maintaining the typical 1:3 muscularis:mucosa layer ratio. The duodenum measured as normal (between 0.3-0.5cm in wall thickness) and the jejunum measured as normal (between 0.2-0.47cm.) Visualized peristalsis appears appropriate. There were no focal lesions consistent with obstruction or a mass effect observed.

The ileocecal junction is visualized and exhibits normal intact wall layering, and is subjectively of normal thickness. More distal sections of colon are visualized with non-formed fecal material and prominent wall measuring at 0.28 cm. There is no observed focal or generalized loss of layering noted.

Pancreas

The pancreas is normal and isoechoic to surrounding mesentery. There is no evidence of nodules or cystic lesions. There is no evidence of regional mesenteric inflammation or fluid.

Free Abdomen

Evaluation of the peritoneal cavity did not reveal any evidence of effusion, or subjective lymphadenomegaly. The Medial iliac nodes appear normal and there was no evidence of a caudal aortic thrombus at the bifurcation. The omentum is of normal uniform echogenicity.

Other

A brief view of the heart was submitted. No significant pericardial effusion was seen.

ULTRASONOGRAPHIC FINDINGS

- Small, hypoechoic lesion visualized within the spleen – There is a non-cavitated, hypoechoic splenic nodule visualized. Differentials include lymphoid hyperplasia,



PATIENT

Apollo Cordisco

extramedullary hematopoiesis, infiltrative neoplasia, inflammation, other. Cytology or histopathology would be necessary to get a definitive diagnosis.

SPECIES

Canine

- Mildly heterogeneous liver – The diffuse hepatic changes are non-specific and could be consistent with vacuolar hepatopathy, nodular hyperplasia, inflammatory/immune-mediated disease, fibrosis, extramedullary hematopoiesis, toxic hepatopathy (e.g., copper), infiltrative neoplasia (less likely) or other hepatopathy.

BREED

Golden Retriever

- Non-formed liquid stool visualized in the distal colon with mild colonic wall thickening – most consistent with colitis and diarrhea. Infiltrative disease cannot be ruled out.

SEX

Neutered Male

INTERPRETATION OF THE FINDINGS & FURTHER RECOMMENDATIONS

Today's scan is relatively normal. No large focal lesions are observed. There is a very small, hypoechoic nodule in the spleen. A fine needle aspirate of the spleen could be considered. Additionally, the liver is mildly heterogeneous, but the significance of this is unclear if liver enzyme values are normal. Based on this scenario of a very mildly elevated bilirubin and a very mild anemia, it is difficult to gauge the source of this issue. I would consider:

6.9 Years

- Pathologist review of the blood smear to look for atypical cells, blood parasites, etc.

WEIGHT

95.2 Pounds

- Infectious disease panel to NC State's vector borne disease lab (canine comprehensive panel).
- Continued monitoring of the red blood cell and other indices on the CBC.

INTERPRETED BY

Kathleen Sennello DVM,
MS, Diplomate ACVIM
(Small Animal Internal
Medicine)

- If this is a non-regenerative anemia based on reticulocyte count, I would consider a bone marrow evaluation.
- Recommend 3-view thoracic radiographs and abdominal radiographs (looking for any metallic foreign bodies, etc.). (Already done)

IMAGING BY

Loetitia Saint-Jacques,
LVT

- If there is strong evidence for an autoimmune process, I would consider starting steroids, although this is not a typical presentation for IMHA.
- Consider a fine needle aspirate of the spleen.

HOSPITAL NAME

Truckee Meadows VH

- Recommend treatment for diarrhea with probiotic therapy, a novel protein or hydrolyzed protein prescription diet, etc. If symptoms persist, you could consider obtaining GI biopsies (depending on if this is a large or small bowel diarrhea).

REFERRING VET

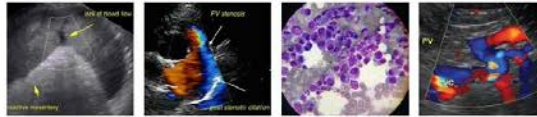
Dr. Rachel Kuester

INVOICE

39232

DATE

7/6/22



PATIENT

Apollo Cordisco

SPECIES

Canine

BREED

Golden Retriever

SEX

Neutered Male

AGE

6.9 Years

WEIGHT

95.2 Pounds

INTERPRETED BY

Kathleen Sennello DVM,
MS, Diplomate ACVIM
(Small Animal Internal
Medicine)

IMAGING BY

Loetitia Saint-Jacques,
LVT

HOSPITAL NAME

Truckee Meadows VH

REFERRING VET

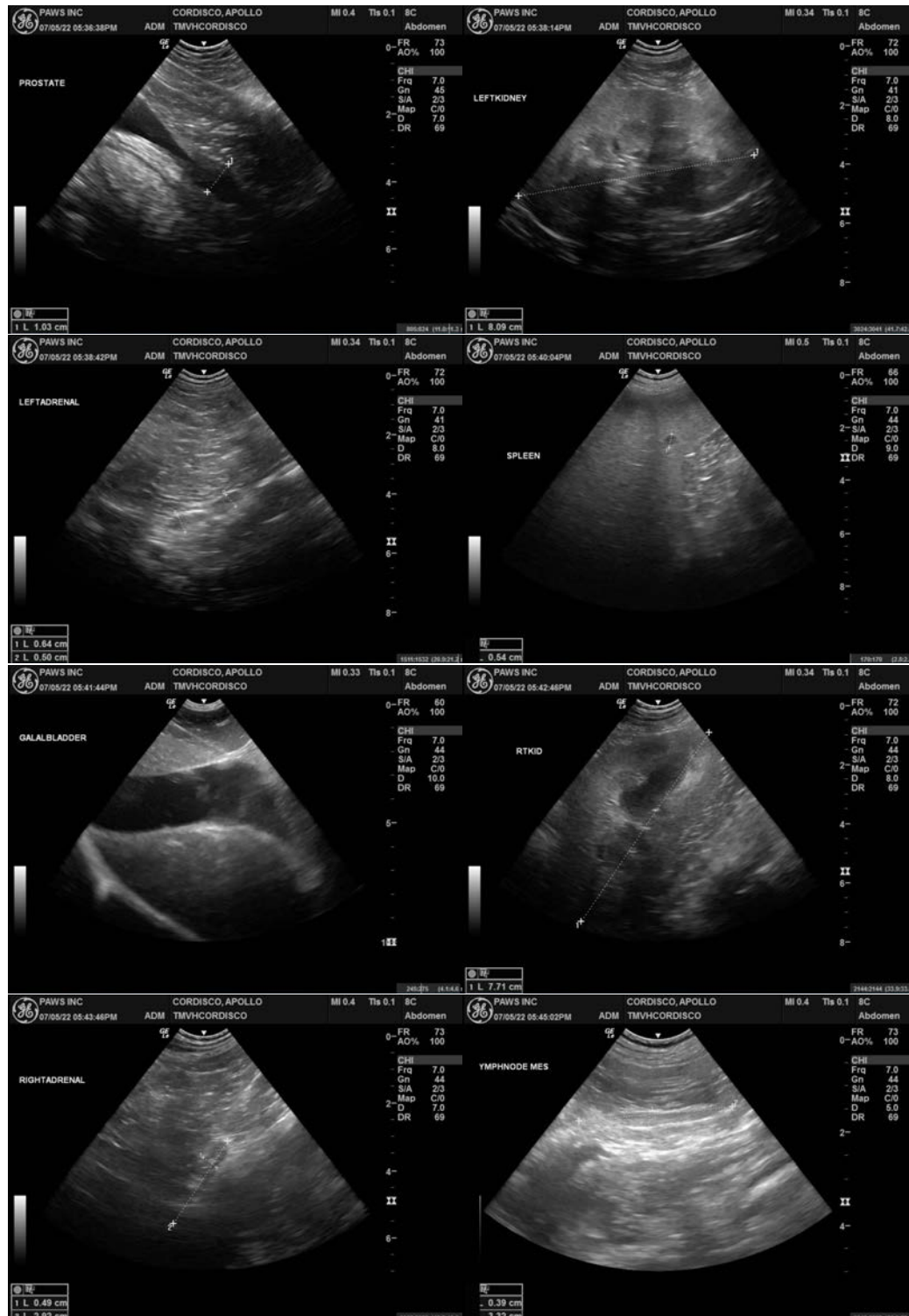
Dr. Rachel Kuester

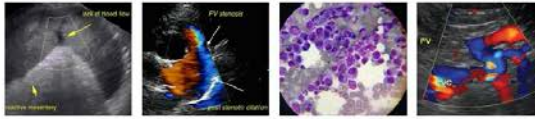
INVOICE

39232

DATE

7/6/22





PATIENT

Apollo Cordisco

SPECIES

Canine

BREED

Golden Retriever

SEX

Neutered Male

AGE

6.9 Years

WEIGHT

95.2 Pounds

INTERPRETED BY

Kathleen Sennello DVM,
MS, Diplomate ACVIM
(Small Animal Internal
Medicine)

IMAGING BY

Loetitia Saint-Jacques,
LVT

HOSPITAL NAME

Truckee Meadows VH

REFERRING VET

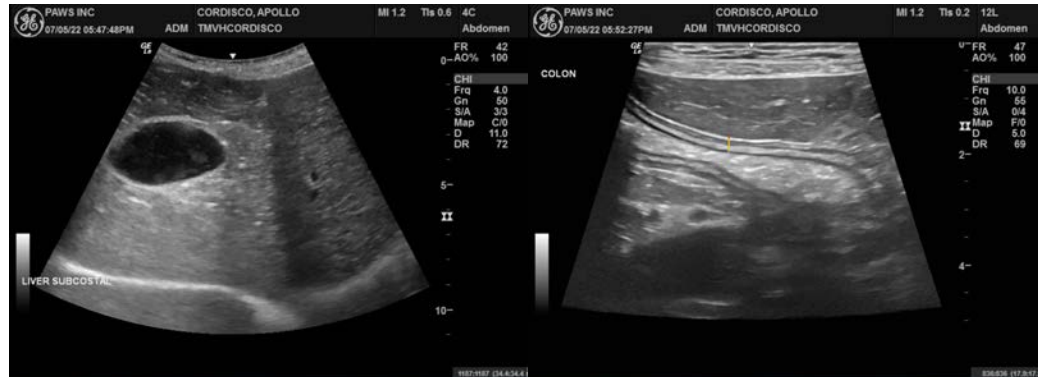
Dr. Rachel Kuester

INVOICE

39232

DATE

7/6/22



The information and recommendations provided are based on the images presented by the referring veterinarian/sonographer. No evaluation can be communicated regarding pathology that was not visible in the image/video clips provided.

Thank you for this referral. If the clinical or image interpretation does not parallel your findings or if I can be of any further assistance please contact me.

Kathleen Sennello DVM,MS, Diplomate ACVIM (Small animal Internal Medicine)
kathleen.sennello@sonopath.com