

**DATE PRESENTING CLINICAL SIGNS**

7/5/23 History of soft tissue sarcoma, elevated liver enzymes, abnormal bile acids, neoplasia?

PATIENT

Mercedes Payne

Current Medications: Denamarin, Clavamox 375mg, Gabapentin 300mg.

Date of Previous IntraPet Ultrasound: No previous.

Sedation: Dexdomitor/Torbugesic.

Stat Report: Not requested.

Imaging Performed By: Stephanie Warga RDCS, RVT.

SPECIES

Canine

ULTRASONOGRAPHIC EXAMINATION OF THE ABDOMEN**BREED**

Shiloh Shepherd

Urinary System

The urinary bladder is mildly distended with anechoic urine. The Bladder wall, trigone, ureteral papillae and visible urethra (to a depth of 2cm) appear normal with no evidence of wall thickening, mucosal irregularities, masses or cystic calculi. Full evaluation of the urinary bladder is difficult due to lack of significant urine distention.

SEX

Spayed Female

The left kidney has a normal shape and size (7.9 cm). Overall echogenicity is normal with adequate corticomedullary distinction and a typical 1:3 cortex:medulla ratio. There is no evidence of focal perinephric inflammation or effusion. There is no evidence of pyelectasia, nephroliths, infarcts or hydroureter. Renal vasculature is normal.

AGE

12/2/10

The right kidney has a normal shape and size (7.58 cm). Overall echogenicity is normal with adequate corticomedullary distinction and a typical 1:3 cortex:medulla ratio. There is no evidence of focal perinephric inflammation or effusion. There is no evidence of pyelectasia, nephroliths, infarcts or hydroureter. Renal vasculature is normal.

WEIGHT

75 Pounds

INTERPRETED BY

Kathleen Sennello DVM,
MS, Diplomate ACVIM
(Small Animal Internal
Medicine)

Adrenal Glands

The left adrenal gland is normal in size measuring 0.57 cm at the caudal pole. It is observed in its normal position cranial to the left renal artery. It is normal in appearance (uniformly hypoechoic) and shape with no evidence of a mass effect.

HOSPITAL NAME

Mt Airy AH

The right adrenal gland is normal in size measuring 0.75 cm at the caudal pole. It is observed in its normal position between the cranial aspect of the right kidney and the caudal vena cava. It is normal in appearance (uniformly hypoechoic) and shape with no evidence of a mass effect.

REFERRING VET

Dr. Riley

Spleen

The spleen is subjectively normal in size. The spleen echotexture is heterogenous and mottled, the splenic capsule is smooth with no irregularities. The blood flow through the hilus and splenic parenchyma appears normal. There are numerous ill-defined hyperechoic lesions visualized throughout the parenchyma, most consistent with benign myelolipomas. Additionally, there is some very subtle hypoechoic mottling evident.

INVOICE

43796

Liver

The liver is subjectively normal in size but slightly irregular. The parenchyma is heterogenous in echotexture with subtle, indistinct focal mottling. The visible portions of the vasculature and biliary tract appear normal. There are occasional very subtle hypoechoic nodules visualized in the parenchyma. On the left side there is a nodule measuring 1.49 cm and 2.8 cm in diameter. On the right side there is a hypoechoic nodule visualized intracostally measuring 1.7 cm in diameter.

The gall bladder lumen is significantly distended. Some areas of the wall appear mildly thickened with adherent debris. There is a large amount of primarily non-organized echogenic debris. There is no evidence of bile duct dilation.

Gastrointestinal

The stomach contains minimal luminal contents. It measures at a normal thickness of <0.7cm with some variability due to the presence of rugal folds. The distinction of the gastric wall layers is adequate and there is no impression of reduced peristaltic activity. No masses or focal lesions were observed.

The visualized areas of duodenum, jejunum and ileum have a relatively uniform diameter with minimal fluid distension. Wall thickness is normal. Bowel loops follow a curvilinear path with distinct wall layering maintaining the typical 1:3 muscularis:mucosa layer ratio. Duodenum wall measures 0.44 cm. Jejunum wall measures 0.37 cm. Visualized peristalsis appears appropriate. There were no focal lesions consistent with obstruction or a mass effect observed.

The ileocecal junction was visualized and exhibited normal intact wall layering and is subjectively of normal thickness. Sections of colon are visualized with formed fecal material and gas shadowing distally. There is no observed focal or generalized colon wall thickening or loss of layering.

Pancreas

The pancreas is normal and isoechoic to surrounding mesentery. There is no evidence of nodules or cystic lesions. There is no evidence of regional mesenteric inflammation or fluid.

Free Abdomen

Evaluation of the peritoneal cavity did not reveal any evidence of effusion, or subjective lymphadenomegaly. The Medial iliac nodes appear normal and there was no evidence of a caudal aortic thrombus at the bifurcation. The omentum is of normal uniform echogenicity.

Other

The right auricle and pericardium were visualized and were unremarkable. No obvious pathology is visualized. If cardiac function evaluation is desired a full echocardiogram is warranted.

ULTRASONOGRAPHIC FINDINGS

- Mildly mottled spleen with hyperechoic foci – The diffuse splenic changes are non-specific and could be consistent with lymphoid hyperplasia, extramedullary hematopoiesis, infiltrative neoplasia, inflammation, other. Cytology or histopathology would be necessary to get a definitive diagnosis. The hyperechoic foci are most consistent with benign myelolipomas.
- Slightly irregular, heterogeneous liver with ill-defined hypoechoic nodules – The diffuse hepatic changes are non-specific and could be consistent with vacuolar hepatopathy, nodular hyperplasia, inflammatory/immune-mediated disease, fibrosis, extramedullary hematopoiesis, toxic hepatopathy (e.g., copper), infiltrative neoplasia (less likely) or other hepatopathy. The nodules observed trend toward a more benign process but underlying neoplasia cannot be ruled out.
- Large distended gallbladder with a large amount of mobile intraluminal debris and mild debris adhered to the gallbladder wall – A large amount of debris is evident in the gall bladder with no evidence of a mucocele or associated inflammation at this time. This could represent an early mucocele or cholestasis, with minimal evidence of associated inflammation at this time. Continued monitoring of labwork and ultrasound are warranted for progression of this lesion. Ursodiol therapy could be considered.

INTERPRETATION OF THE FINDINGS & FURTHER RECOMMENDATIONS

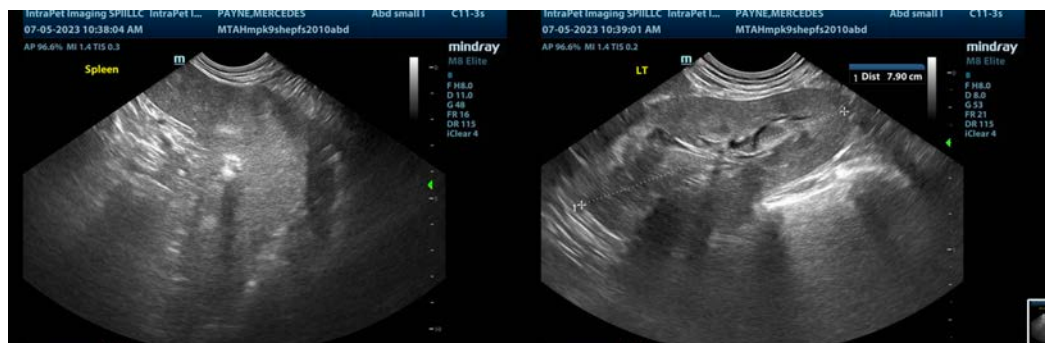
There is no overt evidence of metastatic neoplasia, although there are hypoechoic nodules visualized in the liver, and the spleen is mottled, so a more subtle neoplastic process cannot be definitively ruled out. A fine needle aspirate of the liver and spleen could be considered.

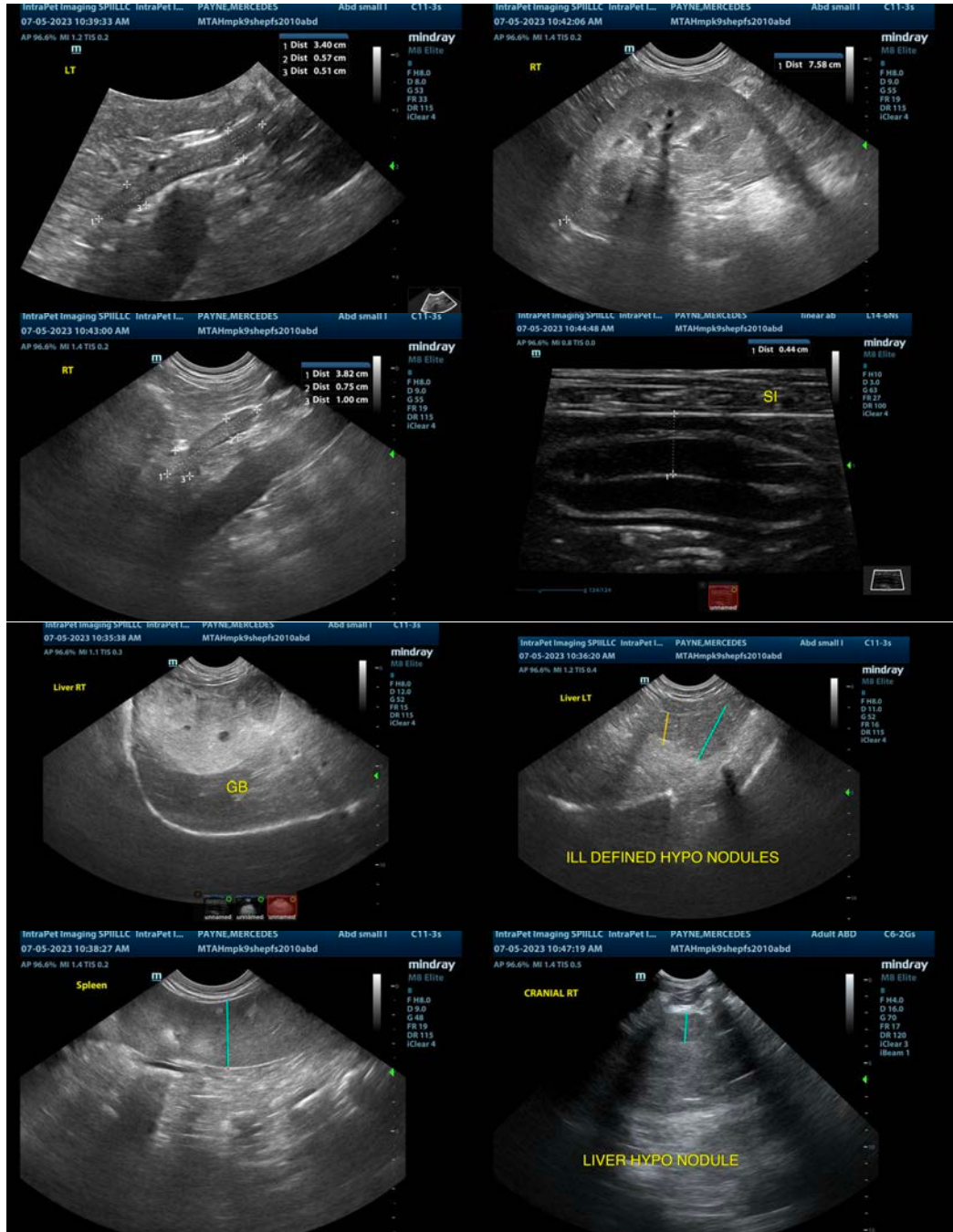
Depending on the degree of the liver enzyme elevations and which enzymes are elevated as well as the severity of the bile acid elevation, there could be concern for a primary hepatopathy. Additionally, the gallbladder has a large amount of intraluminal debris with minimal surrounding inflammation, so it is questionable if this is a major source of clinical signs at this time. These are general recommendations if a primary hepatopathy is recommended:

- Consider close evaluation of history for possible toxic changes examine medications, diet, dietary indiscretion etc...
- Consider PCR on urine/serum for leptospirosis (if not on antibiotics)/serology if recent antibiotic history
- If not already done, consider pre and post prandial bile acids to evaluate liver function
- Consider Fine needle aspirate if round cell neoplasia is on your differentia list (25 g needle, normal coags)
- If no response to supportive care (Denamarin, fluids, antibiotics, +/- ursodiol etc.) Consider liver biopsy with samples obtained for histopathology, culture, and copper levels.

If the gallbladder is suspected to be a significant source of liver enzyme elevations, etc., you could consider treatment for cholecystitis and continued monitoring of the gallbladder with ultrasound.

Recommend three view thoracic radiographs to evaluate for possible concurrent thoracic disease/involvement.





The information and recommendations provided are based on the images presented by the referring veterinarian/sonographer. No evaluation can be communicated regarding pathology that was not visible in the image/video clips provided.

Thank you for this referral. If the clinical or image interpretation does not parallel your findings or if I can be of any further assistance please contact me.

Kathleen Sennello DVM,MS, Diplomate ACVIM (Small animal Internal Medicine)
 info@sonopath.com