

**DATE PRESENTING CLINICAL SIGNS**

7/3/23

O noticed blood dripping out of her rectum last night. They noticed she did not clean herself and O cleaned her rear end with a napkin and noticed blood. There has also been blood spots on her bed. She has not noticed any straining. She has been eating normally -canned and dry.

**PATIENT**

Mila Blackstock

Current Medications: Lactulose Suspension, MiraLAX, Gabapentin, Oral Buprenorphine.

Lab Results: CBC, Chemistry WNL.

Radiographs: Stool in colon; rechecked after defecation---clear.

**SPECIES**

Date of Previous IntraPet Ultrasound: No previous.

Feline

Sedation: Not required to complete full diagnostic ultrasound.

Stat Report: Not requested.

**BREED**

Imaging Performed By: Rachel Brillhart, RDMS.

Russian Blue X

**ULTRASONOGRAPHIC EXAMINATION OF THE ABDOMEN****SEX****Urinary System**

Spayed Female

The urinary bladder is moderately distended with anechoic urine. The Bladder wall, trigone, ureteral papillae and visible urethra (to a depth of 2cm) appear normal with no evidence of wall thickening, mucosal irregularities, masses or cystic calculi.

**AGE**

9/16/09

The left kidney has a normal shape and size (4.14 cm). Overall echogenicity is normal with adequate corticomedullary distinction and a typical 1:3 cortex:medulla ratio. There is no evidence of focal perinephric inflammation or effusion. There is no evidence of pyelectasia, nephroliths, infarcts or hydroureter. Renal vasculature is normal.

**WEIGHT**

18.8 Pounds

The right kidney has a normal shape and size (4.51 cm). Overall echogenicity is normal with adequate corticomedullary distinction and a typical 1:3 cortex:medulla ratio. There is no evidence of focal perinephric inflammation or effusion. There is no evidence of pyelectasia, nephroliths, infarcts or hydroureter. Renal vasculature is normal.

**INTERPRETED BY**

Kathleen Sennello DVM,  
MS, Diplomate ACVIM  
(Small Animal Internal  
Medicine)

**Adrenal Glands**

The left adrenal gland is normal in size measuring 0.43 cm at the caudal pole. It is observed in its normal position cranial to the left renal artery. It is normal in appearance (uniformly hypoechoic) and shape with no evidence of a mass effect.

**HOSPITAL NAME**

Animal Emergency  
Hospital

The right adrenal gland is normal in size measuring 0.46 cm at the caudal pole. It is observed in its normal position between the cranial aspect of the right kidney and the caudal vena cava. It is normal in appearance (uniformly hypoechoic) and shape with no evidence of a mass effect.

**REFERRING VET**

Dr. Martinoli

**Spleen**

The spleen is subjectively normal in size (1.0 cm), echotexture is homogenous, and the splenic capsule is smooth with no irregularities. The blood flow through the hilus and splenic parenchyma appears normal. No focal parenchymal abnormalities are visualized.

**INVOICE**

43713

**Liver**

The liver is subjectively normal in size, and echogenicity with smooth peripheral margins. The parenchyma is homogenous echotexture. The visible portions of the vasculature and biliary tract appear normal. No focal nodules or cystic lesions are observed.

The gallbladder lumen is moderately distended. The wall of the gall bladder is not thickened and has a smooth mucosal surface. Luminal contents are mild and primarily anechoic. The cystic and common bile ducts are normal/not visible.

### ***Gastrointestinal***

The stomach contains minimal luminal contents. It measures at a normal thickness of <0.36cm with some variability due to the presence of rugal folds. The distinction of the gastric wall layers is adequate and there is no impression of reduced peristaltic activity. No masses or focal lesions were observed.

The visualized areas of duodenum, jejunum and ileum have a uniform diameter with minimal fluid distension. Wall thickness is normal to slightly increased. Bowel loops follow a typical curvilinear path with distinct wall layering, but some areas display a prominent muscularis layer which does not display the typical 1:3 muscularis:mucosa layer ratio. Jejunum wall measures 0.20 cm. Duodenum wall measures 0.28 cm. Visualized peristalsis appears appropriate. There were no focal lesions consistent with obstruction or a mass effect observed.

The ileocecal junction was visualized and exhibited normal intact wall layering and is subjectively of normal thickness. Sections of colon are visualized with formed fecal material and gas shadowing distally. There is no observed focal or generalized colon wall thickening or loss of layering. Colon wall measures 0.13 cm. The distal rectum was imaged with no obvious mass lesions observed.

### ***Pancreas***

The pancreas is normal and isoechoic to surrounding mesentery. There is no evidence of nodules or cystic lesions. There is no evidence of regional mesenteric inflammation or fluid.

### ***Free Abdomen***

Evaluation of the peritoneal cavity did not reveal any evidence of effusion, or subjective lymphadenomegaly. The Medial iliac nodes appear normal and there was no evidence of a caudal aortic thrombus at the bifurcation. The omentum is of normal uniform echogenicity.

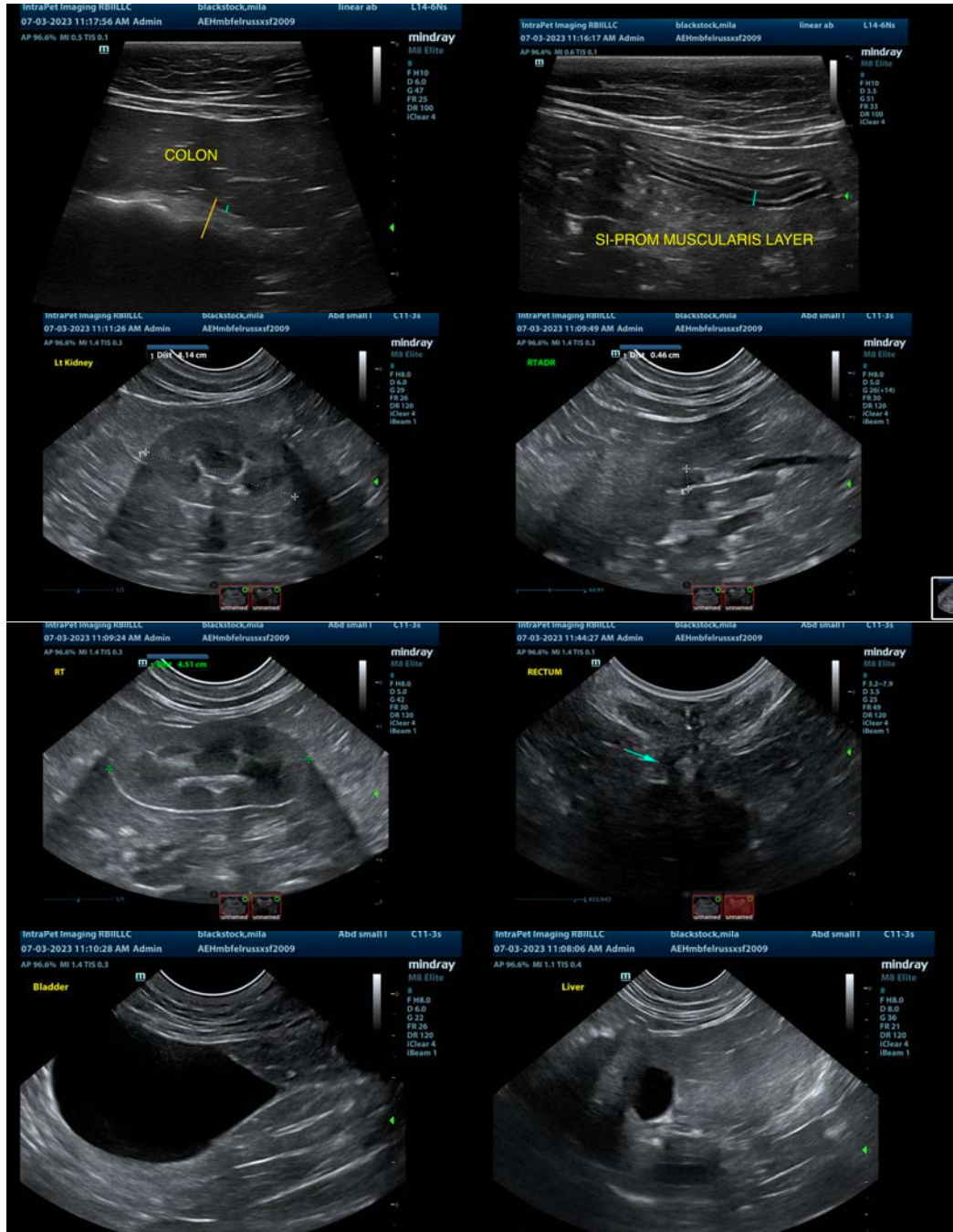
## **ULTRASONOGRAPHIC FINDINGS**

- Subjectively prominent muscularis layer of the small intestine – The small intestinal wall changes could be consistent with an underlying inflammatory process. These types of changes can sometimes be seen in normal older cats. Correlate with clinical signs.

## **INTERPRETATION OF THE FINDINGS & FURTHER RECOMMENDATIONS**

Today's scan appears relatively normal. The muscularis layer is slightly prominent in the small intestine. This can be a normal finding in some older cats. If there are symptoms of small bowel disease (melena, small bowel diarrhea, weight loss, etc.), you could consider further workup for a primary enteropathy. Given the current symptoms, large bowel disease is primarily suspected. If there is no history of large bowel diarrhea, then primary concern would be a mucosal irregularity (polyp, mass, ulceration, inflammatory disease, etc.). Unfortunately, ultrasound is insensitive in evaluation of colonic and rectal disease. Consider a colonoscopy for further evaluation if symptoms persist.

Recommend three view thoracic radiographs to evaluate for possible concurrent thoracic disease/involvement.



The information and recommendations provided are based on the images presented by the referring veterinarian/sonographer. No evaluation can be communicated regarding pathology that was not visible in the image/video clips provided.

Thank you for this referral. If the clinical or image interpretation does not parallel your findings or if I can be of any further assistance please contact me.

Kathleen Sennello DVM,MS, Diplomate ACVIM (Small animal Internal Medicine)  
 info@sonopath.com