

IMAGING PERFORMED BY

IntraPet.com



SonoPath

Clinical Sonography & Telectology

EDUCATIONAL TELECONSULTATION SERVICES™

1-800-838-4268 info@sonopath.com SonoPath.com

DATE PRESENTING CLINICAL SIGNS

7/29/22

Abdominal distension over the past couple weeks causing pet to have difficulty breathing, has been wheezing and coughing.

PATIENT

Snake Wasmer

Current Medications: Fluticasone propionate inhaler-- as needed
Albuterol inhaler-- as needed, hydrocodone-- as needed, metoclopramide 10mg-- 1/2 tab tid 3 days, then 1/2 tab bid, otc probiotics

SPECIES

Canine

Radiographs: large bladder, enlargement of liver, distension of abdomen, ingesta in the stomach with delayed emptying-- o noted last meal was 8-12 hours ago, loss of detail mid/cranial abdomen.

Date of Previous IntraPet Ultrasound: No previous.

Sedation: Not required to complete full diagnostic ultrasound.

Stat Report: Not requested.

BREED

Dachshund

ULTRASONOGRAPHIC EXAMINATION OF THE ABDOMEN

SEX

Neutered Male

Urinary System

The urinary bladder is moderately distended with anechoic urine. The Bladder wall, trigone, ureteral papillae and visible urethra (to a depth of 2cm) appear normal with no evidence of wall thickening, mucosal irregularities, masses or cystic calculi.

AGE

10/15/08

The left kidney has a normal shape and size (4.5 cm). Overall echogenicity is slightly hyperechoic with poor corticomedullary distinction and a typical 1:3 cortex:medulla ratio. There is no evidence of perinephric inflammation or effusion. There is no evidence of pyelectasia, nephroliths, infarcts or hydroureter. Renal vasculature is normal.

WEIGHT

19 Pounds

The right kidney has a normal shape and size (4.81 cm). Overall echogenicity is slightly hyperechoic with poor corticomedullary distinction and a typical 1:3 cortex:medulla ratio. There is no evidence of perinephric inflammation or effusion. There is no evidence of pyelectasia, nephroliths, infarcts or hydroureter. Renal vasculature is normal.

INTERPRETED BY

Kathleen Sennello DVM,
MS, Diplomate ACVIM
(Small Animal Internal
Medicine)

Adrenal Glands

The left adrenal gland is normal/borderline plump, measuring 0.65 cm at the caudal pole. It is observed in its normal position cranial to the left renal artery. It is normal in appearance (uniformly hypoechoic) and shape with no evidence of a mass effect.

IMAGING PERFORMED BY

Andi Parkinson RDMS

The right adrenal gland is normal/borderline plump, measuring 0.54 cm at the caudal pole. It is observed in its normal position between the cranial aspect of the right kidney and the caudal vena cava. It is normal in appearance (uniformly hypoechoic) and shape with no evidence of a mass effect.

HOSPITAL NAME

Animal Care Center

Spleen

The spleen is subjectively normal in size, echotexture is homogenous, and the splenic capsule is smooth with no irregularities. The blood flow through the hilus and splenic parenchyma appears normal. No focal parenchymal abnormalities are visualized.

REFERRING VET

Dr. Beavers

Liver

The liver is large in size, and normal in echogenicity with smooth peripheral margins. The parenchyma is heterogenous in echotexture with subtle, indistinct focal mottling. The visible portions of the vasculature and biliary tract appear normal. There is an ill-defined hyperechoic nodule measuring 1.12 cm x 1.01 cm. Additionally, there is a small hypoechoic lesion measuring 1.8 cm x 1.43 cm.

INVOICE

39956

The gall bladder lumen is moderately distended. The wall of the gall bladder is not thickened and has a smooth mucosal surface. There is a moderate amount of non-organized echogenic debris. The cystic and common bile ducts are normal/not visible.

Gastrointestinal

The stomach contains minimal luminal contents. It measures at a normal thickness of <0.7cm with some variability due to the presence of rugal folds. The distinction of the gastric wall layers is adequate and there is no impression of reduced peristaltic activity. No masses or focal lesions were observed.

The visualized areas of duodenum, jejunum and ileum have a relatively uniform diameter with minimal fluid distension. Wall thickness is normal. Bowel loops follow a curvilinear path with distinct wall layering maintaining the typical 1:3 muscularis:mucosa layer ratio. Jejunum wall measured 0.34 cm. Visualized peristalsis appears appropriate. There were no focal lesions consistent with obstruction or a mass effect observed.

The ileocecal junction was visualized and exhibited normal intact wall layering and is subjectively of normal thickness. Sections of colon are visualized with formed fecal material and gas shadowing distally. There is no observed focal or generalized colon wall thickening or loss of layering.

Pancreas

The pancreas is prominent and mottled compared to the surrounding isoechoic mesentery. There is no evidence of nodules or cystic lesions. There is no evidence of regional mesenteric inflammation or fluid.

Free Abdomen

Evaluation of the peritoneal cavity did not reveal any evidence of effusion, or subjective lymphadenomegaly. The Medial iliac nodes appear normal and there was no evidence of a caudal aortic thrombus at the bifurcation. The omentum is of normal uniform echogenicity.

PRIMARY FINDINGS

- Large, heterogeneous liver with ill-defined hyper- and hypoechoic nodule – The diffuse hepatic changes are non-specific and could be consistent with vacuolar hepatopathy, nodular hyperplasia, inflammatory/immune-mediated disease, fibrosis, extramedullary hematopoiesis, toxic hepatopathy (e.g., copper), infiltrative neoplasia (less likely) or other hepatopathy.
- Moderate gallbladder debris – The significance of the aggregated gallbladder sludge is unclear. This could represent an early mucocele, cholestasis, or may be secondary to fasting.

SECONDARY FINDINGS

- Decreased corticomedullary distinction in both kidneys – The bilateral renal findings are consistent with age-related change.
- Prominent, mottled pancreas – The pancreatic changes are most consistent with age-related parenchymal remodeling, potentially secondary to a prior inflammatory episode, early fibrosis or chronic pancreatitis.
- Large amount of intraabdominal fat

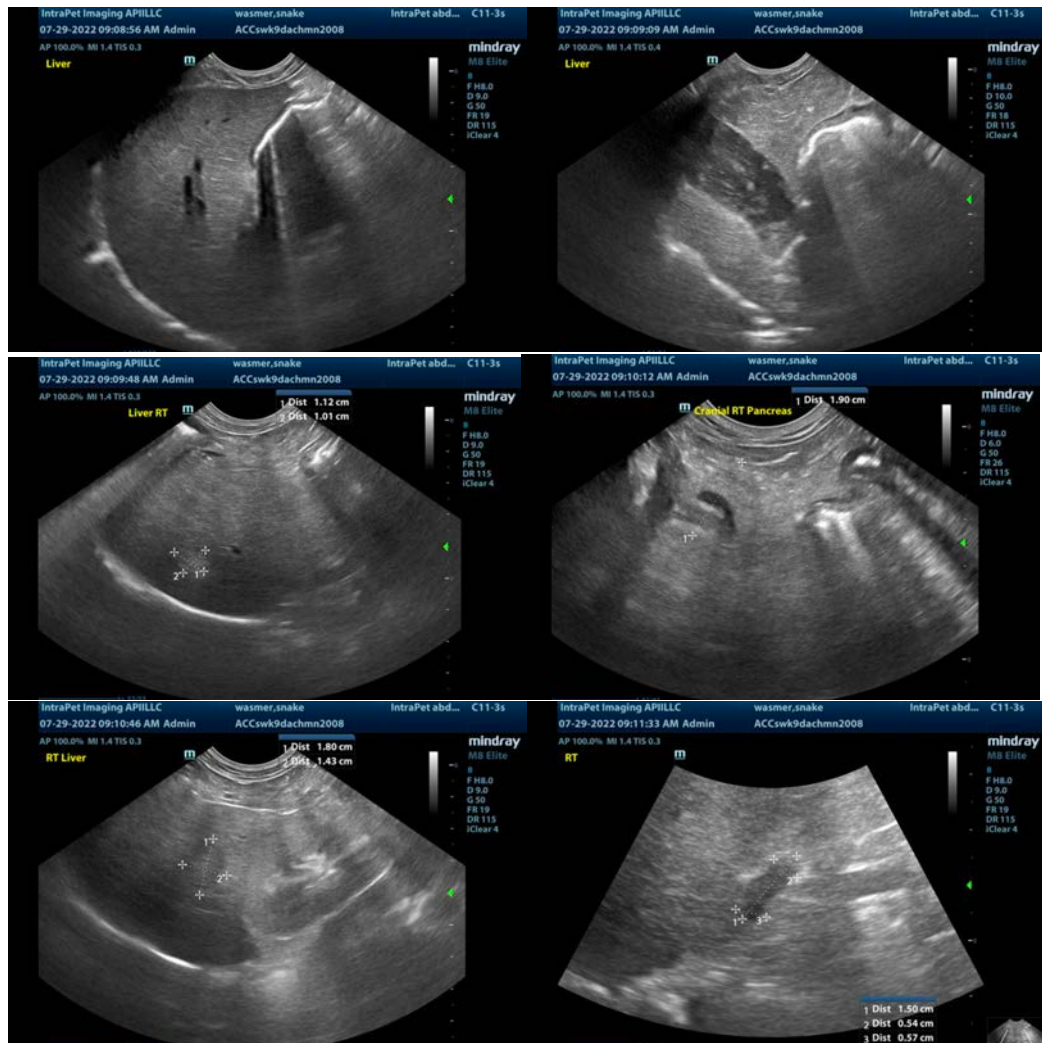
INTERPRETATION OF THE FINDINGS & FURTHER RECOMMENDATIONS

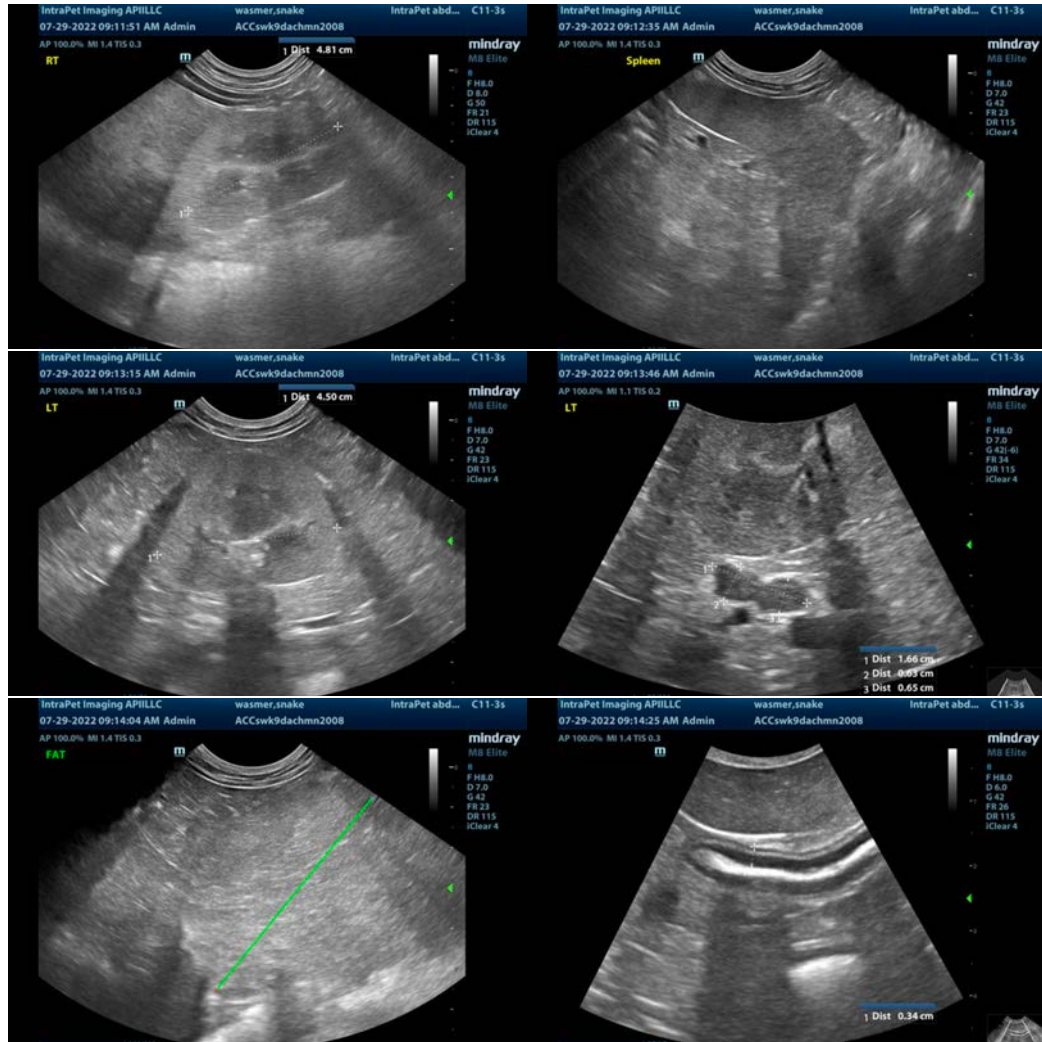
No focal mass lesions are observed on today's scan. The liver does appear somewhat enlarged. Correlate this with bloodwork findings. If liver enzyme elevations are present, consider further workup for a primary

hepatopathy or a vacuolar hepatopathy. There are two ill-defined nodules visualized within the liver. The appearance of these nodules trends towards a benign process, although an underlying neoplastic process cannot be ruled out. Options moving forward include continued monitoring with ultrasound or fine needle aspiration.

Additionally, the gallbladder has a moderate amount of debris. If liver enzyme elevations are present, consider Ursodiol therapy and continued monitoring.

An obvious cause for the significant abdominal distention is not identified, although there is a large amount of intraabdominal fat. This does not appear encapsulated like an intraabdominal lipoma, although this could be a possibility.





The information and recommendations provided are based on the images presented by the referring veterinarian/sonographer. No evaluation can be communicated regarding pathology that was not visible in the image/video clips provided.

Thank you for this referral. If the clinical or image interpretation does not parallel your findings or if I can be of any further assistance please contact me.

Kathleen Sennello DVM,MS, Diplomate ACVIM (Small animal Internal Medicine)
 kathleen.sennello@sonopath.com