



PATIENT

Eli Freeman-Griffin

PRESENTING CLINICAL SIGNS

Jaundice, inappetent, decreased appetite. Current meds: IVF, Cerenia, Unasyn
Abnormal PE/Chem/CBC/UA Results: WBC 24.6 (19.5 H); NEUT 22.93 (12.58 H); ALT 131 (100H);
GGT <10 was 22; TBILI 2.4 (0.5H) was 12.6

SPECIES

Feline

ULTRASONOGRAPHIC EXAMINATION OF THE ABDOMEN

BREED

DSH

Urinary System

The urinary bladder is moderately distended with echogenic urine. The Bladder wall appears mildly diffusely thickened and irregular. Additionally, there are several hyperechoic shadowing mobile structures most consistent with calculi visualized in the dependent portion of the urinary bladder. Two of these measure at 0.61 cm and 0.56 cm. The area of the trigone, ureteral papillae and proximal urethra appear free of any mass lesions or calculi at this time.

SEX

Neutered Male

The left kidney has a normal shape and size (4.46 cm). Overall echogenicity is normal with adequate corticomedullary distinction and a typical 1:3 cortex:medulla ratio. There is no evidence of perinephric inflammation or effusion. There is no evidence of pyelectasia, nephroliths, infarcts or hydroureter. Renal vasculature is normal.

AGE

2 Years

The right kidney has a normal shape and size (5.14 cm). Overall echogenicity is normal with adequate corticomedullary distinction and a typical 1:3 cortex:medulla ratio. Mild areas of mineralization are noted at the renal pelvis and at the corticomedullary junction, but there is no evidence of renal pelvic dilation, obstruction, etc. There is significant perirenal inflammation and a small amount of echogenic fluid. Renal vasculature is normal.

WEIGHT

Not Provided

Adrenal Glands

The left adrenal gland is normal in size measuring 0.52 cm at the caudal pole. It is observed in its normal position cranial to the left renal artery. It is normal in appearance (uniformly hypoechoic) and shape with no evidence of a mass effect.

The right adrenal gland is normal in size measuring 0.55 cm at the caudal pole. It is observed in its normal position between the cranial aspect of the right kidney and the caudal vena cava. It is normal in appearance (uniformly hypoechoic) and shape with no evidence of a mass effect.

INTERPRETED BY

Kathleen Sennello DVM,
MS, Diplomate ACVIM
(Small Animal Internal
Medicine)

IMAGING PERFORMED BY

Shari Reffi, CVT

Spleen

The spleen is subjectively normal in size (0.71 cm in width at the level of the hilus), echotexture is homogenous, and the splenic capsule is smooth with no irregularities. The blood flow through the hilus and splenic parenchyma appears normal. No focal parenchymal abnormalities are visualized.

HOSPITAL NAME

Newton Vet Hospital

Liver

The liver is large in size with smooth peripheral margins. The parenchyma is hyperechoic and homogenous in echotexture. The visible portions of the vasculature and biliary tract appear normal. No focal nodules or cystic lesions are observed.

REFERRING VET

Dr. Kim

INVOICE

39873

The gallbladder lumen is moderately distended. The wall of the gall bladder is not thickened and has a smooth mucosal surface. Luminal contents are primarily anechoic. The cystic and common bile ducts are normal/not visible.

Gastrointestinal

DATE

7/28/22



PATIENT

Eli Freeman-Griffin

The visualized areas of duodenum, jejunum and ileum have a uniform diameter with minimal fluid distension. Wall thickness is normal to slightly increased. Bowel loops follow a typical curvilinear path with distinct wall layering, but some areas display a prominent muscularis layer which does not display the typical 1:3 muscularis:mucosa layer ratio. Visualized peristalsis appears appropriate. There were no focal lesions consistent with obstruction or a mass effect observed.

SPECIES

Feline

The visualized areas of duodenum, jejunum and ileum have a relatively uniform diameter with minimal fluid distension. Wall thickness is normal. Bowel loops follow a curvilinear path with distinct wall layering maintaining the typical 1:3 muscularis:mucosa layer ratio. The duodenum measured as normal (between 0.13-0.38cm in wall thickness) and the jejunum measured as normal (between 0.15-0.36cm.) Visualized peristalsis appears appropriate. There were no focal lesions consistent with obstruction or a mass effect observed.

BREED

DSH

SEX

Neutered Male

The ileocecal junction was visualized and exhibited normal intact wall layering and is subjectively of normal thickness. Sections of colon are visualized with formed fecal material and gas shadowing distally. There is no observed focal or generalized colon wall thickening or loss of layering.

AGE

2 Years

Pancreas

The pancreas is normal and isoechoic to surrounding mesentery. There is no evidence of nodules or cystic lesions. There is no evidence of regional mesenteric inflammation or fluid.

Free Abdomen

There is a small amount of free abdominal fluid. No lymphadenopathy. The omentum is hyperechoic around the right kidney.

WEIGHT

Not Provided

PRIMARY FINDINGS

INTERPRETED BY

Kathleen Sennello DVM,
MS, Diplomate ACVIM
(Small Animal Internal
Medicine)

- Moderately distended urinary bladder with a large amount of echogenic urine, slightly irregular urinary bladder wall, and multiple shadowing calculi – most consistent with cystitis and calculi. Recommend urinalysis and culture, correlate with abdominal radiographs, and likely cystotomy.
- Large, hyperechoic liver – Hepatic changes are non-specific and could be consistent with hepatic lipidosis, inflammatory/infectious disease, infiltrative neoplasia, or other hepatopathy.
- Severe perinephric inflammation and scant echogenic perinephric fluid – Consider inflammation, infection, neoplastic change, etc.

IMAGING PERFORMED BY

Shari Reffi, CVT

SECONDARY FINDINGS

- Moderate amount of ingesta within the gastric lumen – Correlate with feeding history. If the patient was adequately fasted, consider delayed gastric emptying or a partial outflow tract obstruction (none observed).

HOSPITAL NAME

Newton Vet Hospital

INTERPRETATION OF THE FINDINGS & FURTHER RECOMMENDATIONS

REFERRING VET

Dr. Kim

There is a significant amount of inflammation surrounding the right kidney, and some echogenic perinephric fluid. Consider sampling this fluid for fluid analysis, cytology and culture. An obvious cause for this inflammation is not readily identified. There are calculi visualized in the urinary bladder, so there is the possibility of a previous ureteral stone, urine leakage, etc., but none is readily seen. If fluid continues to build, or this patient becomes azotemic, you could consider a contrast study or a contrast CT scan to further evaluate the right kidney and urine outflow.

INVOICE

39873

DATE

7/28/22



PATIENT

Eli Freeman-Griffin

There is no significant evidence for biliary disease, and the liver subjectively appears somewhat hyperechoic. The elevation in bilirubin and liver values could be secondary to sepsis if there is infection associated with the inflammation around the kidney, or it could be due to a primary hepatopathy. If coagulation parameters permit, consider a fine needle aspirate of the liver.

SPECIES

Feline

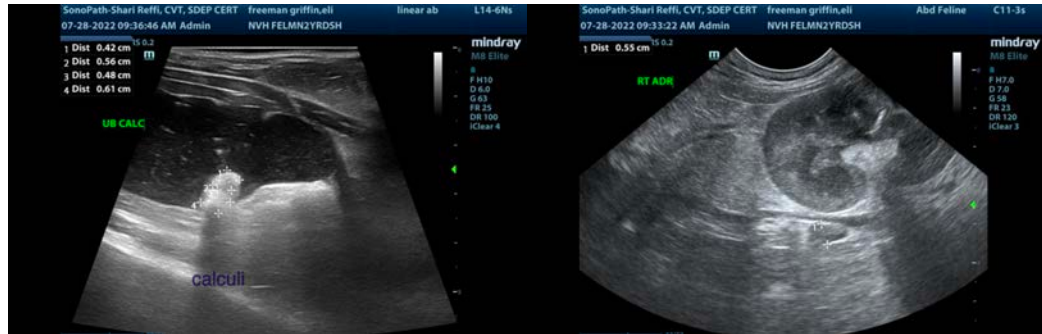
Consider three view thoracic radiographs to rule out concurrent thoracic disease/involvement.

BREED

DSH

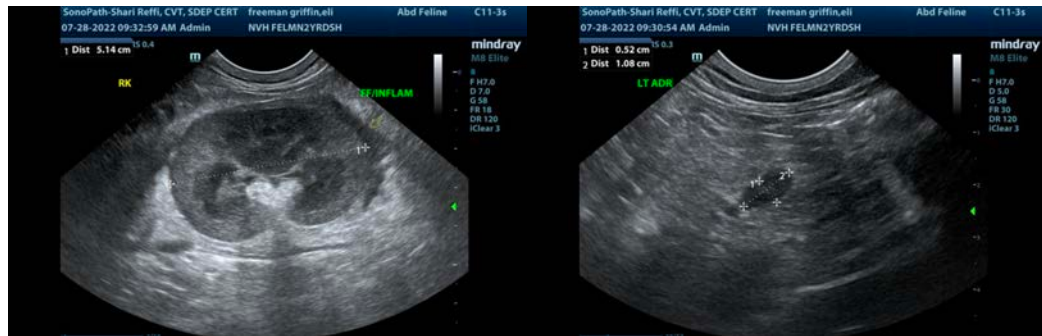
SEX

Neutered Male



AGE

2 Years

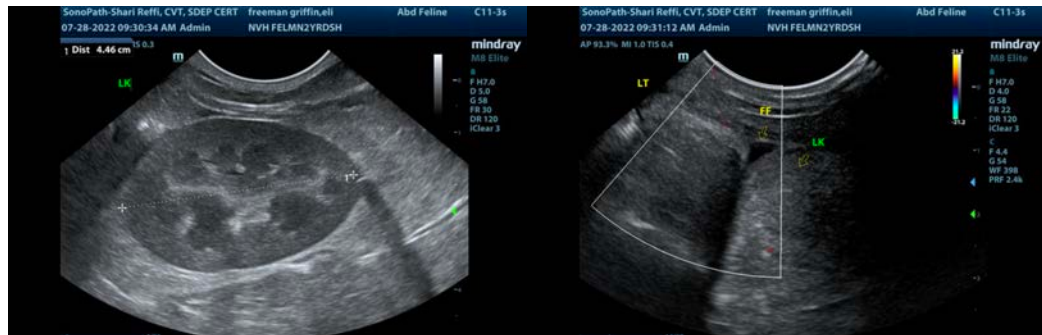


WEIGHT

Not Provided

INTERPRETED BY

Kathleen Sennello DVM, MS, Diplomate ACVIM (Small Animal Internal Medicine)

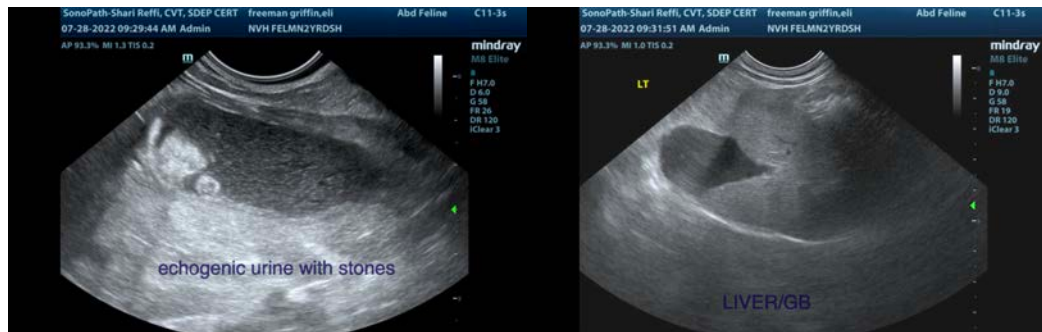


IMAGING PERFORMED BY

Shari Reffi, CVT

HOSPITAL NAME

Newton Vet Hospital



REFERRING VET

Dr. Kim

INVOICE

39873

DATE

7/28/22



PATIENT

Eli Freeman-Griffin

SPECIES

Feline

BREED

DSH

SEX

Neutered Male

AGE

2 Years

WEIGHT

Not Provided

INTERPRETED BY

Kathleen Sennello DVM,
MS, Diplomate ACVIM
(Small Animal Internal
Medicine)

**IMAGING
PERFORMED BY**

Shari Reffi, CVT

HOSPITAL NAME

Newton Vet Hospital

REFERRING VET

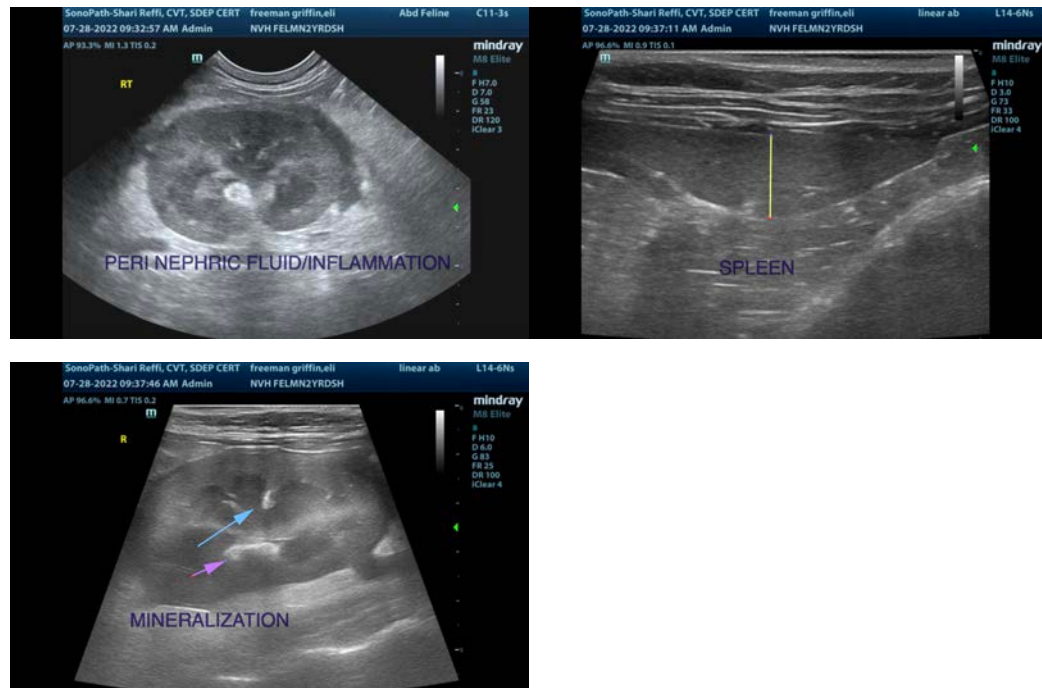
Dr. Kim

INVOICE

39873

DATE

7/28/22



The information and recommendations provided are based on the images presented by the referring veterinarian/sonographer. No evaluation can be communicated regarding pathology that was not visible in the image/video clips provided.

Thank you for this referral. If the clinical or image interpretation does not parallel your findings or if I can be of any further assistance please contact me.

Kathleen Sennello DVM,MS, Diplomate ACVIM (Small animal Internal Medicine)

kathleen.sennello@sonopath.com