

**PATIENT**

Dinah Stack

**SPECIES**

Canine

**BREED**

Cavalier King Charles

**SEX**

Spayed Female

**AGE**

12 Years

**WEIGHT**

15.2 Pounds

**INTERPRETED BY**Kathleen Sennello DVM,  
MS, Diplomate ACVIM  
(Small Animal Internal  
Medicine)**IMAGING  
PERFORMED BY**

Amy Mayhew, LVT

**HOSPITAL NAME**

SVS Imaging MI

**REFERRING VET**Wixom Family Pet  
Practice**INVOICE**

39853

**DATE**

7/27/22

**PRESENTING CLINICAL SIGNS**

Current Medications: Meloxicam 15lb dose PO SID, Enalapril 5mg PO BID, Metronidazole 250mg BID, Prednisolone 5mg PO SID (just started tapering from BID, has been on for 4 weeks from previous vet), Sulfasalazine 500mg PO BID, had owner stop the Pepto bismol that was prescribed from previous vet. Started Pepcid AC 5mg PO BID. Patient History: Chronic diarrhea, weight loss and decreased appetite for 4 months. Previous vet has been treating with several medications, some improvement. Blood work was done and owner reports high WBC previously, but I don't have records. Heart murmur for a few years, on Enalapril, but no chest rads/echo were ever done. No vomiting, urinating normally. More recently is having episodes of gagging while eating, much slower on walks. Stool is like soft serve with some mucous, no blood, did have tenesmus today. It was very watery a few weeks ago.

Abnormal PE/Chem/CBC/UA Results: Thin, grade 3/6 left and right sided heart murmur, pale pink MM, mild tartar/gingivitis diffuse, no oral masses/FB, swallowing appears normal. Haziness to lenses OU. Abdomen is soft, non-painful. Blood work shows severe hepatopathy, mild anemia, T4 is low, mild neutrophilia, UA shows hematuria, pyuria, cocci and rod bacteruria. Concern for esophagitis and that the dog has been on corticosteroids and NSAID for 1 month. Chronic issue concern for IBD, pancreatitis, EPI, neoplasia. The liver changes may be related to the recent steroids. The owner does not think those values were elevated before. \*\*please see attached BW

**ULTRASONOGRAPHIC EXAMINATION OF THE ABDOMEN****Urinary System**

The urinary bladder is moderately distended with anechoic urine. The Bladder wall, trigone, ureteral papillae and visible urethra (to a depth of 2cm) appear normal with no evidence of wall thickening, mucosal irregularities, masses or cystic calculi.

The left kidney has a normal shape and size (5.57 cm). Overall echogenicity is normal with adequate corticomedullary distinction and a typical 1:3 cortex:medulla ratio. There is no evidence of perinephric inflammation or effusion. There is no evidence of pyelectasia, nephroliths, infarcts or hydroureter. Renal vasculature is normal.

The right kidney has a normal shape and size (5.67 cm). Overall echogenicity is normal with adequate corticomedullary distinction and a typical 1:3 cortex:medulla ratio. There is no evidence of perinephric inflammation or effusion. There is no evidence of pyelectasia, nephroliths, infarcts or hydroureter. Renal vasculature is normal.

**Adrenal Glands**

The left adrenal gland is normal in size measuring 0.34 cm at the caudal pole. It is observed in its normal position cranial to the left renal artery. It is normal in appearance (uniformly hypoechoic) and shape with no evidence of a mass effect.

The right adrenal gland is normal in size measuring 0.56 cm at the caudal pole. It is observed in its normal position between the cranial aspect of the right kidney and the caudal vena cava. It is normal in appearance (uniformly hypoechoic) and shape with no evidence of a mass effect.

**Spleen**

The spleen is large, hypoechoic, mottled, and irregular. The blood flow through the hilus and splenic parenchyma appears normal. The spleen is lumpy and nodular with numerous subtle mass effects that appear to be disrupting the splenic capsule. There are both hypo- and hyperechoic lesions visualized. A focal hypoechoic nodule measures 0.55 cm. A hyperechoic nodule measures 0.55 cm. Additional hypoechoic nodules measure 0.86, 0.96, and 1.4 cm. In some areas, the mottling is prominent, almost appearing cavitated.

**PATIENT**

Dinah Stack

**SPECIES**

Canine

**BREED**

Cavalier King Charles

**SEX**

Spayed Female

**AGE**

12 Years

**WEIGHT**

15.2 Pounds

**INTERPRETED BY**Kathleen Sennello DVM,  
MS, Diplomate ACVIM  
(Small Animal Internal  
Medicine)**IMAGING  
PERFORMED BY**

Amy Mayhew, LVT

**HOSPITAL NAME**

SVS Imaging MI

**REFERRING VET**Wixom Family Pet  
Practice**INVOICE**

39853

**DATE**

7/27/22

**Liver**

The liver is large in size, and normal in echogenicity with smooth peripheral margins. The parenchyma is heterogenous in echotexture with subtle, indistinct focal mottling. Pinpoint hyperechoic foci are noted. The visible portions of the vasculature and biliary tract appear normal. No focal nodules or cystic lesions are observed.

The gallbladder lumen is moderately distended. The wall of the gall bladder is not thickened and has a smooth mucosal surface. Luminal contents are primarily anechoic. The cystic and common bile ducts are normal/not visible.

**Gastrointestinal**

The stomach contains minimal luminal contents. It measures at a normal thickness of <0.7cm with some variability due to the presence of rugal folds. The distinction of the gastric wall layers is adequate and there is no impression of reduced peristaltic activity. No masses or focal lesions were observed.

The visualized areas of duodenum, jejunum and ileum have a relatively uniform diameter with minimal fluid distension. Wall thickness is normal. Bowel loops follow a curvilinear path with distinct wall layering maintaining the typical 1:3 muscularis:mucosa layer ratio. Duodenum wall measured 0.30 cm. Jejunum wall measured 0.28 cm. Visualized peristalsis appears appropriate. There were no focal lesions consistent with obstruction or a mass effect observed.

The ileocecal junction was visualized and exhibited normal intact wall layering and is subjectively of normal thickness. Sections of colon are visualized with nonformed fecal material and gas shadowing distally. There is no observed focal or generalized colon wall thickening or loss of layering. Colon wall measured 0.22 cm.

**Pancreas**

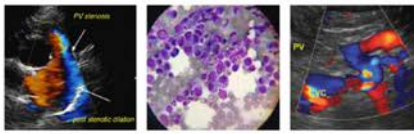
The pancreas is prominent and mottled compared to the surrounding isoechoic mesentery. There is no evidence of nodules or cystic lesions. There is no evidence of regional mesenteric inflammation or fluid.

**Free Abdomen**

Evaluation of the peritoneal cavity did not reveal any evidence of effusion, or subjective lymphadenomegaly. The Medial iliac nodes appear normal and there was no evidence of a caudal aortic thrombus at the bifurcation. The omentum is of normal uniform echogenicity.

**ULTRASONOGRAPHIC FINDINGS**

- Large, irregular, mottled and nodular spleen – The changes observed are concerning for an underlying neoplastic process. Recommend a fine needle aspirate.
- Large, heterogeneous liver – The diffuse hepatic changes are non-specific and could be consistent with vacuolar hepatopathy, nodular hyperplasia, inflammatory/immune-mediated disease, fibrosis, extramedullary hematopoiesis, toxic hepatopathy (e.g., copper), infiltrative neoplasia (less likely) or other hepatopathy.
- Prominent, mottled pancreas – The pancreatic changes are most consistent with age-related parenchymal remodeling, potentially secondary to a prior inflammatory episode, early fibrosis or chronic pancreatitis.



**PATIENT**

Dinah Stack

**SPECIES**

Canine

**BREED**

Cavalier King Charles

**SEX**

Spayed Female

**AGE**

12 Years

**WEIGHT**

15.2 Pounds

**INTERPRETED BY**

Kathleen Sennello DVM,  
MS, Diplomate ACVIM  
(Small Animal Internal  
Medicine)

**IMAGING PERFORMED BY**

Amy Mayhew, LVT

**HOSPITAL NAME**

SVS Imaging MI

**REFERRING VET**

Wixom Family Pet  
Practice

**INVOICE**

39853

**DATE**

7/27/22

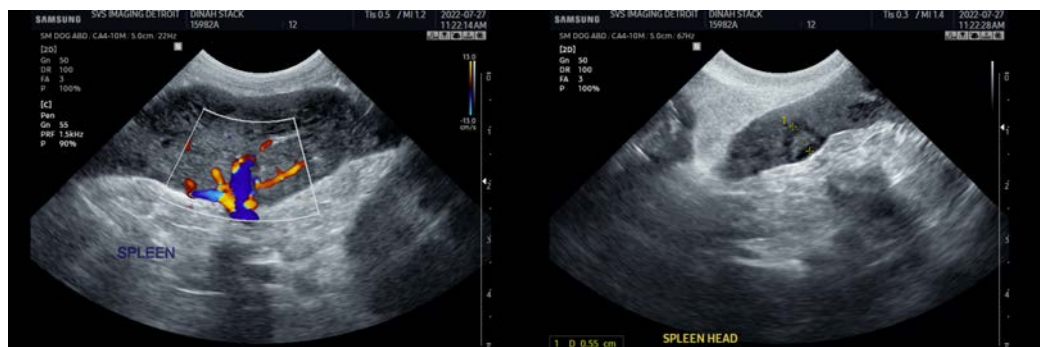
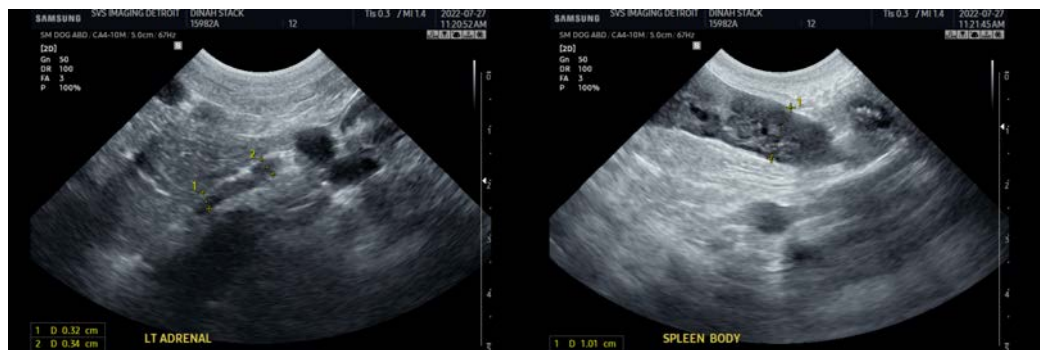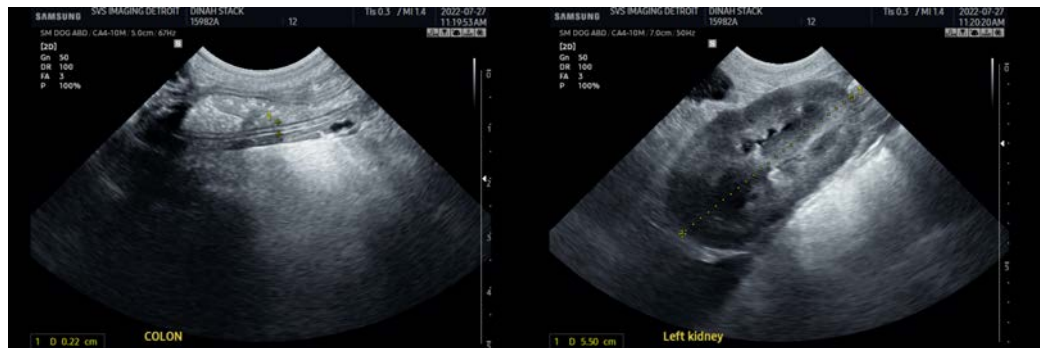**INTERPRETATION OF THE FINDINGS & FURTHER RECOMMENDATIONS**

The spleen is hypoechoic and very mottled with numerous, somewhat ill-defined hypo- and hyperechoic mass lesions/nodules that deform the splenic capsule. Recommend a fine needle aspirate of the spleen.

Consider three view thoracic radiographs to rule out concurrent thoracic disease/involvement.

Additionally, the liver is large and heterogeneous. Some of this could be consistent with a steroid hepatopathy. Because of the concern for an underlying neoplastic process, you could consider a fine needle aspirate. Additionally, reevaluation of the liver enzymes and the size of the liver in 4-6 weeks to see if there is improvement could be considered.

There are minimal changes observed associated with the gastrointestinal tract. Unfortunately, the clinical signs do not always correlate with ultrasonographic findings. Consider changing to a novel protein/hydrolyzed protein prescription diet, evaluating GI panel (Texas A&M) for a qualitative PLI, TLI, cobalamin and folate to look for evidence of exocrine pancreatic insufficiency, dysbiosis, pancreatitis, etc. Recommend chronic probiotic therapy. If symptoms are not improving despite discontinuation of the steroids and a diet change, you may consider obtaining GI biopsies. If cytology of the spleen is not diagnostic, you could consider surgical biopsies and splenectomy. Recommend a cardiac evaluation prior to general anesthesia.



**IMAGING PERFORMED BY**

SVS Mobile Imaging MI 734-637-7711  
svsimagingmi@gmail.com



**PATIENT**

Dinah Stack

**SPECIES**

Canine

**BREED**

Cavalier King Charles

**SEX**

Spayed Female

**AGE**

12 Years

**WEIGHT**

15.2 Pounds

**INTERPRETED BY**

Kathleen Sennello DVM,  
MS, Diplomate ACVIM  
(Small Animal Internal  
Medicine)

**IMAGING  
PERFORMED BY**

Amy Mayhew, LVT

**HOSPITAL NAME**

SVS Imaging MI

**REFERRING VET**

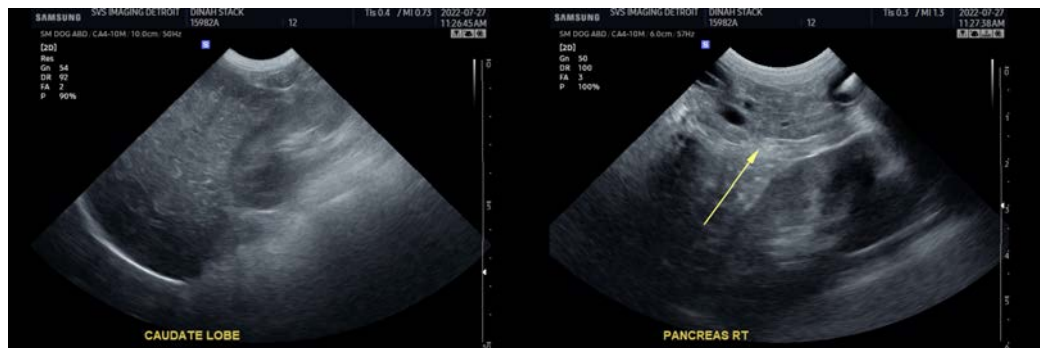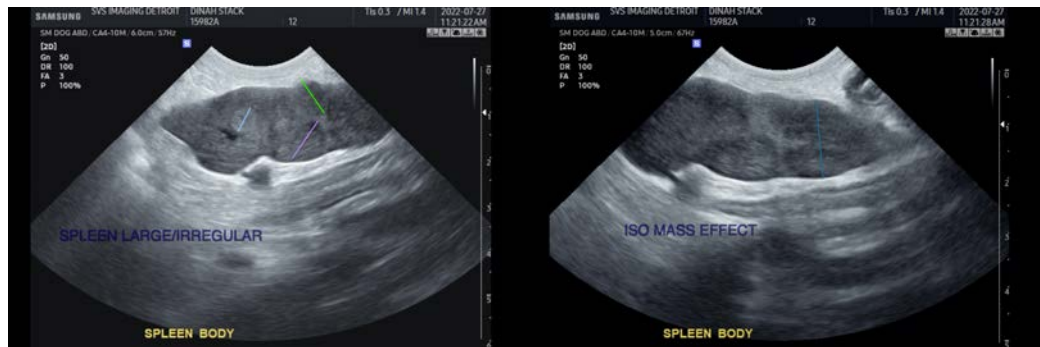
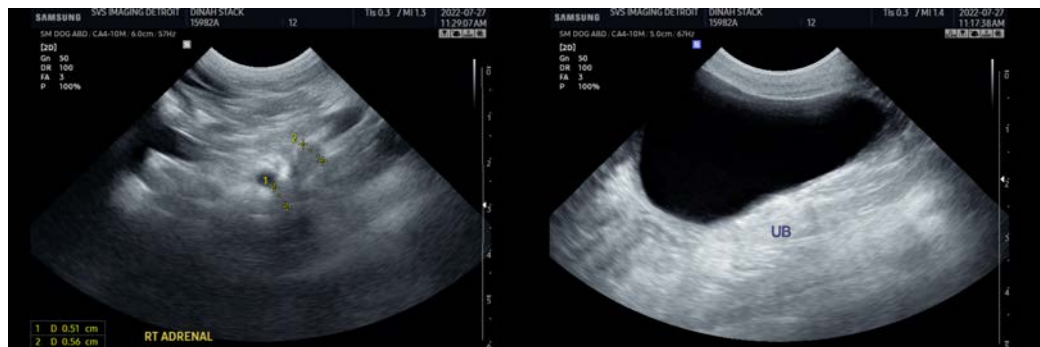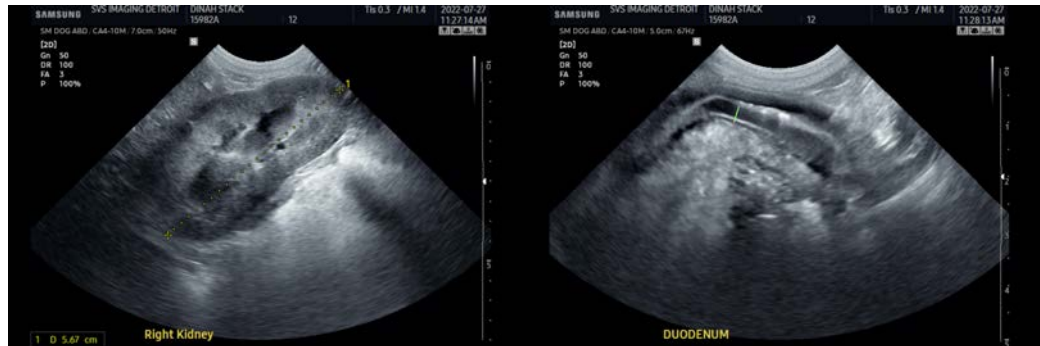Wixom Family Pet  
Practice

**INVOICE**

39853

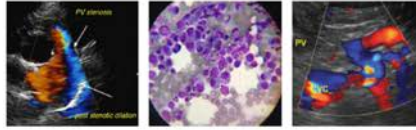
**DATE**

7/27/22



**IMAGING PERFORMED BY**

SVS Mobile Imaging MI 734 - 637 - 7711  
svsimagingmi@gmail.com



**PATIENT**

Dinah Stack

The information and recommendations provided are based on the images presented by the referring veterinarian/sonographer. No evaluation can be communicated regarding pathology that was not visible in the image/video clips provided.

**SPECIES**

Canine

Thank you for this referral. If the clinical or image interpretation does not parallel your findings or if I can be of any further assistance please contact me.

Kathleen Sennello DVM,MS, Diplomate ACVIM (Small animal Internal Medicine)

kathleen.sennello@sonopath.com

**BREED**

Cavalier King Charles

**SEX**

Spayed Female

**AGE**

12 Years

**WEIGHT**

15.2 Pounds

**INTERPRETED BY**

Kathleen Sennello DVM,  
MS, Diplomate ACVIM  
(Small Animal Internal  
Medicine)

**IMAGING  
PERFORMED BY**

Amy Mayhew, LVT

**HOSPITAL NAME**

SVS Imaging MI

**REFERRING VET**

Wixom Family Pet  
Practice

**INVOICE**

39853

**DATE**

7/27/22