



PATIENT

Tara Godwin

SPECIES

Canine

BREED

Lab X

SEX

Spayed Female

AGE

13 Years 5 Months

WEIGHT

42 Pounds

INTERPRETED BY

Kathleen Sennello DVM,
MS, Diplomate ACVIM
(Small Animal Internal
Medicine)

**IMAGING
PERFORMED BY**

Shari Reffi, CVT

HOSPITAL NAME

ACC Flanders

REFERRING VET

Dr. Hallihan

INVOICE

39835

DATE

7/26/22

PRESENTING CLINICAL SIGNS

Bloated abdomen since around Spring, vertigo episode in May. R/O Ascites and abd. mass vs other. Current meds: Trazodone 100mg 1.5 T before u/s. Just finished Doxycycline.
Abnormal PE/Chem/CBC/UA Results: Faint Anaplasma + (has hx of + Ana); BW 5/6/22-wbc 2.1, nrbc 3, Neut 57, Eos 13, Chol 359, abs. neu 1197, abs. lymph 483, ALT 161, ALKP 676, Creat 1.7, Ama. 1332, Pres Psl 573

ULTRASONOGRAPHIC EXAMINATION OF THE ABDOMEN

Urinary System

The urinary bladder is moderately distended with anechoic urine. The Bladder wall, trigone, ureteral papillae and visible urethra (to a depth of 2cm) appear normal with no evidence of wall thickening, mucosal irregularities, masses or cystic calculi.

The left kidney has a normal shape and size (5.42 cm). Overall echogenicity is normal with adequate corticomedullary distinction and a typical 1:3 cortex:medulla ratio. There is no evidence of perinephric inflammation or effusion. There is no evidence of pyelectasia, nephroliths, infarcts or hydroureter. Renal vasculature is normal.

The right kidney has a normal shape and size (5.28 cm). Overall echogenicity is normal with adequate corticomedullary distinction and a typical 1:3 cortex:medulla ratio. There is no evidence of perinephric inflammation or effusion. There is no evidence of pyelectasia, nephroliths, infarcts or hydroureter. Renal vasculature is normal.

Adrenal Glands

The left adrenal gland is normal in size measuring 0.69 cm at the caudal pole. It is observed in its normal position cranial to the left renal artery. It is normal in appearance (uniformly hypoechoic) and shape with no evidence of a mass effect.

The right adrenal gland is normal in size measuring 0.75 cm at the caudal pole. It is observed in its normal position between the cranial aspect of the right kidney and the caudal vena cava. It is normal in appearance (uniformly hypoechoic) and shape with no evidence of a mass effect.

Spleen

The spleen is subjectively normal in size, echotexture is homogenous, and the splenic capsule is smooth with no irregularities. The blood flow through the hilus and splenic parenchyma appears normal. No focal parenchymal abnormalities are visualized.

Liver

The liver is large in size, and normal in echogenicity with smooth peripheral margins. The parenchyma is heterogenous in echotexture with subtle, indistinct focal mottling. The visible portions of the vasculature and biliary tract appear normal. No focal nodules or cystic lesions are observed.

The gallbladder lumen is moderately distended. The wall of the gall bladder appears slightly irregular and thickened, measuring 0.51 cm. Luminal contents are primarily anechoic. The cystic and common bile ducts are normal/not visible.



PATIENT

Gastrointestinal

Tara Godwin

The stomach contains mild fluid. It measures at a normal thickness of <0.7cm with some variability due to the presence of rugal folds. The distinction of the gastric wall layers is adequate and there is no impression of reduced peristaltic activity. No masses or focal lesions were observed.

SPECIES

Canine

The visualized areas of duodenum, jejunum and ileum have a relatively uniform diameter with minimal fluid distension. Wall thickness is normal. Bowel loops follow a curvilinear path with distinct wall layering maintaining the typical 1:3 muscularis:mucosa layer ratio. The duodenum measured as normal (between 0.3-0.5cm in wall thickness) and the jejunum measured as normal (between 0.2-0.47cm.)

BREED

Lab X

Visualized peristalsis appears appropriate. There were no focal lesions consistent with obstruction or a mass effect observed.

SEX

Spayed Female

The ileocecal junction was visualized and exhibited normal intact wall layering and is subjectively of normal thickness. Sections of colon are visualized with formed fecal material and gas shadowing distally. There is no observed focal or generalized colon wall thickening or loss of layering.

Pancreas

AGE

13 Years 5 Months

The pancreas is normal and isoechoic to surrounding mesentery. There is no evidence of nodules or cystic lesions. There is no evidence of regional mesenteric inflammation or fluid.

Free Abdomen

WEIGHT

42 Pounds

Evaluation of the peritoneal cavity did not reveal any evidence of effusion, or subjective lymphadenomegaly. The Medial iliac nodes appear normal and there was no evidence of a caudal aortic thrombus at the bifurcation. The omentum is of normal uniform echogenicity.

ULTRASONOGRAPHIC FINDINGS

INTERPRETED BY

Kathleen Sennello DVM,
MS, Diplomate ACVIM
(Small Animal Internal
Medicine)

- Large, heterogeneous liver – The diffuse hepatic changes are non-specific and could be consistent with vacuolar hepatopathy, nodular hyperplasia, inflammatory/immune-mediated disease, fibrosis, extramedullary hematopoiesis, toxic hepatopathy (e.g., copper), infiltrative neoplasia (less likely) or other hepatopathy.
- Mildly thickened, irregular gallbladder wall – could be consistent with cholecystitis.

IMAGING PERFORMED BY

Shari Reffi, CVT

INTERPRETATION OF THE FINDINGS & FURTHER RECOMMENDATIONS

HOSPITAL NAME

ACC Flanders

No focal lesions are visualized within the hepatic parenchyma. This is a non-specific finding. These are my recommendations for a primary ALP elevation:

REFERRING VET

Dr. Hallihan

- Induction phenomena are the most common cause for an elevation in ALP. These are systemic illnesses that 'turn on' the liver enzyme. Causes of this include Cushing's disease, dental disease, arthritis, and numerous others. In many cases the exact cause is unclear but as long as ultrasound and bile acids tests are normal most patients do not have progressive changes in their liver. While liver biopsy is not routinely performed, vacuolar hepatopathy, is noted on most biopsies. This is often non-progressive but in rare cases can be more severe and lead to liver failure.

INVOICE

39835

- If signs of cushings disease are present recommend endocrine function testing to evaluate for cushings disease.
- Consider fine needle aspirate to rule out round cell neoplasia if this is a concern.

DATE

7/26/22



PATIENT

Tara Godwin

- If a cause for the ALP elevation is not identified: I recommend recheck general blood work every 6 months, ultrasound once per year, and bile acids test every 1-2 years based on other results. If the ALP continues to climb a biopsy could be considered.

SPECIES

Canine

- Consider long term use of denamarin, and monitoring for the signs of cushings developing.

BREED

Lab X

- A primary vacuolar hepatopathy can be breed related and is seen in Scottish Terriers, Schnauzers, Cocker spaniels etc..

SEX

Spayed Female

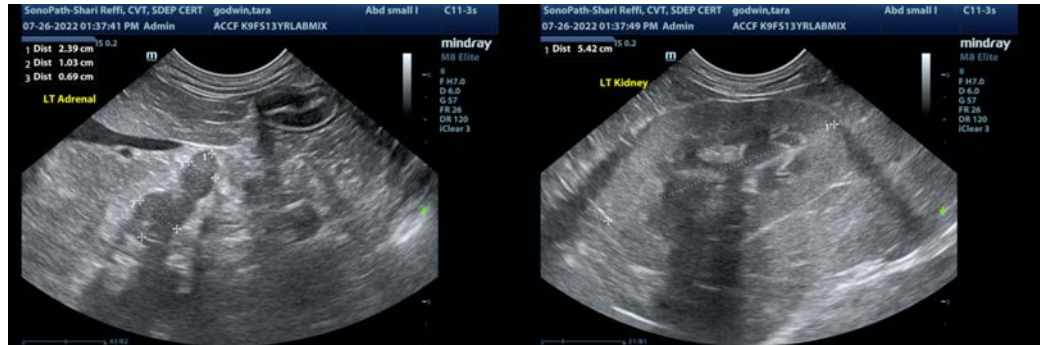
Additionally, the gallbladder wall is slightly irregular and thickened. This could be an indicator of cholecystitis, although there is no significant debris visualized within the gallbladder, which is somewhat unusual. Consider a course of Ursodiol (1-2 months) and continued monitoring of the gallbladder. If thickening persists or worsens, you could consider a course of antibiotics as well.

AGE

13 Years 5 Months

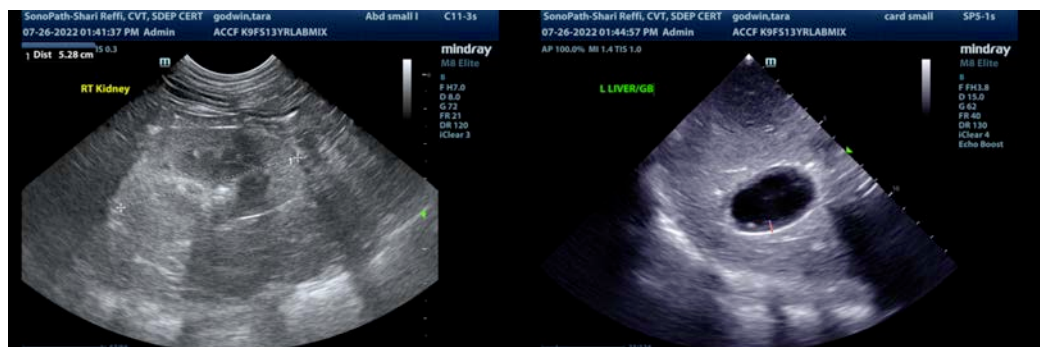
WEIGHT

42 Pounds



INTERPRETED BY

Kathleen Sennello DVM, MS, Diplomate ACVIM (Small Animal Internal Medicine)

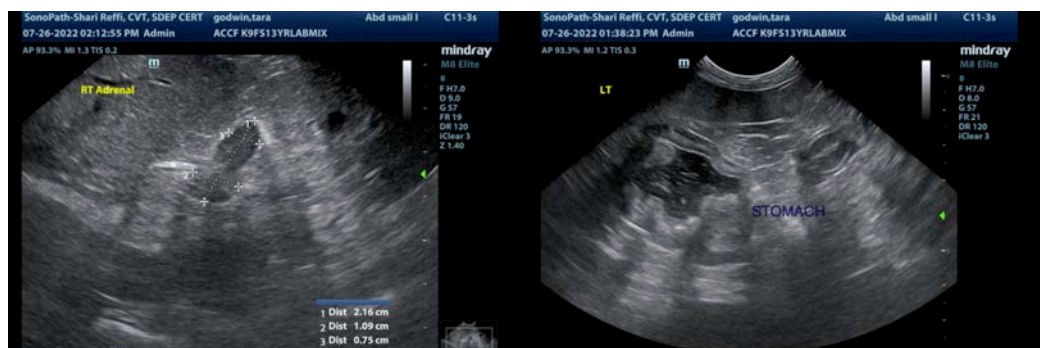


IMAGING PERFORMED BY

Shari Reffi, CVT

HOSPITAL NAME

ACC Flanders



REFERRING VET

Dr. Hallihan

INVOICE

39835

DATE

7/26/22



PATIENT

Tara Godwin

SPECIES

Canine

BREED

Lab X

SEX

Spayed Female

AGE

13 Years 5 Months

WEIGHT

42 Pounds

INTERPRETED BY

Kathleen Sennello DVM,
MS, Diplomate ACVIM
(Small Animal Internal
Medicine)

**IMAGING
PERFORMED BY**

Shari Reffi, CVT

HOSPITAL NAME

ACC Flanders

REFERRING VET

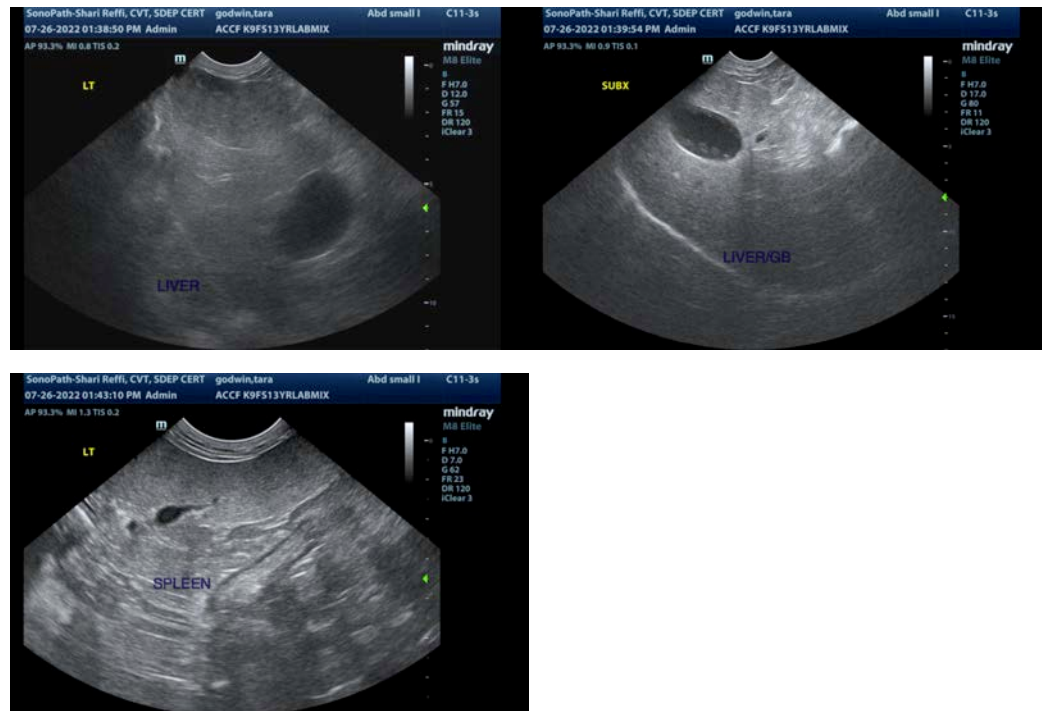
Dr. Hallihan

INVOICE

39835

DATE

7/26/22



The information and recommendations provided are based on the images presented by the referring veterinarian/sonographer. No evaluation can be communicated regarding pathology that was not visible in the image/video clips provided.

Thank you for this referral. If the clinical or image interpretation does not parallel your findings or if I can be of any further assistance please contact me.

Kathleen Sennello DVM,MS, Diplomate ACVIM (Small animal Internal Medicine)

kathleen.sennello@sonopath.com