

**PATIENT**

Jo Jo Wall

SPECIES

Feline

BREED

DSH

SEX

Spayed Female

AGE

13 Years 7 Months

WEIGHT

9 Pounds

INTERPRETED BYKathleen Sennello DVM,
MS, Diplomate ACVIM
(Small Animal Internal
Medicine)**IMAGING PERFORMED BY**

Amy Mayhew, LVT

HOSPITAL NAME

SVS Imaging MI

REFERRING VETWixom Family Pet
Practice**INVOICE**

39849

DATE

7/26/22

PRESENTING CLINICAL SIGNS

Current Medications: Royal Canin Urinary SO / Hydrolyzed Protein dry Gabapentin 100 mg premedication 7/19/22 - FlortiFlora 1 packet SID, Metronidazole 100 mg/ml 0.4 ml BID x 7 days
 Patient History: Previous history of chronic vomiting. Greatly improved with hydrolyzed protein diet. Chronic diarrhea. 7/19/22 Fecal - NPS. Weight loss 0.46# since January. Performing CBC / Chemistry / UA / T4 in hospital day of ultrasound.
 Abnormal PE/Chem/CBC/UA Results: Abnormal Examination Findings: Moderate diffuse calculus. Mild gingivitis. Abdominal palpation is unremarkable.

ULTRASONOGRAPHIC EXAMINATION OF THE ABDOMEN**Urinary System**

The urinary bladder is moderately distended with anechoic urine. The Bladder wall, trigone, ureteral papillae and visible urethra (to a depth of 2cm) appear normal with no evidence of wall thickening, mucosal irregularities, masses or cystic calculi.

The left kidney has a normal shape and size (3.46 cm). Overall echogenicity is normal with adequate corticomedullary distinction and a typical 1:3 cortex:medulla ratio. There is no evidence of perinephric inflammation or effusion. There is no evidence of pyelectasia, nephroliths, infarcts or hydroureter. Renal vasculature is normal.

The right kidney has a normal shape and size (3.49 cm). Overall echogenicity is normal with adequate corticomedullary distinction and a typical 1:3 cortex:medulla ratio. There is no evidence of perinephric inflammation or effusion. There is no evidence of pyelectasia, nephroliths, infarcts or hydroureter. Renal vasculature is normal.

Adrenal Glands

The left adrenal gland is normal in size measuring 0.37 cm at the caudal pole. It is observed in its normal position cranial to the left renal artery. It is normal in appearance (uniformly hypoechoic) and shape with no evidence of a mass effect.

The right adrenal gland is normal in size measuring 0.35 cm at the caudal pole. It is observed in its normal position between the cranial aspect of the right kidney and the caudal vena cava. It is normal in appearance (uniformly hypoechoic) and shape with no evidence of a mass effect.

Spleen

The spleen is subjectively normal in size, echotexture is homogenous, and the splenic capsule is smooth with no irregularities. The blood flow through the hilus and splenic parenchyma appears normal. No focal parenchymal abnormalities are visualized.

Liver

The liver is subjectively normal in size, and echogenicity with smooth peripheral margins. The parenchyma is homogenous echotexture. The visible portions of the vasculature and biliary tract appear normal. No focal nodules or cystic lesions are observed.

The gallbladder lumen is moderately distended. The wall of the gall bladder is not thickened and has a smooth mucosal surface. Luminal contents are primarily anechoic. The cystic and common bile ducts are normal/not visible.

IMAGING PERFORMED BY

SVS Mobile Imaging MI 734 - 637 - 7711
svsimagingmi@gmail.com

**PATIENT**

Jo Jo Wall

SPECIES

Feline

BREED

DSH

SEX

Spayed Female

AGE

13 Years 7 Months

WEIGHT

9 Pounds

INTERPRETED BY

Kathleen Sennello DVM,
MS, Diplomate ACVIM
(Small Animal Internal
Medicine)

IMAGING PERFORMED BY

Amy Mayhew, LVT

HOSPITAL NAME

SVS Imaging MI

REFERRING VET

Wixom Family Pet
Practice

INVOICE

39849

DATE

7/26/22

Gastrointestinal

The stomach contains minimal luminal contents. It measures at a normal thickness of <0.36cm with some variability due to the presence of rugal folds. The distinction of the gastric wall layers is adequate and there is no impression of reduced peristaltic activity. No masses or focal lesions were observed.

The visualized areas of duodenum, jejunum and ileum have a relatively uniform diameter with minimal fluid distension. Wall thickness is normal. Bowel loops follow a curvilinear path with distinct wall layering maintaining the typical 1:3 muscularis:mucosa layer ratio. Jejunum wall measured 0.30 cm. Duodenum wall measured 0.26 cm. Visualized peristalsis appears appropriate. There were no focal lesions consistent with obstruction or a mass effect observed.

The ileocecal junction was visualized and exhibited normal intact wall layering and is subjectively of normal thickness. Sections of colon are visualized with formed fecal material and gas shadowing distally. There is no observed focal or generalized colon wall thickening or loss of layering.

Pancreas

The pancreas is normal and isoechoic to surrounding mesentery. There is no evidence of nodules or cystic lesions. There is no evidence of regional mesenteric inflammation or fluid.

Free Abdomen

Evaluation of the peritoneal cavity did not reveal any evidence of effusion. There are some prominent mesenteric lymph nodes visualized, mostly in the cranial abdomen. The pancreaticoduodenal lymph node measures 0.93 cm. Additional mesenteric lymph nodes in the right cranial abdomen are 0.77 cm and 0.53 cm. A small cluster of lymph nodes near the ileocecal junction are visualized at 0.36, 0.27, and 0.22 cm. The omentum is generally mildly hyperechoic around these lymph nodes.

ULTRASONOGRAPHIC FINDINGS

- Mild mesenteric lymphadenopathy – The prominent abdominal lymph nodes are most consistent with reactive lymphadenitis or lymphoid hyperplasia. Neoplastic infiltration is considered less likely.

INTERPRETATION OF THE FINDINGS & FURTHER RECOMMENDATIONS

No focal gastrointestinal lesions are visualized to explain the chronic diarrhea reported. There does appear to be a generalized lymphadenopathy present, which is likely an indicator of generalized inflammation. If possible, consider a fine needle aspirate of a mesenteric lymph node to try and rule out round cell neoplasia. Unfortunately, there are many causes for chronic diarrhea that cannot be diagnosed by ultrasound alone. Consider such differentials as food allergy/dietary sensitivity (you are already using a hypoallergenic diet), chronic pancreatitis, GI parasitism, infectious causes of diarrhea, exocrine pancreatic insufficiency, IBD, and less likely intestinal neoplasia. Consider the following:

- Consider a GI panel to Texas A&M for a qualitative fPLI, TLI, cobalamin and folate to further evaluate the pancreas and small intestine.
- Recommend chronic probiotic therapy.
- If symptoms persist and lymph node cytology is not helpful, consider obtaining GI biopsies, as it is possible that you are improving symptoms with your current diet, but additional therapy may be recommended to further improve the situation.
- Consider three view thoracic radiographs to rule out concurrent thoracic disease/involvement.

IMAGING PERFORMED BY

SVS Mobile Imaging MI 734-637-7711
svsimagingmi@gmail.com



PATIENT

Jo Jo Wall

SPECIES

Feline

BREED

DSH

SEX

Spayed Female

AGE

13 Years 7 Months

WEIGHT

9 Pounds

INTERPRETED BY

Kathleen Sennello DVM,
MS, Diplomate ACVIM
(Small Animal Internal
Medicine)

**IMAGING
PERFORMED BY**

Amy Mayhew, LVT

HOSPITAL NAME

SVS Imaging MI

REFERRING VET

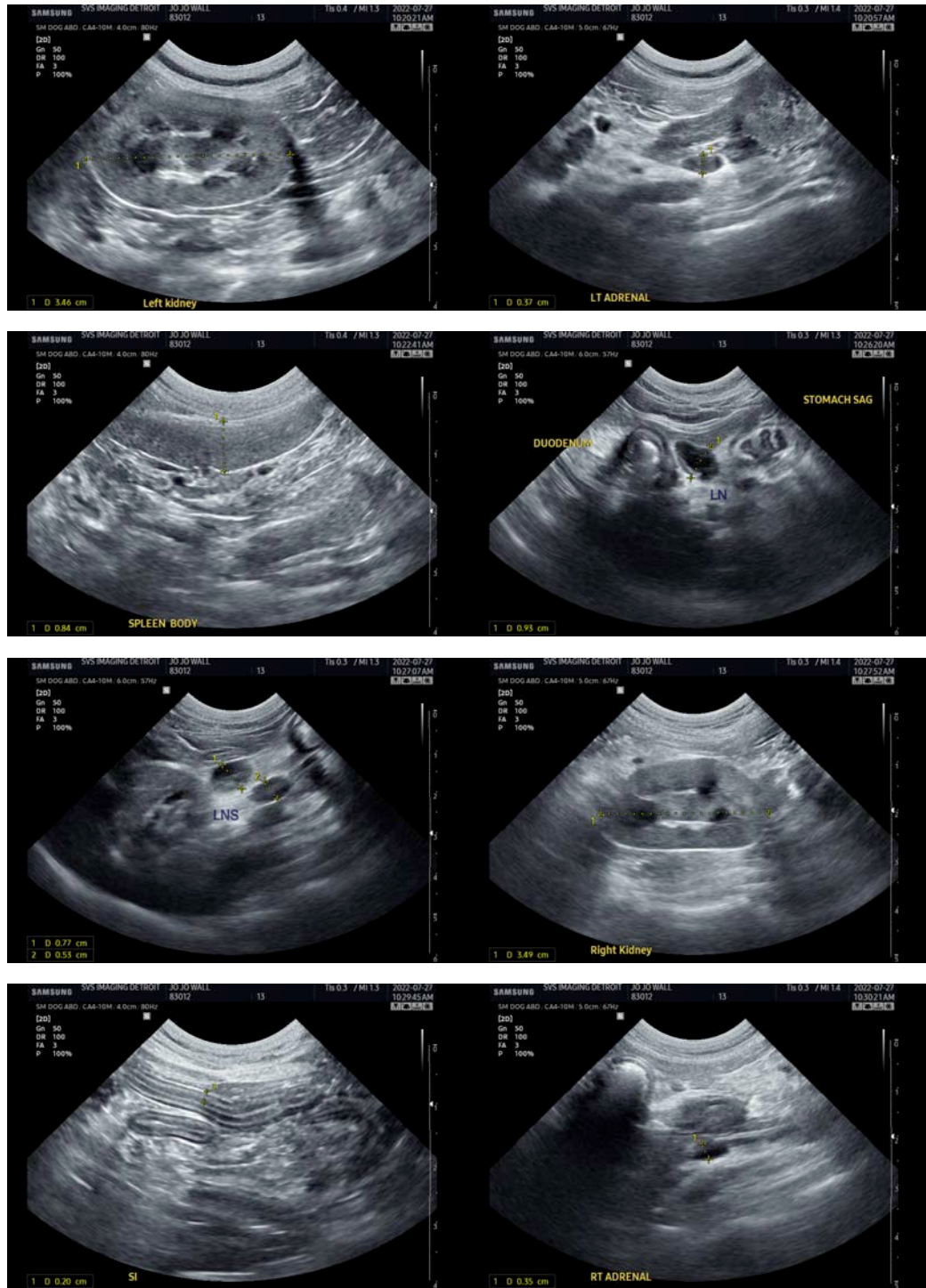
Wixom Family Pet
Practice

INVOICE

39849

DATE

7/26/22



IMAGING PERFORMED BY

SVS Mobile Imaging MI 734-637-7711
svsimagingmi@gmail.com



PATIENT

Jo Jo Wall

SPECIES

Feline

BREED

DSH

SEX

Spayed Female

AGE

13 Years 7 Months

WEIGHT

9 Pounds

INTERPRETED BY

Kathleen Sennello DVM,
MS, Diplomate ACVIM
(Small Animal Internal
Medicine)

**IMAGING
PERFORMED BY**

Amy Mayhew, LVT

HOSPITAL NAME

SVS Imaging MI

REFERRING VET

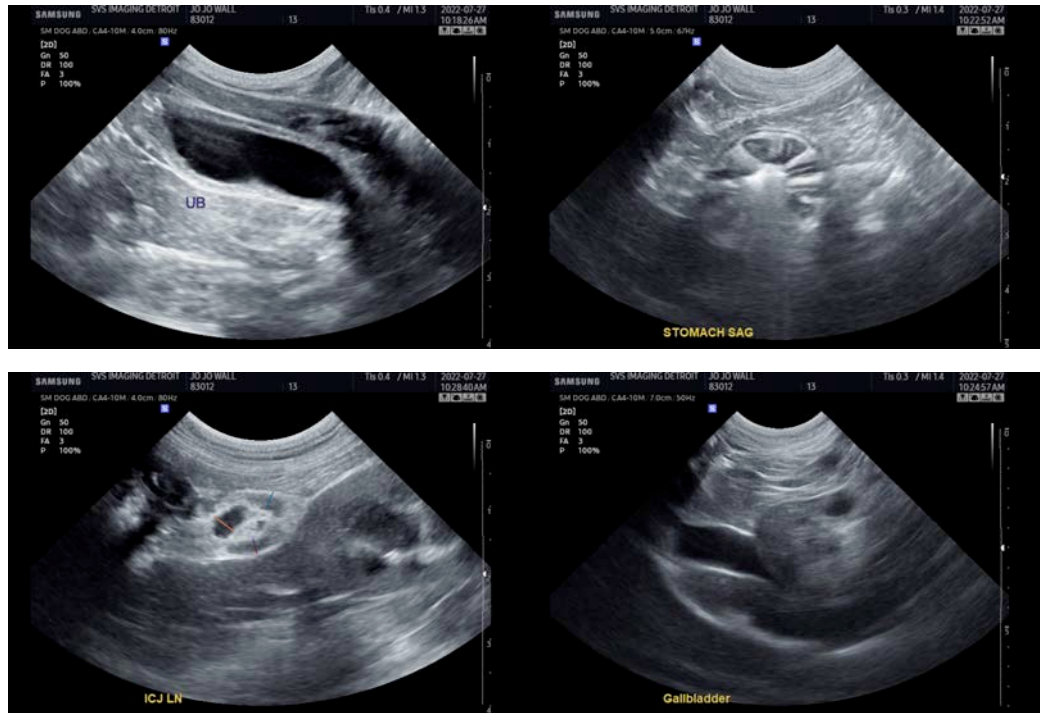Wixom Family Pet
Practice

INVOICE

39849

DATE

7/26/22



The information and recommendations provided are based on the images presented by the referring veterinarian/sonographer. No evaluation can be communicated regarding pathology that was not visible in the image/video clips provided.

Thank you for this referral. If the clinical or image interpretation does not parallel your findings or if I can be of any further assistance please contact me.

Kathleen Sennello DVM,MS, Diplomate ACVIM (Small animal Internal Medicine)

kathleen.sennello@sonopath.com