

IMAGING PERFORMED BY

IntraPet.com



SonoPath

Clinical Sonography & Telectology

EDUCATIONAL TELECONSULTATION SERVICES™

1-800-838-4268 info@sonopath.com SonoPath.com

DATE PRESENTING CLINICAL SIGNS

7/26/22 Known DM. Uncontrolled DM, hypoglycemia, mass on palpation.

PATIENT Current Medications: Dextrose, Amoxicillin, Denamarin, Prozac.
Lab Results: See attached.

Bud Murray Date of Previous IntraPet Ultrasound: No previous.
Sedation: Not required to complete full diagnostic ultrasound.
Stat Report: Not requested.

SPECIES

Feline

ULTRASONOGRAPHIC EXAMINATION OF THE ABDOMEN

BREED

Norwegian Forest

Urinary System

The urinary bladder is moderately distended with anechoic urine. The Bladder wall, trigone, ureteral papillae and visible urethra (to a depth of 2cm) appear normal with no evidence of wall thickening, mucosal irregularities, masses or cystic calculi.

SEX

Neutered Male

The left kidney has a normal shape and size (4.59 cm) with a 0.61 cm cortical cyst. Overall echogenicity is slightly hyperechoic with poor corticomedullary distinction and a typical 1:3 cortex:medulla ratio. There is no evidence of perinephric inflammation or effusion. There is no evidence of pyelectasia, nephroliths, infarcts or hydronephrosis. Renal vasculature is normal.

AGE

4/18/11

The right kidney has a normal shape and size. Overall echogenicity is normal with adequate corticomedullary distinction and a typical 1:3 cortex:medulla ratio. There is no evidence of perinephric inflammation or effusion. There is no evidence of pyelectasia, nephroliths, infarcts or hydronephrosis. Renal vasculature is normal.

WEIGHT

15.6 Pounds

INTERPRETED BY

Kathleen Sennello DVM,
MS, Diplomate ACVIM
(Small Animal Internal
Medicine)

Adrenal Glands

The left adrenal gland is normal in size measuring 0.50 cm at the caudal pole. It is observed in its normal position cranial to the left renal artery. It is somewhat abnormal in appearance in that there is some hyperechoic shadowing areas in the parenchyma, most consistent with benign mineralization.

The right adrenal gland is normal in size measuring 0.52 cm at the caudal pole. It is observed in its normal position between the cranial aspect of the right kidney and the caudal vena cava. It is somewhat abnormal in appearance in that there is some hyperechoic shadowing areas in the parenchyma, most consistent with benign mineralization.

IMAGING PERFORMED BY

Rachel Brilhart RDMS

Spleen

The spleen is subjectively normal in size (1.0 cm), echotexture is homogenous, and the splenic capsule is smooth with no irregularities. The blood flow through the hilus and splenic parenchyma appears normal. No focal parenchymal abnormalities are visualized.

HOSPITAL NAME

Animal Emergency
Hospital

Liver

The liver is subjectively normal in size, and echogenicity with smooth peripheral margins. The parenchyma is heterogenous in echotexture with subtle, indistinct focal mottling. The visible portions of the vasculature and biliary tract appear normal. There are hyperechoic shadowing foci visualized within the liver, most consistent with intrahepatic biliary stones.

REFERRING VET

Dr. Saubier

INVOICE

39802

The gallbladder lumen is moderately distended. The wall of the gall bladder is not thickened and has a smooth mucosal surface. Luminal contents are primarily anechoic. The bile duct is slightly prominent and visible, but does not appear overtly dilated.

Gastrointestinal

The stomach contains minimal luminal contents. It measures at a normal thickness of <0.36cm with some variability due to the presence of rugal folds. The distinction of the gastric wall layers is adequate and there is no impression of reduced peristaltic activity. No masses or focal lesions were observed.

The visualized areas of duodenum, jejunum and ileum have a relatively uniform diameter with minimal fluid distension. Wall thickness is normal. Bowel loops follow a curvilinear path with distinct wall layering maintaining the typical 1:3 muscularis:mucosa layer ratio. The duodenum measured as normal (between 0.13-0.38cm in wall thickness) and the jejunum measured as normal (between 0.15-0.36cm.) Jejunum wall measured 0.24 cm. Visualized peristalsis appears appropriate. There were no focal lesions consistent with obstruction or a mass effect observed.

The ileocecal junction was visualized and exhibited normal intact wall layering and is subjectively of normal thickness. Sections of colon are visualized with formed fecal material and gas shadowing distally. There is no observed focal or generalized colon wall thickening or loss of layering.

Pancreas

The pancreas is large and hypoechoic to surrounding mesentery. There are numerous ill-defined, hyperechoic nodules visualized throughout the pancreatic parenchyma. It is generally irregular, and there is evidence of mild regional mesenteric inflammation, consistent with mild/moderate pancreatitis.

Free Abdomen

Evaluation of the peritoneal cavity did not reveal any evidence of effusion, or subjective lymphadenomegaly. The Medial iliac nodes appear normal and there was no evidence of a caudal aortic thrombus at the bifurcation. The omentum is of normal uniform echogenicity.

PRIMARY FINDINGS

- Large, irregular, prominent and nodular pancreas with mild/moderate surrounding inflammation – most consistent with chronic pancreatitis and possible nodular hyperplasia or pancreatic neoplasia. Recommend a fine needle aspirate.
- Heterogeneous liver with intrahepatic biliary mineralizations – Hepatic changes are non-specific and could be consistent with inflammation/infection (cholangiohepatitis), infiltrative neoplasia, lipodosis or other hepatopathy.

SECONDARY FINDINGS

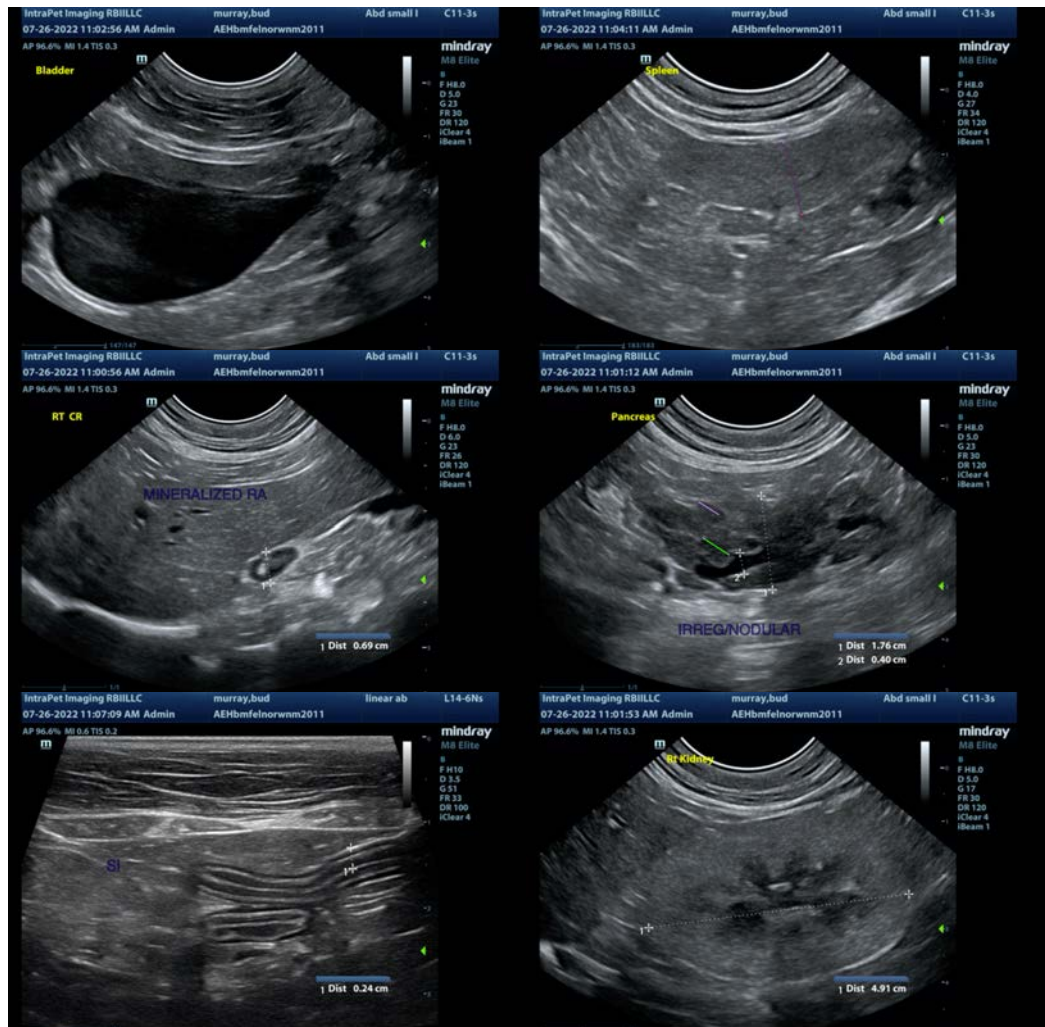
- Decreased corticomedullary distinction in both kidneys – The bilateral renal findings are consistent with age-related change.
- Bilateral adrenal mineralizations – This can be a normal finding in older cats.

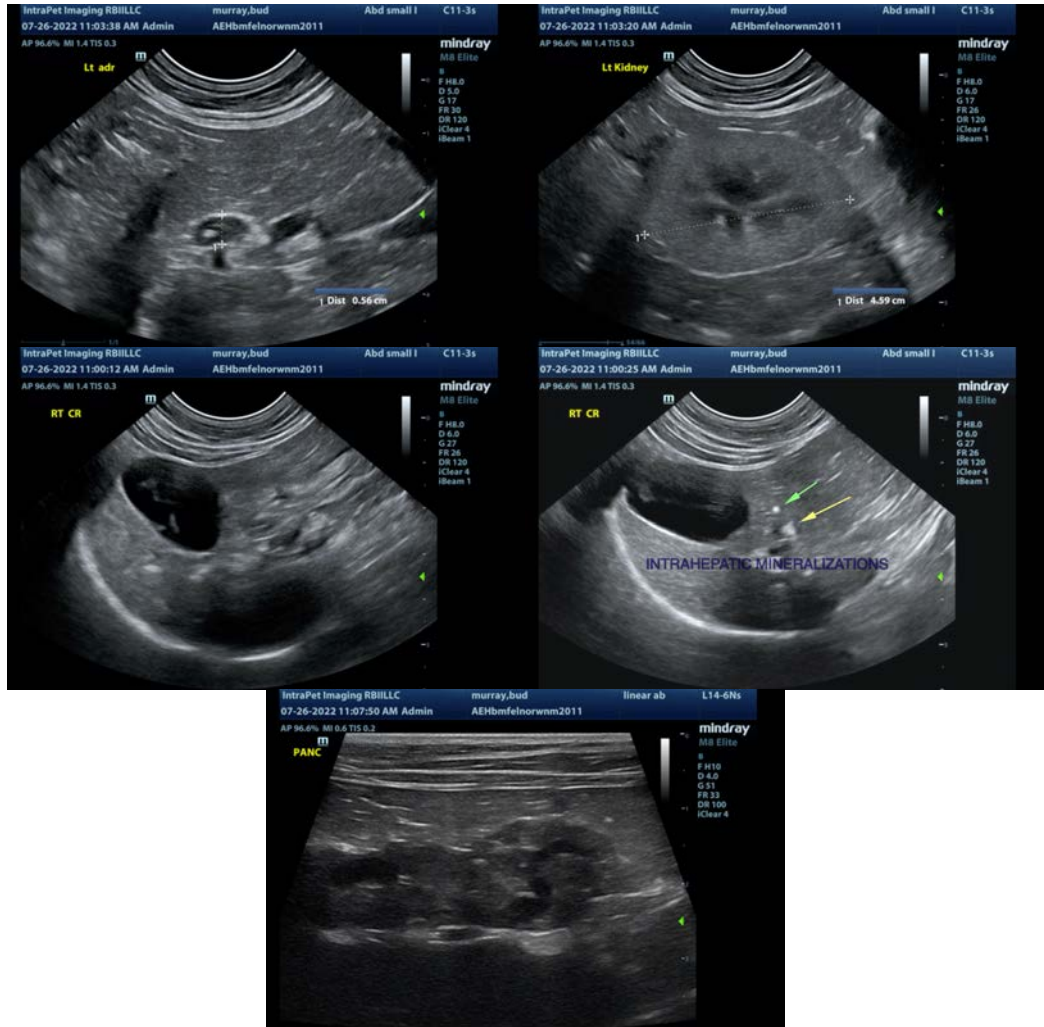
INTERPRETATION OF THE FINDINGS & FURTHER RECOMMENDATIONS

The pancreas is very irregular and hypoechoic with ill-defined nodules and a prominent pancreatic duct. These changes are most consistent with chronic pancreatic inflammation +/- current pancreatic inflammation. Additionally, a neoplastic change cannot be ruled out. Consider a fine needle aspirate, although nodular hyperplasia is thought most likely. Additionally, the liver appears somewhat heterogeneous with small intrahepatic biliary stones. The concurrent involvement of the pancreas and liver could be an indicator of underlying Triaditis, although the small intestinal changes are mild.

- Consider a novel protein/hydrolyzed protein prescription diet.
- Recommend treatment for pancreatitis.
- Recommend a GI panel to Texas A&M for a qualitative fPLI, TLI, cobalamin and folate to further evaluate the pancreas and small intestine.
- Recommend a fine needle aspirate of the spleen.
- Consider three view thoracic radiographs to rule out concurrent thoracic disease/involvement.

The changes in the kidneys are non-specific and likely age related. Recommend blood pressure evaluation, urinalysis and culture.





The information and recommendations provided are based on the images presented by the referring veterinarian/sonographer. No evaluation can be communicated regarding pathology that was not visible in the image/video clips provided.

Thank you for this referral. If the clinical or image interpretation does not parallel your findings or if I can be of any further assistance please contact me.

Kathleen Sennello DVM,MS, Diplomate ACVIM (Small animal Internal Medicine)
 kathleen.sennello@sonopath.com