

**DATE PRESENTING CLINICAL SIGNS**

7/22/22

Dog has been bleeding through his urine with chunks of blood coming out for going on three days. ATO- in hospital - 3rd day of urinating blood with "chunks" - Hx of dry cough prior- looks like he's trying to vomit, nothing comes out few days - Yesterday morning- vomiting food, partially digested - No diet change- receives Purina dry + water- digests ok; when o gives wet food has diarrhea- tries to avoid; picky eater but has been eating; only new thing- pupperoni treat for the last 1-2 weeks - Hx of eating the weeds- previously sprayed with a chemical; eats grass - Urinates outside the front yard - Vomited once - Very lethargic - Weight loss- o concerned- feeling bones more - Medical hx: bad teeth- O declined removal of teeth; had cleaning once before - No hx of heart disease, kidney disease, uti - no hx of rat poison- no exposure

PATIENT

Wicked Ortega

SPECIES

Canine

BREED

Shih Tzu X

Current Medications: None listed.
Date of Previous IntraPet Ultrasound: No previous.
Sedation: Not required to complete full diagnostic ultrasound.
Stat Report: Not requested.

SEX

Neutered Male

ULTRASONOGRAPHIC EXAMINATION OF THE ABDOMEN**AGE**

4/14/09

Urinary System

The urinary bladder is significantly distended with anechoic urine. The Bladder wall largely appears of normal thickness. There is a focal region visualized with a hyperechoic, rounded mass effect with lack of color flow that has the characteristics most consistent with a clot, but it does not appear mobile with agitation, so an underlying mass effect cannot be excluded. The mass effect measures 1.7 cm x 0.96 cm. In the area of the trigone, ureteral papillae and proximal urethra there is a foley catheter evident with an insufflated bulb. No calculi are visualized.

WEIGHT

18.7 Pounds

The prostate is not clearly seen, largely due to the placement of the foley catheter.

INTERPRETED BY

Kathleen Sennello DVM,
MS, Diplomate ACVIM
(Small Animal Internal
Medicine)

The left kidney has a normal shape and size (4.82 cm). Overall echogenicity is normal with adequate corticomedullary distinction and a typical 1:3 cortex:medulla ratio. There is no evidence of perinephric inflammation or effusion. There is no evidence of pyelectasia, nephroliths, infarcts or hydroureter. Renal vasculature is normal.

IMAGING PERFORMED BY

Andi Parkinson RDMS

The right kidney is large in size (5.1 cm) and very abnormal in shape in that there is a large, mixed echogenic, partially cavitated mass effect that is effacing most of the normal renal architecture. This mass effect measures 5.43 cm x 4.32 cm.

HOSPITAL NAME

Animal Emergency
Hospital

Adrenal Glands

The left adrenal gland is normal in size measuring 0.50 cm at the caudal pole. It is observed in its normal position cranial to the left renal artery. It is normal in appearance (uniformly hypoechoic) and shape with no evidence of a mass effect.

Visualization of the right adrenal gland is obscured by the right renal mass.

REFERRING VET

Dr. Kalwa

Spleen

The spleen is subjectively normal in size, echotexture is homogenous, and the splenic capsule is smooth with no irregularities. The blood flow through the hilus and splenic parenchyma appears normal. No focal parenchymal abnormalities are visualized.

INVOICE

39781

Liver

The liver is subjectively normal in size, and echogenicity with smooth peripheral margins. The parenchyma is homogenous echotexture. The visible portions of the vasculature and biliary tract appear normal. No focal nodules or cystic lesions are observed.

The gall bladder lumen is moderately distended. The wall of the gall bladder is not thickened and has a smooth mucosal surface. There is a moderate amount of non-organized echogenic debris. The cystic and common bile ducts are normal/not visible.

Gastrointestinal

The stomach contains minimal luminal contents. It measures at a normal thickness of <0.7cm with some variability due to the presence of rugal folds. The distinction of the gastric wall layers is adequate and there is no impression of reduced peristaltic activity. No masses or focal lesions were observed.

The visualized areas of duodenum, jejunum and ileum have a relatively uniform diameter with minimal fluid distension. Wall thickness is normal. Bowel loops follow a curvilinear path with distinct wall layering maintaining the typical 1:3 muscularis:mucosa layer ratio. The duodenum measured as normal (between 0.3-0.5cm in wall thickness) and the jejunum measured as normal (between 0.2-0.47cm.) Visualized peristalsis appears appropriate. There were no focal lesions consistent with obstruction or a mass effect observed.

The ileocecal junction was visualized and exhibited normal intact wall layering and is subjectively of normal thickness. Sections of colon are visualized with formed fecal material and gas shadowing distally. There is no observed focal or generalized colon wall thickening or loss of layering.

Pancreas

The pancreas is normal and isoechoic to surrounding mesentery. There is no evidence of nodules or cystic lesions. There is no evidence of regional mesenteric inflammation or fluid.

Free Abdomen

There is a scant amount of free abdominal fluid. The mesentery is diffusely hyperechoic, particularly in the region of the right kidney, and there is no significant lymphadenopathy noted.

ULTRASONOGRAPHIC FINDINGS

- Large, heterogeneous, partially cavitated right renal mass – likely the source of the hematuria reported. Primary differentials would include renal carcinoma, hemangiosarcoma, other. Benign differentials are possible.
- Hyperechoic tissue visualized adhered to the urinary bladder wall – This has the characteristics most consistent with a clot. An underlying mass effect cannot be excluded.
- Gallbladder debris – The significance of the aggregated gallbladder sludge is unclear. This could represent an early mucocele, cholestasis, or may be secondary to fasting.

INTERPRETATION OF THE FINDINGS & FURTHER RECOMMENDATIONS

There is a large mass effect on the right kidney, obliterating all of the normal architecture. This is the likely source of the hematuria reported. Additionally, there is abnormal tissue in the urinary bladder, most consistent with a clot, but a small mass effect cannot be excluded as a possibility.

Consider three view thoracic radiographs to rule out concurrent thoracic disease/involvement.

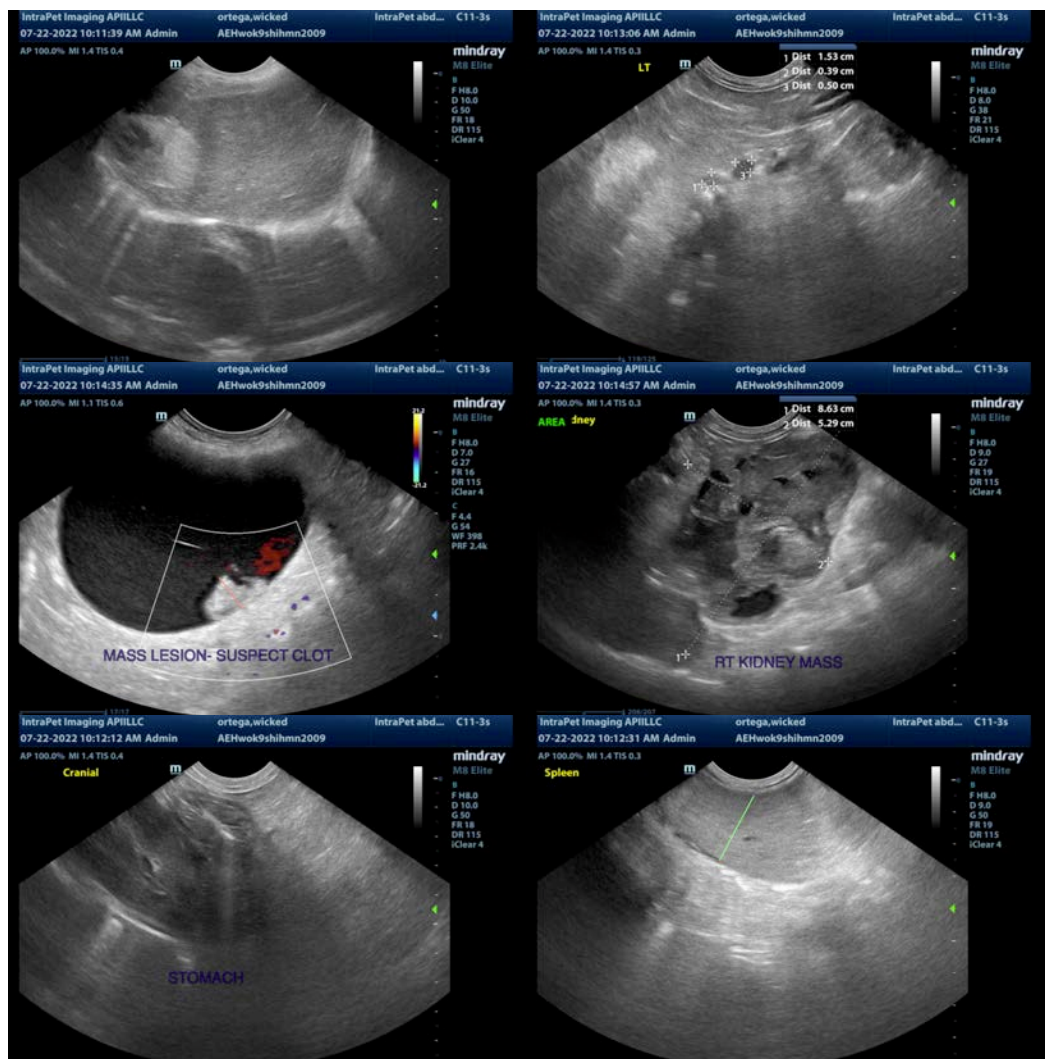
Options moving forward include the possibility of a contrast CT scan to further evaluate for evidence of metastasis and the extent of the involvement of the mass effect. A fine needle aspirate could be considered. There is some small risk for hemorrhage associated with this mass effect. Recommend a blood pressure and coagulation parameter before considering this. Alternately, a nephrectomy could be performed for both

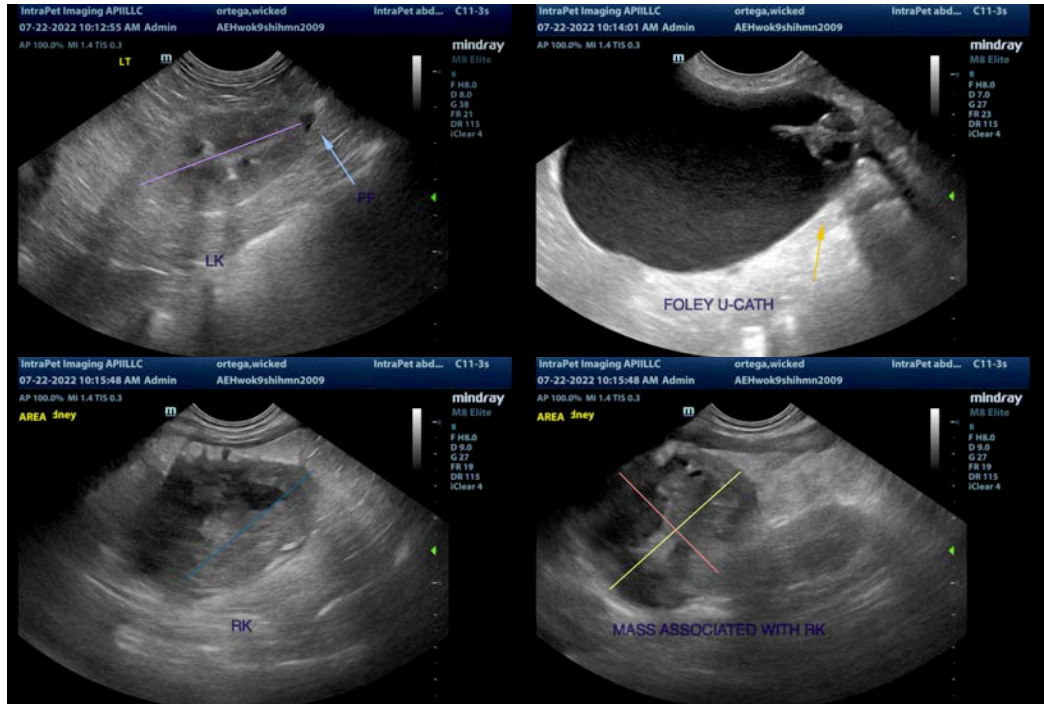
diagnostic and therapeutic purposes with gross evaluation and biopsies of any abnormal tissue.

Recommend urinalysis and culture.

Consider reevaluation of the urinary bladder in 48-72 hours to see if the appearance of the mass effect has changed.

In the history, the owner describes possible bony pain. If any discomfort can be localized, recommend radiographs, as bony metastasis is a possibility.





The information and recommendations provided are based on the images presented by the referring veterinarian/sonographer. No evaluation can be communicated regarding pathology that was not visible in the image/video clips provided.

Thank you for this referral. If the clinical or image interpretation does not parallel your findings or if I can be of any further assistance please contact me.

Kathleen Sennello DVM,MS, Diplomate ACVIM (Small animal Internal Medicine)
kathleen.sennello@sonopath.com