

IMAGING PERFORMED BY

IntraPet.com



SonoPath

Clinical Sonography & Telecytology

EDUCATIONAL TELECONSULTATION SERVICES™

1-800-838-4268 info@sonopath.com SonoPath.com

DATE PRESENTING CLINICAL SIGNS

7/22/22

Was having loose bowels (soft) a few days ago. Tuesday at 5pm, she began vomiting--first was food, then liquid, foamy, saliva/mucus. This am, vomited 3x. Went to rDVM (had appt for other dog and took her in). Does not go to dog park, or lick standing water. Owners did have yard waste bags she was drinking from, but otherwise, nothing abnormal.

PATIENT

Finley Nelson

SPECIES

Canine

BREED

German Shepherd

SEX

Spayed Female

AGE

12/5/15

WEIGHT

53.7 Pounds

INTERPRETED BY

Kathleen Sennello DVM,
MS, Diplomate ACVIM
(Small Animal Internal
Medicine)

IMAGING PERFORMED BY

Andi Parkinson RDMS

HOSPITAL NAME

Animal Emergency
Hospital

REFERRING VET

Dr. Goessling

INVOICE

39767

Current Medications: Buprenorphine, Maropitant, Ampicilin (after specimen collection for leptospirosis PCR).

Lab Results: See attached.

Date of Previous IntraPet Ultrasound: No previous.

Sedation: Not required to complete full diagnostic ultrasound.

Stat Report: Not requested.

ULTRASONOGRAPHIC EXAMINATION OF THE ABDOMEN

Urinary System

The urinary bladder was not clearly visualized.

The prostate was not clearly visualized.

The left kidney has a normal shape and size (6.89 cm). Overall echogenicity is normal with adequate corticomedullary distinction and a typical 1:3 cortex:medulla ratio. There is a small amount of perinephric fluid and generalized inflammation. There is no evidence of pyelectasia, nephroliths, infarcts or hydroureter. Renal vasculature is normal.

The right kidney has a normal shape and size (6.98 cm). There is a small non-obstructive nephrolith visualized within the cortex. Overall echogenicity is normal with adequate corticomedullary distinction and a typical 1:3 cortex:medulla ratio. There is a small amount of perinephric fluid and generalized inflammation. There is no evidence of pyelectasia, infarcts or hydroureter. Renal vasculature is normal.

Adrenal Glands

The left adrenal gland is normal in size measuring 0.72 cm at the caudal pole. It is observed in its normal position cranial to the left renal artery. It is normal in appearance (uniformly hypoechoic) and shape with no evidence of a mass effect.

The right adrenal gland is normal in size measuring 0.60 cm at the caudal pole. It is observed in its normal position between the cranial aspect of the right kidney and the caudal vena cava. It is normal in appearance (uniformly hypoechoic) and shape with no evidence of a mass effect.

Spleen

The spleen is subjectively normal in size. The spleen echotexture is heterogenous and mottled, the splenic capsule is smooth with no irregularities. The blood flow through the hilus and splenic parenchyma appears normal. No focal parenchymal abnormalities are visualized.

Liver

The liver is subjectively normal in size, and is hypoechoic with smooth peripheral margins. The parenchyma is heterogenous in echotexture with subtle, indistinct focal mottling. The visible portions of the vasculature and biliary tract appear normal. No focal nodules or cystic lesions are observed.

The gallbladder lumen is moderately distended. The wall of the gall bladder is not thickened and has a smooth mucosal surface. Luminal contents are primarily anechoic. The cystic and common bile ducts are normal/not visible.

Gastrointestinal

The stomach contains minimal luminal contents. It measures at a normal thickness of <0.7cm with some variability due to the presence of rugal folds. The distinction of the gastric wall layers is adequate and there is no impression of reduced peristaltic activity. No masses or focal lesions were observed.

The visualized areas of duodenum, jejunum and ileum have a relatively uniform diameter with minimal fluid distension. Wall thickness is normal. Bowel loops follow a curvilinear path with distinct wall layering maintaining the typical 1:3 muscularis:mucosa layer ratio. The duodenum measured as normal (between 0.3-0.5cm in wall thickness) and the jejunum measured as normal (between 0.2-0.47cm.) Visualized peristalsis appears appropriate. There were no focal lesions consistent with obstruction or a mass effect observed.

The ileocecal junction was visualized and exhibited normal intact wall layering and is subjectively of normal thickness. Sections of colon are visualized with formed fecal material and gas shadowing distally. There is no observed focal or generalized colon wall thickening or loss of layering.

Pancreas

The pancreas is normal and isoechoic to surrounding mesentery. There is no evidence of nodules or cystic lesions. There is no evidence of regional mesenteric inflammation or fluid.

Free Abdomen

There is a small amount of free abdominal fluid, particularly around the kidneys. No lymphadenopathy is noted, but there is a generalized increase in inflammation, particularly in the cranial abdomen.

ULTRASONOGRAPHIC FINDINGS

- Perinephric inflammation and fluid surrounding both kidneys – These findings are non-specific and correlated with possible acute renal failure. Consider infectious causes such as Leptospirosis, pyelonephritis, but other differentials such as toxicities, etc. can also cause these types of changes.
- Mottled spleen – The diffuse splenic changes are non-specific and could be consistent with lymphoid hyperplasia, extramedullary hematopoiesis, infiltrative neoplasia, inflammation, other. Cytology or histopathology would be necessary to get a definitive diagnosis.
- Hypoechoic, heterogeneous liver – The diffuse hepatic changes are non-specific and could be consistent with vacuolar hepatopathy, nodular hyperplasia, inflammatory/immune-mediated disease, fibrosis, extramedullary hematopoiesis, toxic hepatopathy (e.g., copper), infiltrative neoplasia (less likely) or other hepatopathy.
- Scant free abdominal fluid and hyperechoic mesentery in the cranial abdomen – findings are consistent with an inflammatory response/peritonitis (sterile or infectious).

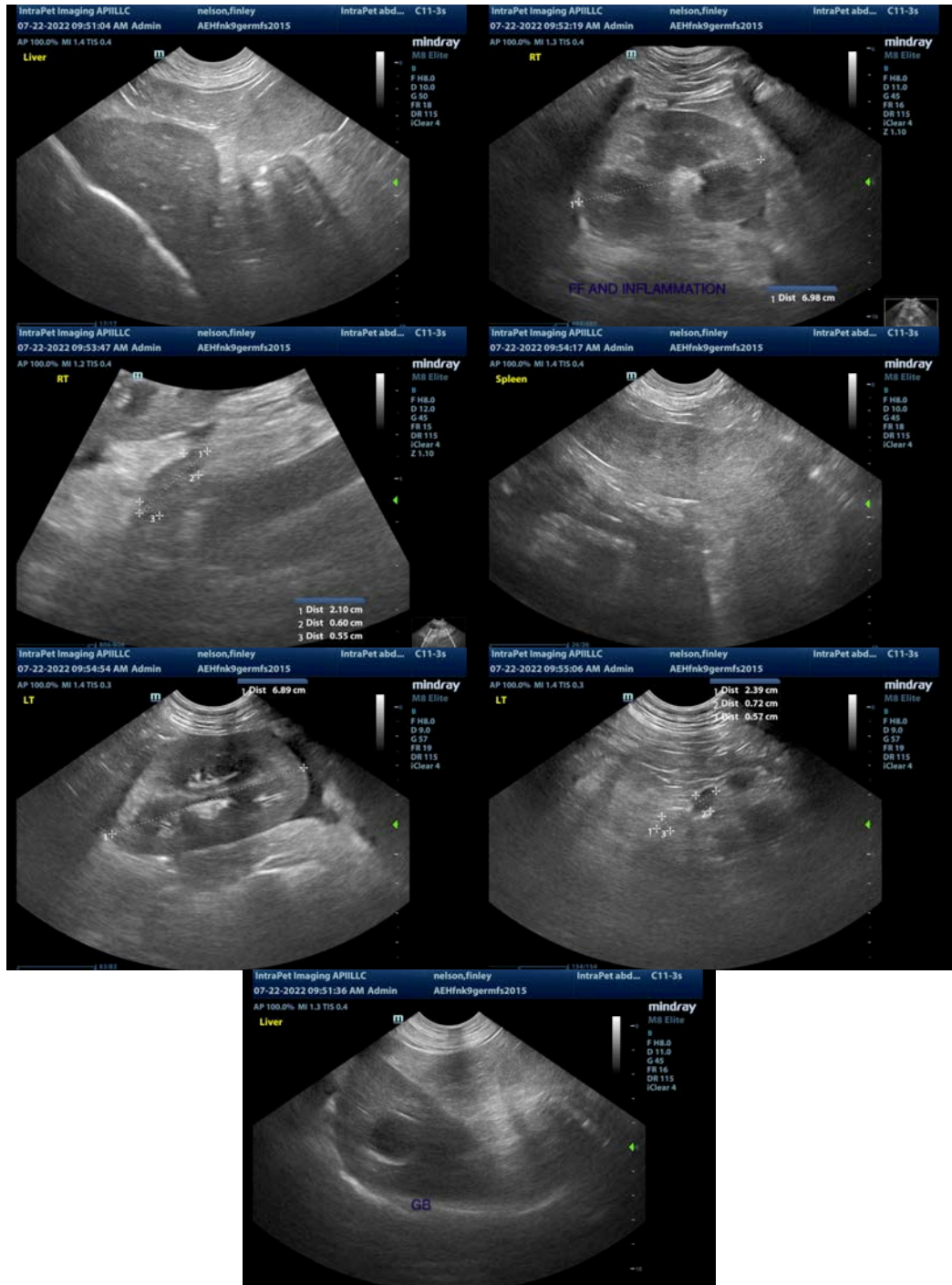
INTERPRETATION OF THE FINDINGS & FURTHER RECOMMENDATIONS

There is inflammation and free fluid in the cranial abdomen. Much of this is surrounding the kidneys, which appear somewhat inflamed. This is consistent with the azotemia reported on the bloodwork, but is a somewhat non-specific finding. Recommend screening for Leptospirosis, consider toxin history, culture the urine, and perform a urinalysis, looking for pyelonephritis. Consider infectious disease testing (lyme, rocky mountain spotted fever, etc.). Additionally, recommend blood pressure evaluation and aggressive diuresis as long as urine output is adequate and blood protein levels are adequate.

The liver is normal to slightly small in size and hypoechoic. If coagulation parameters are normal, you could consider a fine needle aspirate of the liver. No focal lesions are observed, and the gallbladder appears

relatively normal, making these findings most consistent with a primary hepatopathy (infectious, inflammatory, neoplastic, toxic, etc.). If the renal values normalized and cytology is not helpful, consider obtaining liver biopsy.

Consider three view thoracic radiographs to rule out concurrent thoracic disease/involvement.



The information and recommendations provided are based on the images presented by the referring veterinarian/sonographer. No evaluation can be communicated regarding pathology that was not visible in the image/video clips provided.

Thank you for this referral. If the clinical or image interpretation does not parallel your findings or if I can be of any further assistance please contact me.

Kathleen Sennello DVM,MS, Diplomate ACVIM (Small animal Internal Medicine)
kathleen.sennello@sonopath.com