

IMAGING PERFORMED BY

IntraPet.com



SonoPath

Clinical Sonography & Telecytology

EDUCATIONAL TELECONSULTATION SERVICES™

1-800-838-4268 info@sonopath.com SonoPath.com

DATE PRESENTING CLINICAL SIGNS

7/22/22

Referral; O has not noticed any toys missing or anything chewed up. Did see bottom of crate had piece missing, unsure if it came like that or if he chewed it. Known chronic diarrhea-- O believes he has sensitivity to chicken. Yesterday, diarrhea started back up, then vomiting. O did not feed in the morning since she did not want him to defecate in crate. This am, diarrhea every 30mins for several hours. Did eat last night, vomited 2x this am. Last bowel movement this morning looked like spicy mustard. O did switch diet recently from Hills SD to purina salmon.

PATIENT

Asher Fitch

SPECIES

Canine

Current Medications: Omeprazole, Ondansetron, Metronidazole, Buprenorphine, Protonix.
Lab Results: See attached.

BREED

Husky

Radiographs: abnormal gas pattern in right mid-abdominal region
Date of Previous IntraPet Ultrasound: No previous.
Sedation: Patient sedated with Dexdomitor.
Stat Report: Not requested.

SEX

Neutered Male

ULTRASONOGRAPHIC EXAMINATION OF THE ABDOMEN

Urinary System

The urinary bladder is moderately distended with anechoic urine. The Bladder wall, trigone, ureteral papillae and visible urethra (to a depth of 2cm) appear normal with no evidence of wall thickening, mucosal irregularities, masses or cystic calculi.

AGE

7/5/21

The visualized areas of prostate and surrounding tissue appear normal. Unfortunately, the prostate is not fully visualized likely due to its intrapelvic location. Correlate with rectal exam findings.

WEIGHT

66.2 Pounds

The left kidney has a normal shape and size (6.96 cm). Overall echogenicity is normal with adequate corticomedullary distinction and a typical 1:3 cortex:medulla ratio. There is no evidence of perinephric inflammation or effusion. There is no evidence of pyelectasia, nephroliths, infarcts or hydroureter. Renal vasculature is normal.

INTERPRETED BY

Kathleen Sennello DVM,
MS, Diplomate ACVIM
(Small Animal Internal
Medicine)

The right kidney has a normal shape and size (6.74 cm). Overall echogenicity is normal with adequate corticomedullary distinction and a typical 1:3 cortex:medulla ratio. There is no evidence of perinephric inflammation or effusion. There is no evidence of pyelectasia, nephroliths, infarcts or hydroureter. Renal vasculature is normal.

IMAGING PERFORMED BY

Andi Parkinson RDMS

Adrenal Glands

The left adrenal gland is borderline small/"flat" in size measuring 0.50 cm at the caudal pole. It is observed in its normal position cranial to the left renal artery. It is normal in appearance (uniformly hypoechoic) and shape with no evidence of a mass effect.

HOSPITAL NAME

Animal Emergency
Hospital

The right adrenal gland is borderline small/"flat" in size measuring 0.50 cm at the caudal pole. It is observed in its normal position between the cranial aspect of the right kidney and the caudal vena cava. It is normal in appearance (uniformly hypoechoic) and shape with no evidence of a mass effect.

REFERRING VET

Dr. Martinoli

Spleen

The spleen is subjectively normal in size, echotexture is homogenous, and the splenic capsule is smooth with no irregularities. The blood flow through the hilus and splenic parenchyma appears normal. No focal parenchymal abnormalities are visualized.

INVOICE

39765

Liver

The liver is subjectively normal in size, and echogenicity with smooth peripheral margins. The parenchyma is homogenous echotexture. The visible portions of the vasculature and biliary tract appear normal. No focal nodules or cystic lesions are observed.

The gallbladder lumen is moderately distended. The wall of the gall bladder is not thickened and has a smooth mucosal surface. Luminal contents are primarily anechoic. The cystic and common bile ducts are normal/not visible.

Gastrointestinal

The stomach is mildly dilated with fluid and irregular shadowing material most consistent with normal ingesta and gas. It measures at a normal thickness of <0.7cm with some variability due to the presence of rugal folds. The distinction of the gastric wall layering is adequate and there is no impression of reduced peristaltic activity. No masses or focal lesions were observed.

The visualized areas of duodenum, jejunum and ileum have a relatively uniform diameter with minimal fluid distension. Wall thickness is normal. Bowel loops follow a curvilinear path with distinct wall layering maintaining the typical 1:3 muscularis:mucosa layer ratio. Jejunum wall measured 0.43 cm. Visualized peristalsis appears appropriate. There were no focal lesions consistent with obstruction or a mass effect observed.

The ileocecal junction was visualized and exhibited normal intact wall layering and is subjectively of normal thickness. Sections of colon are visualized with formed fecal material and gas shadowing distally. There is no observed focal or generalized colon wall thickening or loss of layering.

Pancreas

The pancreas is prominent and mildly hypoechoic as compared to the surrounding isoechoic mesentery. There is no evidence of nodules or cystic lesions. There is no evidence of regional mesenteric inflammation or fluid.

Free Abdomen

Evaluation of the peritoneal cavity did not reveal any evidence of effusion, or subjective lymphadenomegaly. The Medial iliac nodes appear normal and there was no evidence of a caudal aortic thrombus at the bifurcation. The omentum is of normal uniform echogenicity.

ULTRASONOGRAPHIC FINDINGS

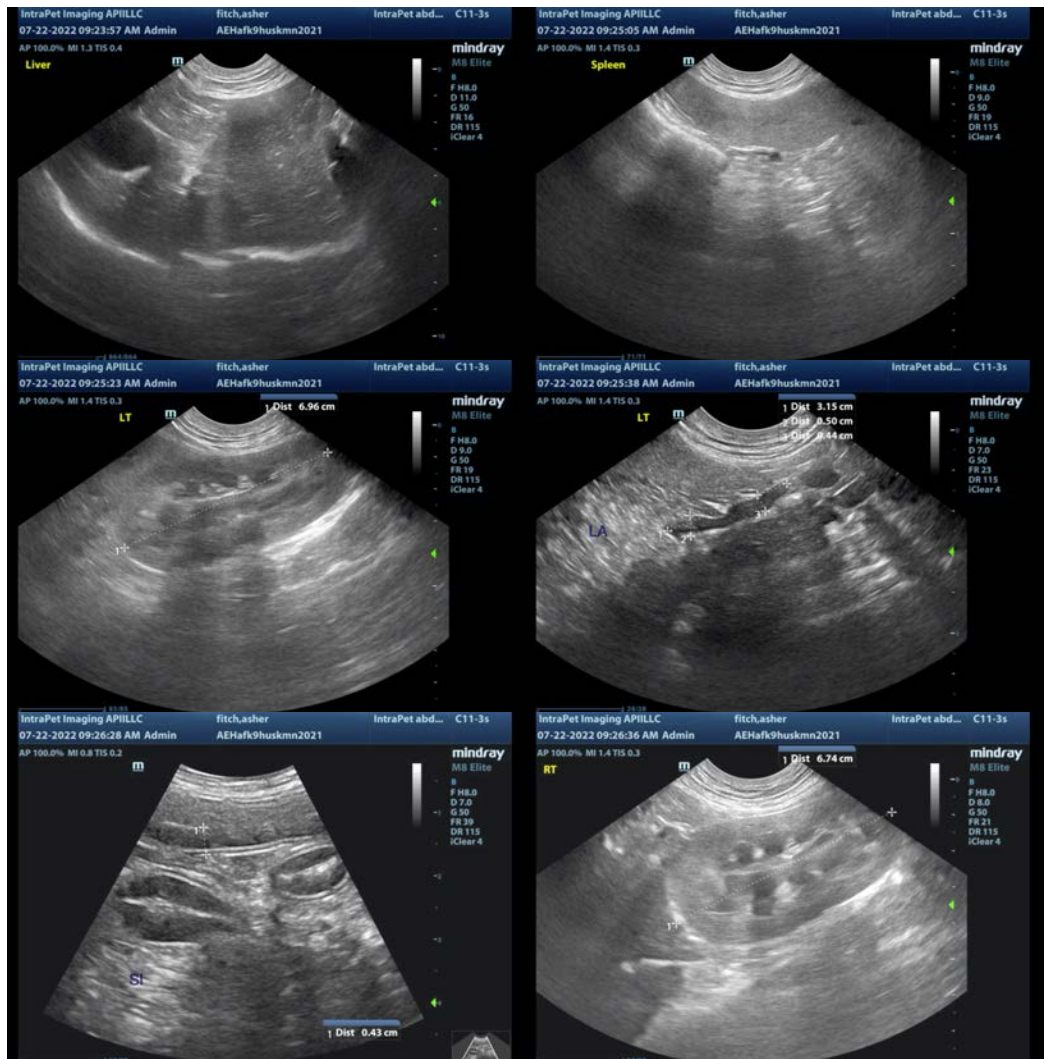
- Borderline “flat” adrenal glands – recommend screening for Addison’s disease.
- Mildly hypoechoic pancreas – The pancreatic changes are most consistent with age-related parenchymal remodeling, potentially secondary to a prior inflammatory episode, early fibrosis or chronic pancreatitis.
- Mild amount of fluid/ingesta within the gastric lumen – correlate with feeding history and abdominal radiographs. If the patient was adequately fasted, consider such differentials as delayed gastric emptying or ingested gastric foreign material.

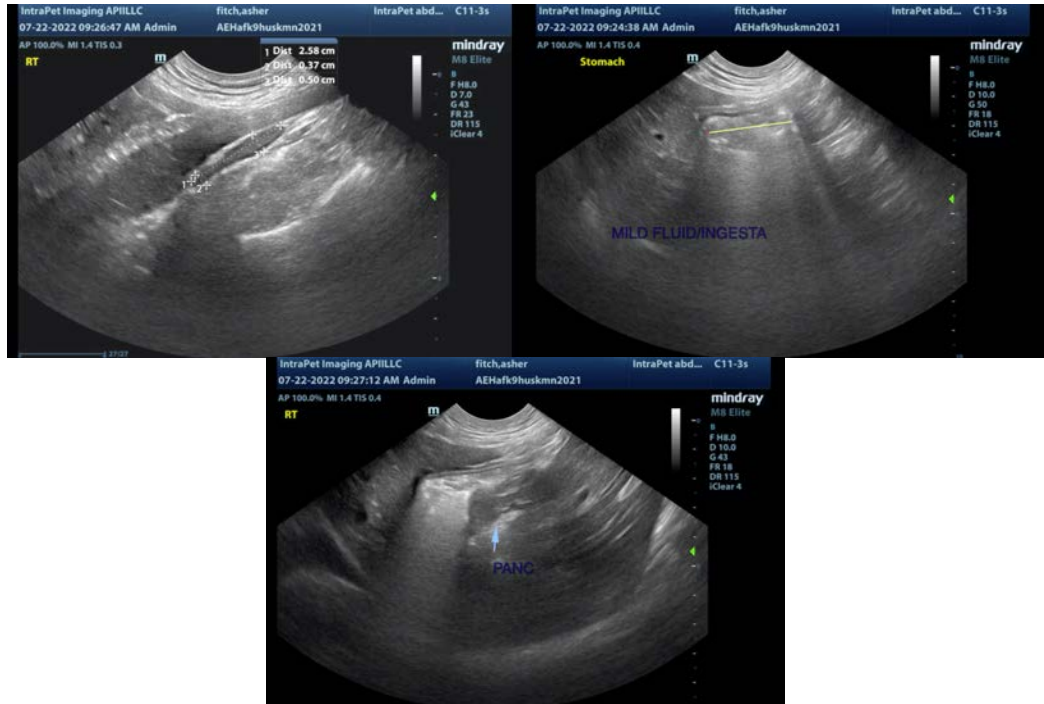
INTERPRETATION OF THE FINDINGS & FURTHER RECOMMENDATIONS

Today’s scan appears relatively normal. No focal lesions are observed. The adrenal glands do appear somewhat “flat” in appearance. Recommend screening for Addison’s disease. There is a small amount of fluid and likely ingesta within the gastric lumen. Recommend treating for acute gastroenteritis. If symptoms persist, then consider reimaging and screening for ingested foreign material.

In a pet this age, consider such differentials as food allergy/dietary intolerance, GI parasitism, Addison's disease, dysbiosis, less likely pancreatitis, less likely IBD or intestinal neoplasia. You could consider these therapeutic and diagnostic options:

- Recommend a novel protein/hydrolyzed protein prescription diet.
- Recommend the aforementioned ACTH stimulation test.
- Consider a GI panel to Texas A&M for a qualitative PLI, TLI, cobalamin and folate to look for evidence of pancreatic and small intestinal disease.
- Recommend chronic probiotic therapy.
- If symptoms persist and other differentials are unlikely, consider obtaining GI biopsies.





The information and recommendations provided are based on the images presented by the referring veterinarian/sonographer. No evaluation can be communicated regarding pathology that was not visible in the image/video clips provided.

Thank you for this referral. If the clinical or image interpretation does not parallel your findings or if I can be of any further assistance please contact me.

Kathleen Sennello DVM,MS, Diplomate ACVIM (Small animal Internal Medicine)
kathleen.sennello@sonopath.com