

IMAGING PERFORMED BY

IntraPet.com



SonoPath

Clinical Sonography & Telecytology

EDUCATIONAL TELECONSULTATION SERVICES™

1-800-838-4268 info@sonopath.com SonoPath.com

DATE PRESENTING CLINICAL SIGNS

7/22/22

Acute onset this morning of vomiting and diarrhea; seeming painful panting on/off not known to eat things no change in diet does not get people food no previous health problems besides missing teeth adopted at the age of 7 years- not sure if she has been spayed or not indoor only

PATIENT

Amy Cedrone

Current Medications: Provable, Metronidazole, Omeprazole, Cerenia, Buprenorphine, Mirtazapine.
Lab Results: See attached.

SPECIES

Feline

Radiographs: stomach looks empty and SI pattern - mild gas changes- no obvious obstruction small patchy area in the caudal lung fields noted; small bladder small stool in the colon

Date of Previous IntraPet Ultrasound: No previous.

Sedation: Not required to complete full diagnostic ultrasound.

Stat Report: Not requested.

BREED

DSH

ULTRASONOGRAPHIC EXAMINATION OF THE ABDOMEN

SEX

Intact Female

Urinary System

The urinary bladder is moderately distended with anechoic urine. The Bladder wall, trigone, ureteral papillae and visible urethra (to a depth of 2cm) appear normal with no evidence of wall thickening, mucosal irregularities, masses or cystic calculi.

AGE

7/14/09

The left kidney has a normal shape and size (3.53 cm). Overall echogenicity is normal with adequate corticomedullary distinction and a typical 1:3 cortex:medulla ratio. There is no evidence of perinephric inflammation or effusion. There is no evidence of pyelectasia, nephroliths, infarcts or hydroureter. Renal vasculature is normal.

WEIGHT

15.5 Pounds

The right kidney has a normal shape and size (4.0 cm). Overall echogenicity is normal with adequate corticomedullary distinction and a typical 1:3 cortex:medulla ratio. There is no evidence of perinephric inflammation or effusion. There is no evidence of pyelectasia, nephroliths, infarcts or hydroureter. Renal vasculature is normal.

INTERPRETED BY

Kathleen Sennello DVM,
MS, Diplomate ACVIM
(Small Animal Internal
Medicine)

Adrenal Glands

The left adrenal gland is normal in size measuring 0.43 cm at the caudal pole. It is observed in its normal position cranial to the left renal artery. It is normal in appearance (uniformly hypoechoic) and shape with no evidence of a mass effect.

IMAGING PERFORMED BY

Andi Parkinson RDMS

The region of the right adrenal (between right cranial kidney and vena cava) is unremarkable, but the adrenal is not distinctly visualized. No evidence of a mass effect.

HOSPITAL NAME

Animal Emergency
Hospital

Spleen

The spleen is large and hypoechoic, measuring 1.4 cm at the level of the hilus. The blood flow through the hilus and splenic parenchyma appears normal. No focal parenchymal abnormalities are visualized. This large spleen could be normal for this large cat.

REFERRING VET

Dr. Willer

Liver

The liver is subjectively normal in size with smooth peripheral margins. The parenchyma is mildly hyperechoic and homogenous in echotexture. The visible portions of the vasculature and biliary tract appear normal. No focal nodules or cystic lesions are observed.

INVOICE

39764

The gallbladder lumen is moderately distended. The wall of the gall bladder is not thickened and has a smooth mucosal surface. Luminal contents are primarily anechoic. The cystic and common bile ducts are normal/not visible.

Gastrointestinal

The stomach contains minimal luminal contents. It measures at a normal thickness of <0.36cm with some variability due to the presence of rugal folds. The distinction of the gastric wall layers is adequate and there is no impression of reduced peristaltic activity. No masses or focal lesions were observed.

The visualized areas of duodenum, jejunum and ileum have a relatively uniform diameter with minimal fluid distension. Wall thickness is normal. Bowel loops follow a curvilinear path with distinct wall layering maintaining the typical 1:3 muscularis:mucosa layer ratio. Jejunum wall measured 0.18 cm. Visualized peristalsis appears appropriate. There were no focal lesions consistent with obstruction or a mass effect observed.

The ileocecal junction was visualized and exhibited normal intact wall layering and is subjectively of normal thickness. Sections of colon are visualized with formed fecal material and gas shadowing distally. There is no observed focal or generalized colon wall thickening or loss of layering.

Pancreas

The pancreas is normal and isoechoic to surrounding mesentery. There is no evidence of nodules or cystic lesions. There is no evidence of regional mesenteric inflammation or fluid.

Free Abdomen

Evaluation of the peritoneal cavity did not reveal any evidence of effusion. There are occasional prominent mesenteric lymph nodes, one measures 0.39 cm, another measures 0.47 cm in the area of the ileocecal junction with hyperechoic mesentery surrounding.

ULTRASONOGRAPHIC FINDINGS

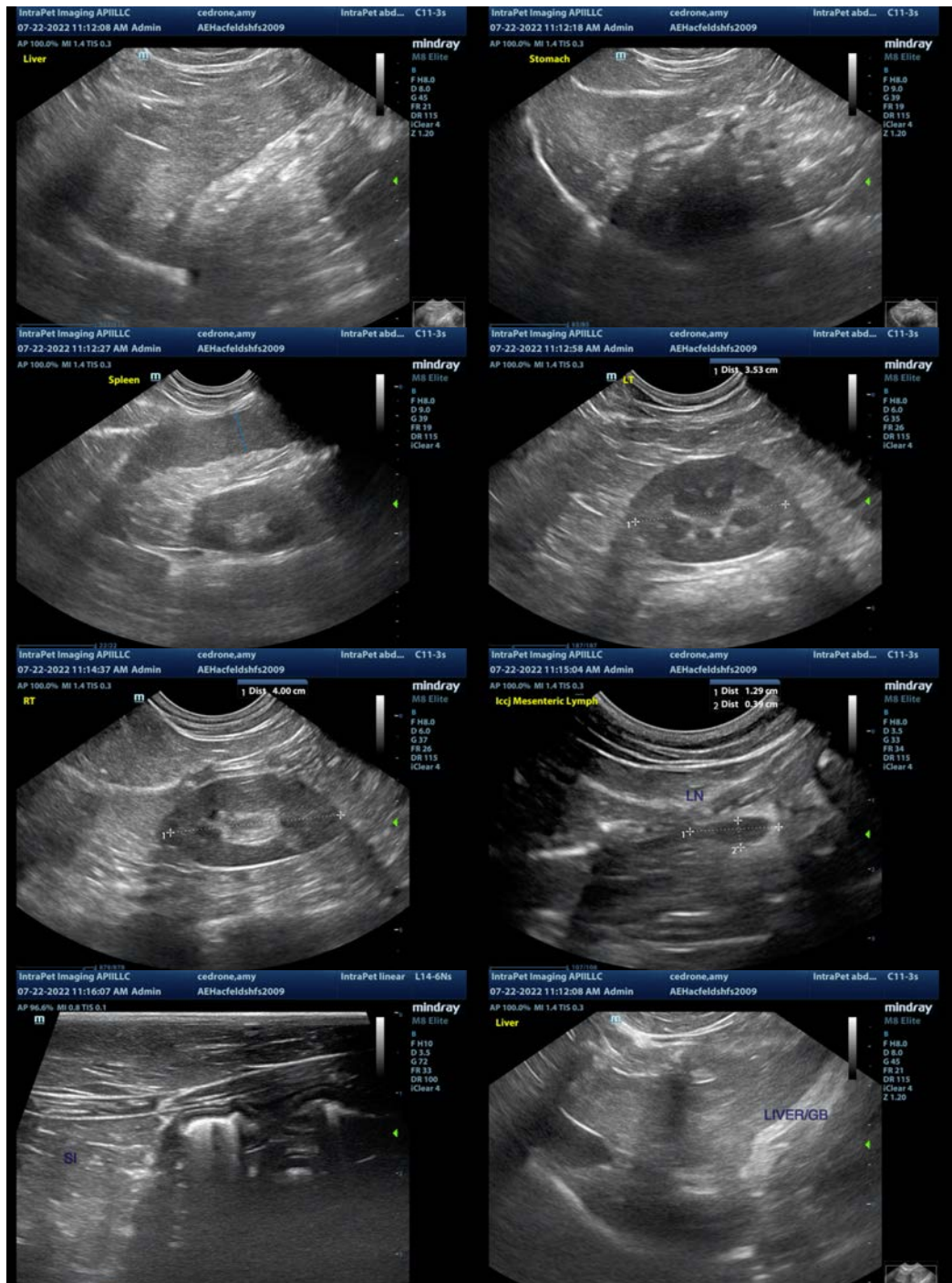
- Subjectively large, hypoechoic spleen – This could be normal for this large cat. If symptoms persist, consider a fine needle aspirate.
- Borderline hyperechoic liver – Hepatic changes are non-specific and could be consistent with hepatic lipidosis, inflammatory/infectious disease, infiltrative neoplasia, or other hepatopathy. This could also be associated with fatty infiltration in an overweight patient.
- Mild mesenteric lymphadenopathy – The prominent abdominal lymph nodes are most consistent with reactive lymphadenitis or lymphoid hyperplasia. Neoplastic infiltration is considered less likely.

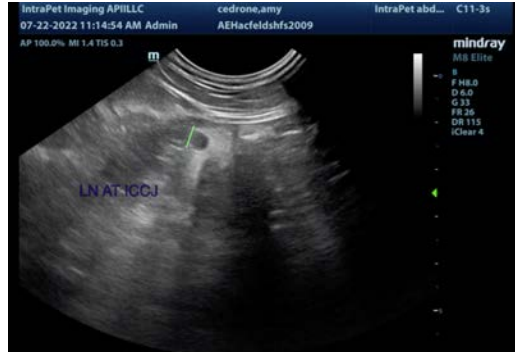INTERPRETATION OF THE FINDINGS & FURTHER RECOMMENDATIONS

No focal gastrointestinal lesions are observed, and the pancreas appears relatively normal on today's scan. Correlate these findings with abdominal radiographs. Recommend treatment for acute gastroenteritis. If patient's symptoms persist, consider:

- Novel protein/hydrolyzed protein prescription diet.
- GI panel to Texas A&M with a qualitative fPLI, TLI, cobalamin and folate to further evaluate the pancreas and small intestine.
- Fine needle aspirate of the spleen.
- Chronic probiotic therapy.
- If symptoms persist, consider serial imaging and possible GI biopsies.

The white blood cell count appears low in this patient. Recommend a pathologist review of a blood smear and possible workup for primary bone marrow disease if this persists.





The information and recommendations provided are based on the images presented by the referring veterinarian/sonographer. No evaluation can be communicated regarding pathology that was not visible in the image/video clips provided.

Thank you for this referral. If the clinical or image interpretation does not parallel your findings or if I can be of any further assistance please contact me.

Kathleen Sennello DVM,MS, Diplomate ACVIM (Small animal Internal Medicine)
kathleen.sennello@sonopath.com