

**DATE PRESENTING CLINICAL SIGNS**

7.21.2023 11yo Dachshund presented 7/12/23 for inappetence, shaking, hiding under bed, no v/d. Has been urinating frequently w/ foul odor for past 2 mos. On PE, otitis, yeast skin infection, potbellied appearance.

PATIENT

Omi Burke

Current Medications: Clavamox (15mg/kg) - 1.5ml (62.5mg/ml) PO q12h x 14 days #3 boxes, terbinafine - one 250mg tablets PO q24h x 21 days #21, Cerenia - one 16mg tab PO q24h x 4 days #1 box, gabapentin (10mg/kg) - 1.3ml PO q12h PRN for pain. May cause sedation #80ml, miconhex + triz shampoo - Apply to haircoat and work into a lather. Let stand 5-10 minutes then rinse thoroughly. Bathe 1-2 times per week #1 16oz bottle

SPECIES

Canine

Lab Results: Prev LDDST testing in Nov 2022 neg for Cushing's. Treated w/ Clavamox for UTI. Mild elev in ALP (458), totprot 8.1, glob 4.7

BREED

Dachshund

Date of Previous IntraPet Ultrasound: No previous.

Sedation: Not required to complete full diagnostic ultrasound.

Stat Report: Not requested.

SEX

Female Spayed

ULTRASONOGRAPHIC EXAMINATION OF THE ABDOMEN**Urinary System**

The urinary bladder is moderately distended with anechoic urine. The bladder wall largely appears normal, but is slightly irregular and thickened (measuring 0.35 cm). The area of the trigone, ureteral papillae and visible urethra (to a depth of 2 cm) appear normal with no evidence of calculi or mass lesions.

AGE

7/2/2012

The left kidney has a normal shape and size (5.16 cm). Overall echogenicity is normal with adequate corticomedullary distinction and a typical 1:3 cortex:medulla ratio. There is no evidence of perinephric inflammation or effusion. There is no evidence of pyelectasia, nephroliths, infarcts or hydroureter. Renal vasculature is normal.

WEIGHT

14.6 lbs

The right kidney has a normal shape and size (5.13 cm). Overall echogenicity is normal with adequate corticomedullary distinction and a typical 1:3 cortex:medulla ratio. There is no evidence of perinephric inflammation or effusion. There is no evidence of pyelectasia, nephroliths, infarcts or hydroureter. Renal vasculature is normal.

INTERPRETED BY

Kathleen Sennello
DVM, MS, Diplomate
ACVIM (Small Animal
Internal Medicine)

Adrenal Glands

The left adrenal gland is normal in size (0.69 cm at the caudal pole). It is observed in its normal position cranial to the left renal artery. It is normal in appearance (uniformly hypoechoic) and shape with no evidence of a mass effect.

HOSPITAL NAME

Chadwell AH

The right adrenal gland is normal in size (0.68 cm at the caudal pole). It is observed in its normal position between the cranial aspect of the right kidney and the caudal vena cava. It is normal in appearance (uniformly hypoechoic) and shape with no evidence of a mass effect.

REFERRING VET

Dr. Mengers

Spleen

The spleen is subjectively normal in size, echotexture is homogenous, and the splenic capsule is smooth with no irregularities. The blood flow through the hilus and splenic parenchyma appears normal. No focal parenchymal abnormalities are visualized.

INVOICE

13787

Liver

The liver is subjectively large in size, and normal in echogenicity with smooth peripheral margins. The parenchyma is heterogenous in echotexture with subtle, indistinct focal mottling. The visible portions of the vasculature and biliary tract appear normal. No focal nodules or cystic lesions are observed.

Gastrointestinal

The stomach contains minimal luminal contents. It measures at a normal thickness of <0.7 cm with some variability due to the presence of rugal folds. The distinction of the gastric wall layers is adequate and there is no impression of reduced peristaltic activity. No masses or focal lesions were observed.

The visualized areas of duodenum (0.34), jejunum (0.32) and ileum have a uniform diameter with minimal fluid distension. Wall appears subjectively mildly increased. Bowel loops follow a typical curvilinear path with distinct wall layering. Visualized peristalsis appears appropriate. There is mild mucosal speckling of the duodenum. There were no focal lesions consistent with obstruction or a mass effect observed.

The ileocecal junction was visualized and exhibited normal intact wall layering and is subjectively of normal thickness. The colon is somewhat dilated distally with liquid fecal material. There is no observed focal or generalized colon wall thickening or loss of layering.

Pancreas

The pancreas is prominent and mottled compared to the surrounding isoechoic mesentery. There is no evidence of nodules or cystic lesions. There is no evidence of regional mesenteric inflammation or fluid.

Free Abdomen

Evaluation of the peritoneal cavity did not reveal any evidence of effusion. There are occasional mild, prominent mesenteric lymph nodes (examples visualized at 0.32 and 0.33 cm). The omentum is generally of normal echogenicity.

ULTRASONOGRAPHIC FINDINGS

Findings

- Mildly irregular/thickened urinary bladder wall – Findings are most consistent with bacterial cystitis or lack of sufficient urine distention. Recommend urinalysis and culture.
- Prominent mottled pancreas – The pancreatic changes are most consistent with age-related parenchymal remodeling, potentially secondary to a prior inflammatory episode, early fibrosis or chronic pancreatitis.
- Large heterogenous liver – The diffuse hepatic changes are non-specific and could be consistent with vacuolar hepatopathy, nodular hyperplasia, inflammatory/immune-mediated disease, fibrosis, extramedullary hematopoiesis, toxic hepatopathy (e.g., copper), infiltrative neoplasia (less likely) or other hepatopathy.
- Subjectively prominent duodenum with mild mucosal speckling – Bright mucosal speckling has been postulated to represent dilated lacteals or focal accumulations of mucus, cellular debris, etc. in the mucosal crypts.
- Visible/slightly prominent mesenteric lymph nodes – The prominent abdominal lymph nodes are most consistent with reactive lymphadenitis or lymphoid hyperplasia. Neoplastic infiltration is considered less likely.

INTERPRETATION OF THE FINDINGS & FURTHER RECOMMENDATIONS

The changes observed on today's scan are relatively mild. No obvious source for significant abdominal pain is identified.

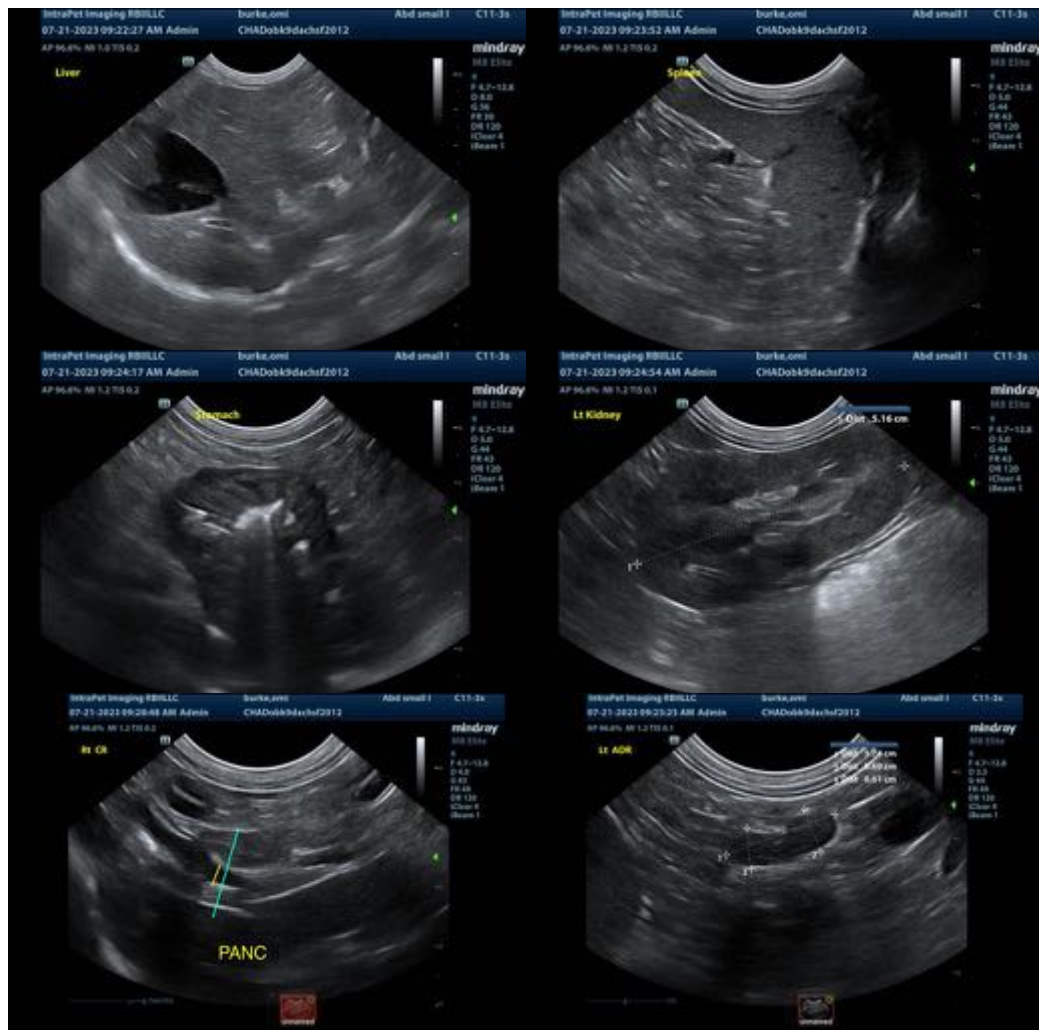
The urinary bladder is slightly thickened and irregular. This could be due to lack of full urine distention or due to mild cystitis. Recommend a urinalysis and culture to further investigate.

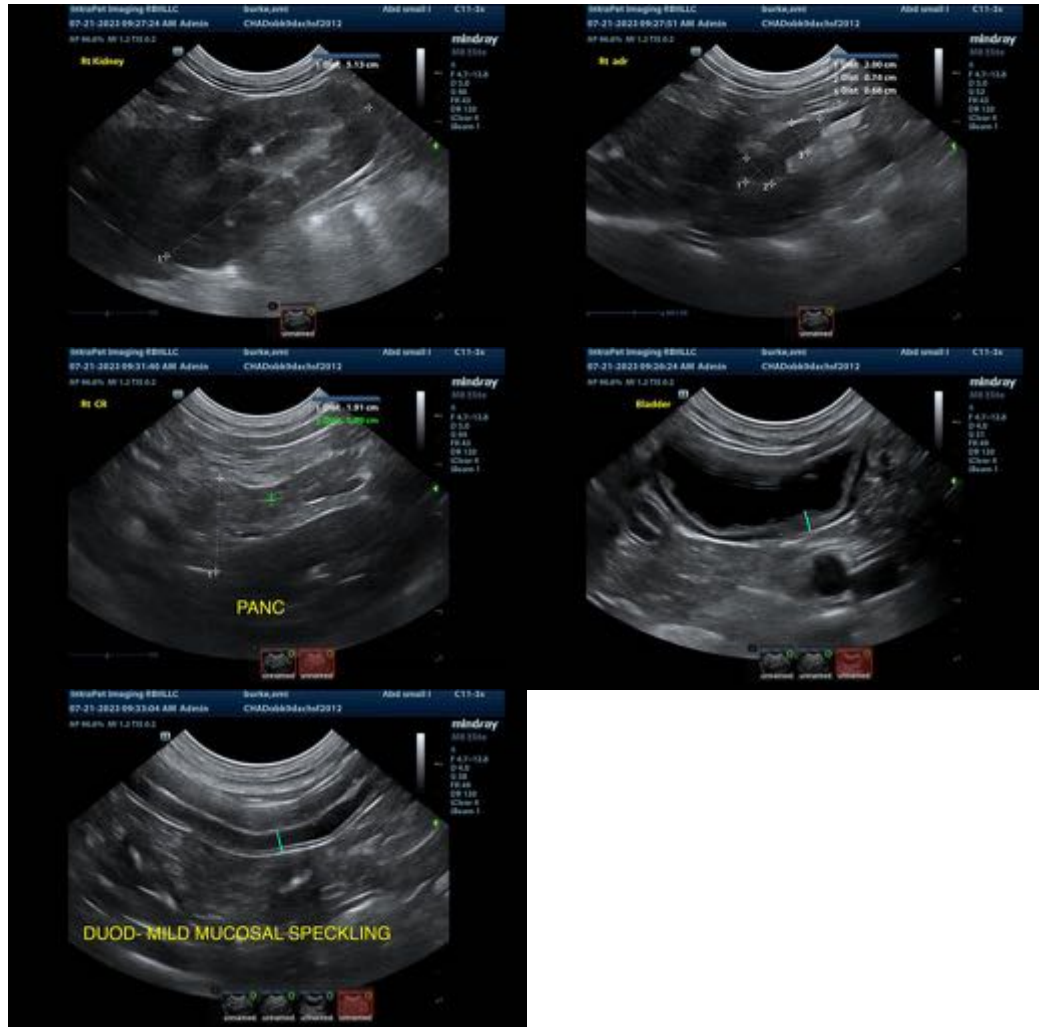
The pancreas appears slightly prominent and mottled, with minimal surrounding inflammation. Findings are most consistent with remodeling and previous episodes of pancreatic inflammation, although mild current inflammation cannot be definitively ruled out.

The liver appears slightly heterogenous and large with no focal lesions. Given the primary ALP elevation, this could be consistent with mild vacuolar hepatopathy. Options moving forward would include a fine-needle aspirate of the liver, screening for Cushing's disease, if consistent clinical signs are evident (not at this time, when there is concurrent illness going on) or continued monitoring.

There is mild mucosal speckling associated with the duodenum. This could be consistent with mild gastrointestinal disease. If there is significant vomiting, diarrhea, weight loss, etc., you could consider a GI panel at Texas A&M for a qualitative PLI, TLI, cobalamin, and folate to further evaluate the GI tract.

Given the history and the concern for pain, consider extrabdominal sources such as spinal, neuromuscular pain, etc.





The information and recommendations provided are based on the images presented by the referring veterinarian. No evaluation can be communicated regarding pathology that was not visible in the image/video clips provided.

Thank you for this referral. If the clinical or image interpretation does not parallel your findings or if I can be of any further assistance, please contact me.

Kathleen Sennello DVM, MS, Diplomate ACVIM (Small animal Internal Medicine)
info@SonoPath.com