**DATE PRESENTING CLINICAL SIGNS**

7.22.2023 Presented in March 2023 for routine med monitoring lab work for CUSHINGS AND CKD and mentioned just started urinating more than normal. Urinalysis performed also to rule out infection.

**PATIENT**

Iris Comber

Current Medications: Dispensed 6/22/23 for UTI 1. Cefpodoxime 50 mg SID 28 days  
 2. Galliprant 20 mg SID 28 days 3. Metronidazole 125 mg BID while on antibiotics for diarrhea

Chronic meds: 1. Enalapril 2.5 mg BID 2. Vetoryl 10 mg SID 3. Fluoxetine 10 mg SID

Lab Results: 7/19/23: UA (Cysto) - USG - 1.014, pH-5, protein-30, blood-10, WBC-5/HPF, RBC-

**SPECIES**

Canine

9/HPF; Non Sq Epi Cells - 6-10/HPF, Hyaline casts>1/HPF, Non-Hyaline Casts>1/HPF; BP - Normal; ACTH Stimulation test normal. Cystitis resolved. 6/20/23: CBC/Chem 11 - ALKP-255, BUN-36, SDMA-

**BREED**

Mixed

21.5, K-6, PLT-895; UA (Cysto) - USG - 1.016, pH-5, protein-2+, blood-trace, WBC-4-10/HPF, RBC-0-1/HPF, MA-19.1, Rods>100/HPF; Dispensed Cefpodoxime and Galliprant; Recheck urine after finishing antibiotics. Called owner. Owner also requested medication for diarrhea. Owner states her stools are already usually soft and she develops diarrhea when she is on antibiotics. 4/26/23: Urine Culture - E. coli >100,000 CFU/ml. Susceptible to multiple drugs. Recommend extended course of treatment due to renal impairment. Called owner. Left message. Start Cefpodoxime while boarding. 4/21/23: CBC/Chem 11 -

**SEX**

Female Spayed

HCT-33.2, HGB-12.7, MCV-56.9, MCHC-38.3, SDMA-15, BUN-34, K-6.5, Cl-107, ALT-141; Non regenerative anemia likely secondary to chronic renal disease. Renal values slightly improved. Concern for hyperkalemia. Recommend decreasing Enalapril (5 mg) to 1/2 tablet BID. 3/10/23: CBC/Chem 11/Lytes - mild anemia, mild azotemia, Na/K-24, Cl-102; ACTH Stim test - controlled, but CBC/Chem concerning for Addison's; UA - USG-1.015, marked rods, 20-30 WBC/HPF; UPC-0.7 (but cystitis present); Recommend Clavamox for cystitis, decrease Vetoryl to 10 mg SID and recheck CBC/Chem 11/Lytes in 1 month.

**AGE**

1/14/2008

Date of Previous IntraPet Ultrasound: No previous.

Sedation: Not required to complete full diagnostic ultrasound.

**WEIGHT**

16.1 lbs

Stat Report: Not requested.

Imaging Performed By: Andi Parkinson, BS, RDMS.

**ULTRASONOGRAPHIC EXAMINATION OF THE ABDOMEN****INTERPRETED BY**

Kathleen Sennello  
 DVM, MS, Diplomate  
 ACVIM (Small Animal  
 Internal Medicine)

**Urinary System**

The urinary bladder is moderately distended with anechoic urine. The bladder wall appears slightly irregular and thickened (measuring up 5.40 cm). The area of the trigone, ureteral papillae and proximal urethra appear free of any mass, lesions or calculi.

**HOSPITAL NAME**

Parkville AH

The left kidney has a normal shape and size (4.16 cm). Overall echogenicity is slightly hyperechoic with poor corticomedullary distinction and a typical 1:3 cortex:medulla ratio. There is no evidence of focal perinephric inflammation or effusion. Numerous, small cortical cysts are seen. There is no evidence of pyelectasia, nephroliths, infarcts or hydroureter. Renal vasculature is normal.

**REFERRING VET**

Dr. Suter

The right kidney has a normal shape and size (4.03 cm). Overall echogenicity is slightly hyperechoic with poor corticomedullary distinction and a typical 1:3 cortex:medulla ratio. There is no evidence of focal perinephric inflammation or effusion. Numerous, small cortical cysts are seen. There is no evidence of pyelectasia, nephroliths, infarcts or hydroureter. Renal vasculature is normal.

**INVOICE**

13785

**Adrenal Glands**

The left adrenal gland is normal in size (0.50 cm at the caudal pole). It is observed in its normal position cranial to the left renal artery. It is normal in appearance (uniformly hypoechoic) and shape with no evidence of a mass effect.

The right adrenal gland is normal in size (0.64 cm at the caudal pole). It is observed in its normal position between the cranial aspect of the right kidney and the caudal vena cava. It is normal in appearance (uniformly hypoechoic) and shape with no evidence of a mass effect.

### ***Spleen***

The spleen is subjectively normal in size and the echotexture is homogenous. The splenic capsule is smooth with no visible irregularities. Rare discrete focal hyperechoic, perivascular parenchymal abnormalities are present. The appearance of these lesions is most consistent with benign splenic myelolipomas. The blood flow through the hilus and splenic parenchyma appears normal.

### ***Liver***

The liver is subjectively large in size, and normal in echogenicity with smooth peripheral margins. The parenchyma is heterogenous in echotexture with subtle, indistinct focal mottling. The visible portions of the vasculature and biliary tract appear normal. No focal nodules or cystic lesions are observed.

Gallbladder is moderately distended with anechoic bile as well as suspended and gravity dependent echogenic debris. The wall is smooth without visible thickening. There is no evidence of cystic or CBD dilation. There is no evidence of effusion or inflammation.

### ***Gastrointestinal***

The stomach contains minimal luminal contents. It measures at a normal thickness of <0.7 cm with some variability due to the presence of rugal folds. The distinction of the gastric wall layers is adequate and there is no impression of reduced peristaltic activity. No masses or focal lesions were observed.

The visualized areas of duodenum, jejunum and ileum have a relatively uniform diameter with minimal fluid distension. Wall thickness is normal. Bowel loops follow a curvilinear path with distinct wall layering maintaining the typical 1:3 muscularis:mucosa layer ratio. The duodenum measured as normal (between 0.3-0.5 cm in wall thickness) and the jejunum measured as normal (0.29 cm) Visualized peristalsis appears appropriate. There were no focal lesions consistent with obstruction or a mass effect observed.

The ileocecal junction was visualized and exhibited normal intact wall layering and is subjectively of normal thickness. Sections of colon are visualized with formed fecal material and gas shadowing distally. There is no observed focal or generalized colon wall thickening or loss of layering.

### ***Pancreas***

The pancreas is normal and isoechoic to surrounding mesentery. There is no evidence of nodules or cystic lesions. There is no evidence of regional mesenteric inflammation or fluid.

### ***Free Abdomen***

Evaluation of the peritoneal cavity did not reveal any evidence of effusion, or subjective lymphadenomegaly. The Medial iliac nodes appear normal and there was no evidence of a caudal aortic thrombus at the bifurcation. The omentum is of normal uniform echogenicity.

### ***Other***

The right auricle and pericardium were visualized and were unremarkable. No obvious pathology is visualized. If cardiac function evaluation is desired a full echocardiogram is warranted. No evidence of pleural effusion or thoracic mass lesions are observed.

## **ULTRASONOGRAPHIC FINDINGS**

### **Primary Findings**

- Thickened, irregular urinary bladder wall. Findings are most consistent with diffuse cystitis. Recommend a urinalysis and culture. Underlying neoplastic change cannot be ruled out.

- Decreased corticomedullary distinction in both kidneys with numerous, small cortical cysts - Mild loss of corticomedullary distinction in both kidneys could be consistent with chronic degenerative disease or interstitial nephrosis.
- Hyperechoic nodules visualized in the spleen – Findings are most consistent with benign myelolipomas. Continued monitoring is warranted, as an underlying neoplastic process cannot be definitively ruled out.
- Large heterogenous liver - The diffuse hepatic changes are non-specific and could be consistent with vacuolar hepatopathy, nodular hyperplasia, inflammatory/immune-mediated disease, fibrosis, extramedullary hematopoiesis, toxic hepatopathy (e.g., copper), infiltrative neoplasia (less likely) or other hepatopathy.
- Moderate gall bladder debris - The significance of the aggregated gallbladder debris is unclear. This could represent an early mucocele, cholestasis, or may be secondary to fasting but seems unlikely to be causing a current issue. Recommend continued monitoring.

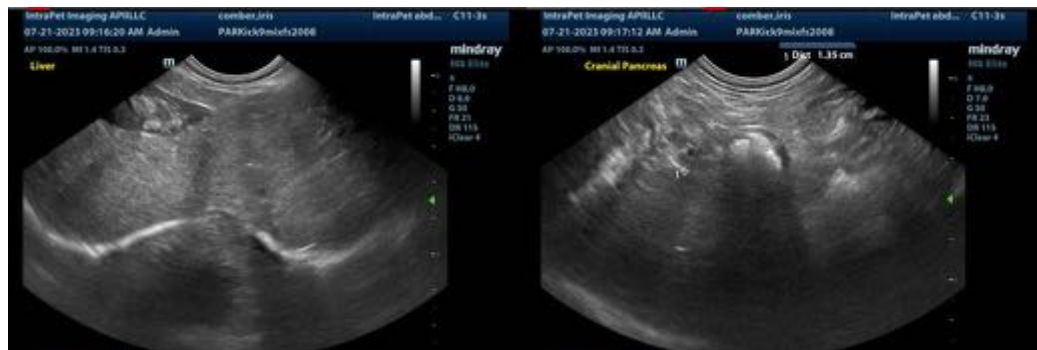
#### **INTERPRETATION OF THE FINDINGS & FURTHER RECOMMENDATIONS**

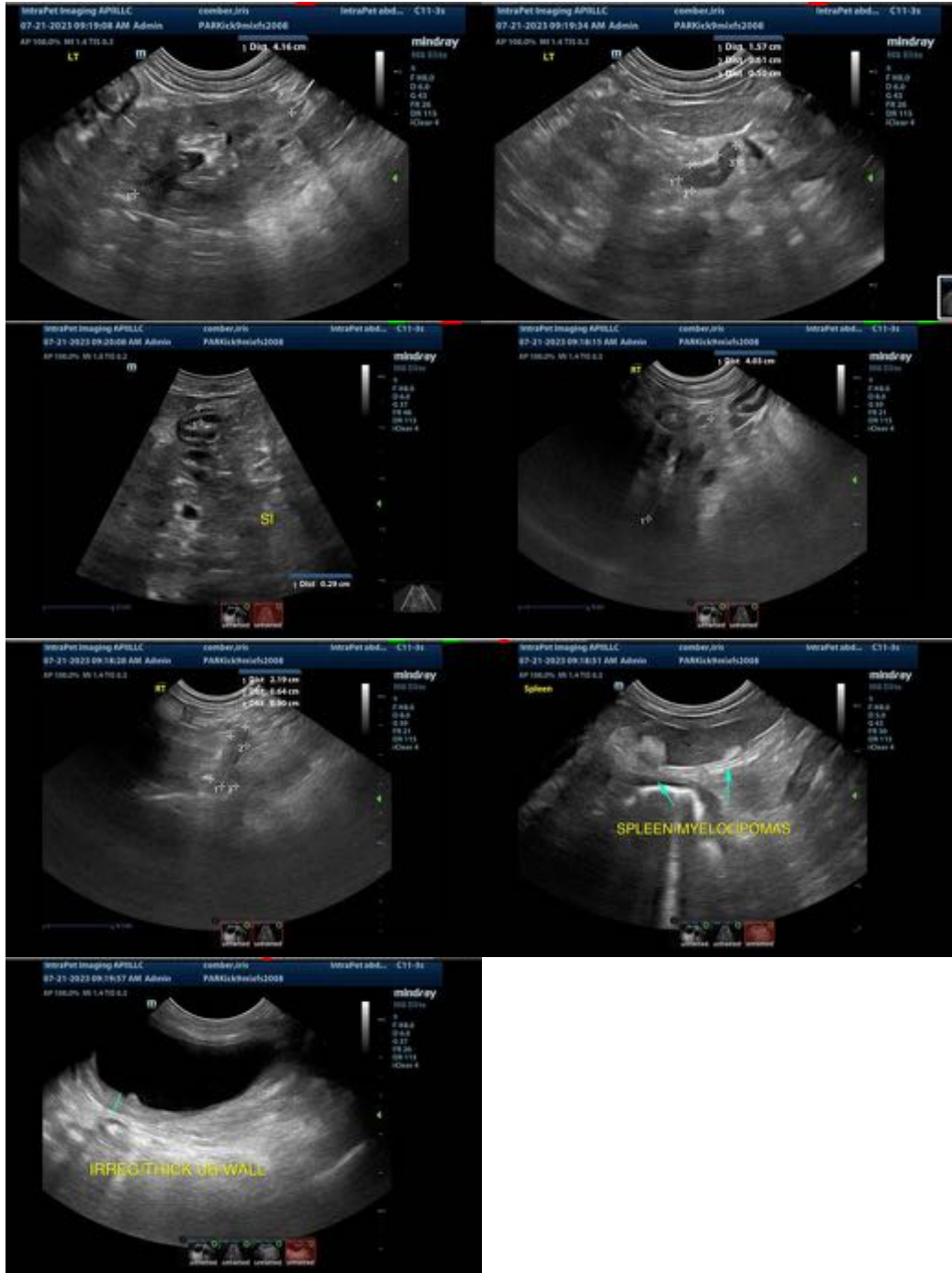
The urinary bladder appears somewhat thickened and irregular. These changes are likely consistent with bacterial cystitis. Recommend urinalysis and culture. If no infection is present, then consider a traumatic catheterization, looking for any evidence of underlying neoplasia. If infection is present, recommend reevaluation of the urinary bladder while on antibiotics in approximately two weeks to ensure that the irregularity and thickening resolves with therapy.

Both kidneys have changes consistent with chronic progressive renal disease. Recommend a blood pressure, urinalysis and culture as a baseline.

The changes observed in the liver are likely consistent with the pituitary-dependent hyperadrenocorticism described. There is some moderate debris in the gallbladder, but no gallbladder wall thickening or associated inflammation at this time.

Recommend three-view thoracic radiographs to evaluate for possible concurrent thoracic disease/involvement.





The information and recommendations provided are based on the images presented by the referring veterinarian. No evaluation can be communicated regarding pathology that was not visible in the image/video clips provided.

Thank you for this referral. If the clinical or image interpretation does not parallel your findings or if I can be of any further assistance, please contact me.

Kathleen Sennello DVM, MS, Diplomate ACVIM (Small animal Internal Medicine)  
[info@SonoPath.com](mailto:info@SonoPath.com)