



PATIENT

Hazel Banta

SPECIES

Feline

BREED

DSH

SEX

Female

AGE

7 Years

WEIGHT

12.1 Pounds

INTERPRETED BY

Kathleen Sennello DVM,
MS, Diplomate ACVIM
(Small Animal Internal
Medicine)

**IMAGING
PERFORMED BY**

Dr. Gordon Brackee

HOSPITAL NAME

Bradentown VH

REFERRING VET

Dr. Gordon Brackee

INVOICE

39744

DATE

7/21/22

PRESENTING CLINICAL SIGNS

Lethargic, depressed, dehydrated, jaundiced for 2 days. FELV/FIP-Neg
Abnormal PE/Chem/CBC/UA Results: CBC: NEU %=93.3, PLT=7, LYM %=3.6,
HCT=6.9,RBC=1.54,WBC=4.26. CHEM: GGT=35,ALT=814,ALP=311, Total bil=16.8,BUN=93.8.

ULTRASONOGRAPHIC EXAMINATION OF THE ABDOMEN

Urinary System

The urinary bladder is moderately distended with anechoic urine. The Bladder wall, trigone, ureteral papillae and visible urethra (to a depth of 2cm) appear normal with no evidence of wall thickening, mucosal irregularities, masses or cystic calculi.

The left kidney has a normal shape and size (3.75 cm). Overall echogenicity is normal with adequate corticomedullary distinction and a typical 1:3 cortex:medulla ratio. There is no evidence of perinephric inflammation or effusion. There is no evidence of pyelectasia, nephroliths, infarcts or hydroureter. Renal vasculature is normal.

The right kidney has a normal shape and size (4.16 cm). Overall echogenicity is normal with adequate corticomedullary distinction and a typical 1:3 cortex:medulla ratio. There is no evidence of perinephric inflammation or effusion. There is no evidence of pyelectasia, nephroliths, infarcts or hydroureter. Renal vasculature is normal.

Adrenal Glands

The region of left adrenal (Cranial to left renal artery) is unremarkable but the adrenal is not distinctly visualized. No evidence of a mass effect.

The right adrenal gland is normal in size measuring 0.32 cm at the caudal pole. It is observed in its normal position between the cranial aspect of the right kidney and the caudal vena cava. It is normal in appearance (uniformly hypoechoic) and shape with no evidence of a mass effect.

Spleen

The spleen is subjectively normal in size, echotexture is homogenous, and the splenic capsule is smooth with no irregularities. The blood flow through the hilus and splenic parenchyma appears normal. No focal parenchymal abnormalities are visualized.

Liver

The liver is large, irregular, heterogeneous, and hyperechoic. The visible portions of the vasculature and biliary tract appear normal. No focal nodules or cystic lesions are observed.

The gallbladder lumen is moderately distended. The wall of the gall bladder is not thickened and has a smooth mucosal surface. Luminal contents are primarily anechoic. The cystic and common bile ducts are normal/not visible.

Gastrointestinal

The stomach contains minimal luminal contents. It measures at a normal thickness of <0.36cm with some variability due to the presence of rugal folds. The distinction of the gastric wall layers is adequate and there is no impression of reduced peristaltic activity. No masses or focal lesions were observed.

The visualized areas of duodenum, jejunum and ileum have a relatively uniform diameter with minimal fluid distension. Wall thickness is normal. Bowel loops follow a curvilinear path with distinct wall layering maintaining the typical 1:3 muscularis:mucosa layer ratio. The duodenum measured as normal



PATIENT

Hazel Banta

(between 0.13-0.38cm in wall thickness) and the jejunum measured as normal (between 0.15-0.36cm.) Visualized peristalsis appears appropriate. There were no focal lesions consistent with obstruction or a mass effect observed.

SPECIES

Feline

The ileocecal junction was visualized and exhibited normal intact wall layering and is subjectively of normal thickness. Sections of colon are visualized with formed fecal material and gas shadowing distally. There is no observed focal or generalized colon wall thickening or loss of layering.

Pancreas

BREED

DSH

The pancreas is large and hypoechoic to surrounding mesentery. There is no evidence of nodules or cystic lesions. There is evidence of regional mesenteric inflammation. Consistent with moderate pancreatitis.

SEX

Female

Free Abdomen

There is a moderate to large amount of free abdominal fluid. No lymphadenomegaly is visualized. The omentum is of increased echogenicity diffusely.

AGE

7 Years

ULTRASONOGRAPHIC FINDINGS

WEIGHT

12.1 Pounds

- Large hypoechoic, prominent pancreas with surrounding hyperechoic mesentery – The pancreatic changes are most consistent with mild/moderate pancreatitis/pancreatic inflammation. Recommend fPLI testing and continued monitoring for improvement or possible development of a pancreatic abscess. Consider fine needle aspirate if not improving.

- Large, irregular, heterogeneous and hyperechoic liver – Hepatic changes are non-specific and could be consistent with inflammation/infection (cholangiohepatitis), infiltrative neoplasia, lipidosis or other hepatopathy.

- Moderate amount of free abdominal fluid.

INTERPRETED BY

Kathleen Sennello DVM,
MS, Diplomate ACVIM
(Small Animal Internal
Medicine)

INTERPRETATION OF THE FINDINGS & FURTHER RECOMMENDATIONS

There is a moderate amount of free abdominal fluid, and a very large, irregular, heterogeneous liver. No focal lesions are observed. The gallbladder and visual portions of the bile duct appear relatively normal. Findings are most consistent with a primary hepatopathy.

IMAGING PERFORMED BY

Dr. Gordon Brackee

- Recommend a fine needle aspirate, provided coagulation parameters and platelet count allow this safely.
- Recommend 3-view thoracic radiographs.
- Consider cardiac evaluation if heart disease is on your differential list.

HOSPITAL NAME

Bradentown VH

Additionally, the pancreas is hypoechoic and prominent. There is a small amount of surrounding inflammation. Correlate with fPLI levels. Additionally, you could consider a fine needle aspirate of the pancreas, looking for infiltrative disease.

REFERRING VET

Dr. Gordon Brackee

There is a moderate amount of free abdominal fluid. This could be due to congestion (thus the consideration for cardiac evaluation), due to liver disease, carcinomatosis, hypoalbuminemia, etc. Correlate these findings with bloodwork, chest radiographs, and fluid analysis and cytology on a collected sample of abdominal fluid.

INVOICE

39744

If a cytologic diagnosis cannot be obtained based on evaluation of hepatic aspirates and free fluid, then consider surgical biopsies of the liver.

DATE

7/21/22



PATIENT

Hazel Banta

SPECIES

Feline

BREED

DSH

SEX

Female

AGE

7 Years

WEIGHT

12.1 Pounds

INTERPRETED BY

Kathleen Sennello DVM,
MS, Diplomate ACVIM
(Small Animal Internal
Medicine)

**IMAGING
PERFORMED BY**

Dr. Gordon Brackee

HOSPITAL NAME

Bradentown VH

REFERRING VET

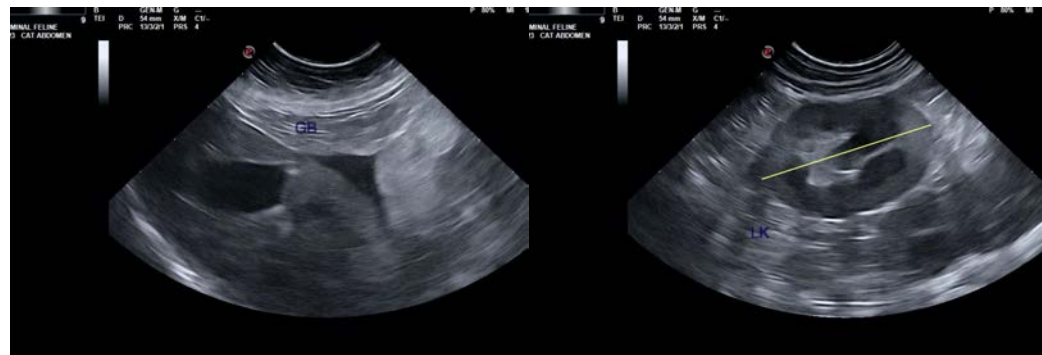
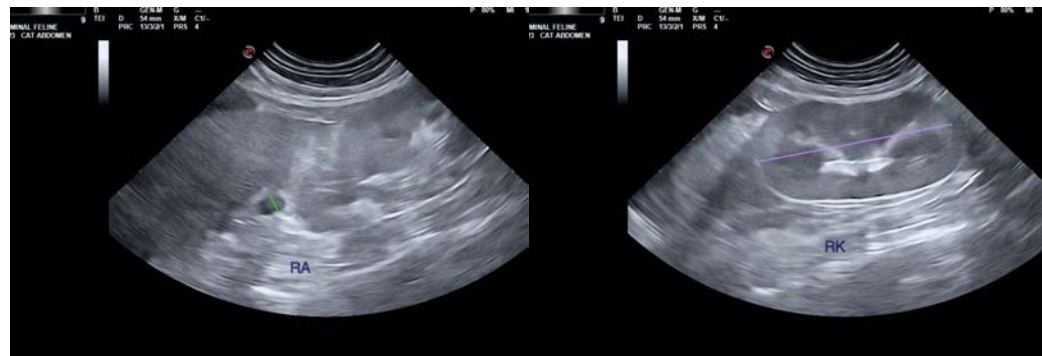
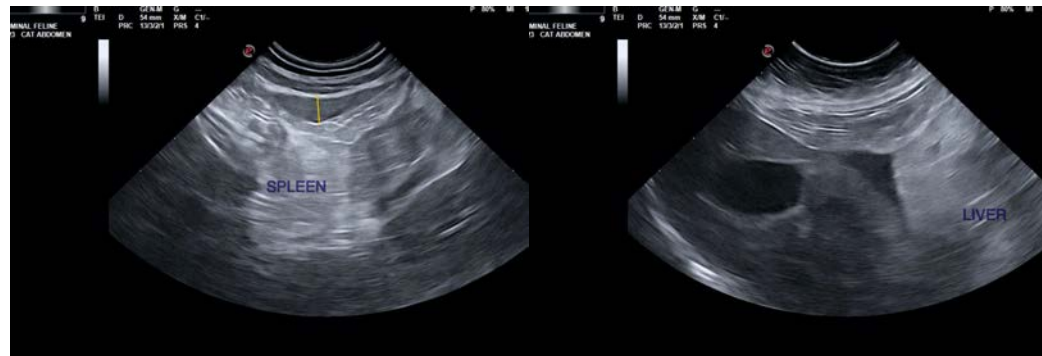
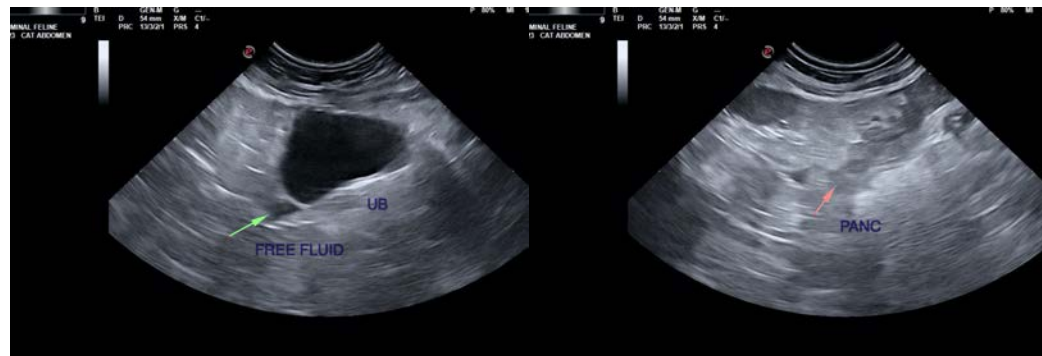
Dr. Gordon Brackee

INVOICE

39744

DATE

7/21/22





PATIENT

Hazel Banta

The information and recommendations provided are based on the images presented by the referring veterinarian/sonographer. No evaluation can be communicated regarding pathology that was not visible in the image/video clips provided.

SPECIES

Feline

Thank you for this referral. If the clinical or image interpretation does not parallel your findings or if I can be of any further assistance please contact me.

Kathleen Sennello DVM,MS, Diplomate ACVIM (Small animal Internal Medicine)

kathleen.sennello@sonopath.com

BREED

DSH

SEX

Female

AGE

7 Years

WEIGHT

12.1 Pounds

INTERPRETED BY

Kathleen Sennello DVM,
MS, Diplomate ACVIM
(Small Animal Internal
Medicine)

**IMAGING
PERFORMED BY**

Dr. Gordon Brackee

HOSPITAL NAME

Bradentown VH

REFERRING VET

Dr. Gordon Brackee

INVOICE

39744

DATE

7/21/22