



PATIENT

Arabella Bonaventura

SPECIES

Feline

BREED

DSH

SEX

Spayed Female

AGE

13 Years

WEIGHT

7.02 kg

INTERPRETED BY

Kathleen Sennello DVM,
MS, Diplomate ACVIM
(Small Animal Internal
Medicine)

IMAGING PERFORMED BY

Dallas Ramberg

HOSPITAL NAME

Lone Mountain AH

REFERRING VET

Dr. Jacquelyn Shoppa

INVOICE

39739

DATE

7/21/22

PRESENTING CLINICAL SIGNS

Patient presented for hematuria of 5 day duration on 6/24/22, was treated unsuccessfully with amoxiclav. She rechecked on 7/11/22 and right nephrolithiasis and ureterolith was noted on radiographs. Hematuria resolved after convenia administration. Urine culture was negative.

Abnormal PE/Chem/CBC/UA Results: USG: 1.020, 2+ protein, 4-10 RBC/hpf, calcium oxalate dihydrate: 0-1, BUN: 36, Cre: 2.1, Glu: 204, Amy: 1348, K: 3.5

ULTRASONOGRAPHIC EXAMINATION OF THE ABDOMEN

Urinary System

The urinary bladder is moderately distended with anechoic urine. The Bladder wall, trigone, ureteral papillae and visible urethra (to a depth of 2cm) appear normal with no evidence of wall thickening, mucosal irregularities, masses or cystic calculi.

The left kidney is normal in size (3.2 cm). It is very irregular in shape with decreased corticomedullary distinction. The irregularity noted is likely due to previous infarcts and scarring. Additionally, there are numerous pinpoint non-obstructive nephroliths visualized, and pyelectasia at 0.19 cm. There is no evidence of hydroureter. Renal vasculature is normal.

The right kidney is normal in size (3.9 cm) and very irregular in shape with decreased corticomedullary distinction. There are numerous small non-obstructive nephroliths visualized, and a suspected nephrolith visualized within the renal pelvis, and mild pyelectasia at 0.23 cm. Additionally, the proximal ureter appears prominent and very mildly dilated at 0.23 cm with a small mineralization measuring 0.26 cm. There is hyperechoic mesentery surrounding the proximal ureter.

Adrenal Glands

The region of left adrenal (Cranial to left renal artery) is unremarkable but the adrenal is not distinctly visualized. No evidence of a mass effect.

The region of the right adrenal (between right cranial kidney and vena cava) is unremarkable, but the adrenal is not distinctly visualized. No evidence of a mass effect.

Spleen

The spleen is subjectively normal in size (0.77 cm in width at the level of the hilus), echotexture is homogenous, and the splenic capsule is smooth with no irregularities. The blood flow through the hilus and splenic parenchyma appears normal. No focal parenchymal abnormalities are visualized.

Liver

The liver is subjectively normal in size, and echogenicity with smooth peripheral margins. The parenchyma is homogenous echotexture. The visible portions of the vasculature and biliary tract appear normal. No focal nodules or cystic lesions are observed.

The gallbladder lumen is moderately distended. The wall of the gall bladder is not thickened and has a smooth mucosal surface. Luminal contents are primarily anechoic. The common bile duct is visualized and appears slightly tortuous, measuring at 0.23 cm.

Gastrointestinal

The stomach contains minimal luminal contents. It measures at a normal thickness of <0.36cm with some variability due to the presence of rugal folds. The distinction of the gastric wall layers is adequate and there is no impression of reduced peristaltic activity. No masses or focal lesions were observed.



PATIENT

Arabella Bonaventura

SPECIES

Feline

BREED

DSH

SEX

Spayed Female

AGE

13 Years

WEIGHT

7.02 kg

INTERPRETED BY

Kathleen Sennello DVM,
MS, Diplomate ACVIM
(Small Animal Internal
Medicine)

**IMAGING
PERFORMED BY**

Dallas Ramberg

HOSPITAL NAME

Lone Mountain AH

REFERRING VET

Dr. Jacquelyn Shoppa

INVOICE

39739

DATE

7/21/22

The visualized areas of duodenum, jejunum and ileum have a uniform diameter with minimal fluid distension. Wall thickness is normal to slightly increased. Bowel loops follow a typical curvilinear path with distinct wall layering, but some areas display a prominent muscularis layer which does not display the typical 1:3 muscularis:mucosa layer ratio. Duodenum wall measured 0.34 cm. Jejunum wall measured 0.27 cm. Visualized peristalsis appears appropriate. There were no focal lesions consistent with obstruction or a mass effect observed.

The ileocecal junction was visualized and exhibited normal intact wall layering and is subjectively of normal thickness. Sections of colon are visualized with formed fecal material and gas shadowing distally. There is no observed focal or generalized colon wall thickening or loss of layering.

Pancreas

The pancreas is prominent and mottled compared to the surrounding isoechoic mesentery. There is no evidence of nodules or cystic lesions. There is no evidence of regional mesenteric inflammation or fluid.

Free Abdomen

Evaluation of the peritoneal cavity did not reveal any evidence of effusion, or subjective lymphadenomegaly. The Medial iliac nodes appear normal and there was no evidence of a caudal aortic thrombus at the bifurcation. The omentum is of normal uniform echogenicity.

PRIMARY FINDINGS

- Large, irregular kidneys with non-obstructive nephroliths and mild pyelectasia – Mild loss of corticomedullary distinction in both kidneys could be consistent with chronic degenerative disease or interstitial nephrosis. Pyelectasia of the left/right kidney could be consistent with pyelonephritis, chronic renal disease, secondary to PU/PD or fluid therapy (if applicable), other. The irregularity noted in the right kidney is likely secondary to previous renal infarcts.
- Suspected nephrolith in the right renal pelvis and proximal right ureter with surrounding inflammation. These are small mineralizations correlating with minimal dilation, so a true obstruction is not evident, although there is inflammation and irritation, and monitoring is warranted.
- Prominent muscularis layer of the small intestine – The small intestinal wall changes are most consistent with an inflammatory process (i.e., inflammatory bowel disease) with a low possibility of emerging lymphoma. This could be a normal finding in older cats.

ULTRASONOGRAPHIC FINDINGS

- Prominent mottled pancreas – The pancreatic changes are most consistent with age-related parenchymal remodeling, potentially secondary to a prior inflammatory episode, early fibrosis or chronic pancreatitis.

INTERPRETATION OF THE FINDINGS & FURTHER RECOMMENDATIONS

Both kidneys are very irregular with decreased corticomedullary distinction. This is likely due to previous infarcts. Additionally, there are small, non-obstructive nephroliths visualized in both kidneys, and a suspected nephrolith visualized in the renal pelvis of the right kidney. Additionally, there is mild proximal ureteral dilation and inflammation with some intraluminal mineralized material. The dilation of the renal pelvis and ureter is very mild, so a completely obstructive process is thought unlikely, but there is associated inflammation, likely pain, possible infection, etc.



PATIENT

Arabella Bonaventura

Recommend urinalysis and culture, blood pressure evaluation, and fluid diuresis with pain medication. Continued monitoring of both kidneys is recommended to look for progressive dilation, which could indicate a true obstruction that may require surgical intervention (suburethral bypass or ureterotomy, etc.). Recommend steps to increase general hydration levels and consider a diet for oxalate stones (the most common provided there is no infection and you're unable to provide a sample stone for analysis).

SPECIES

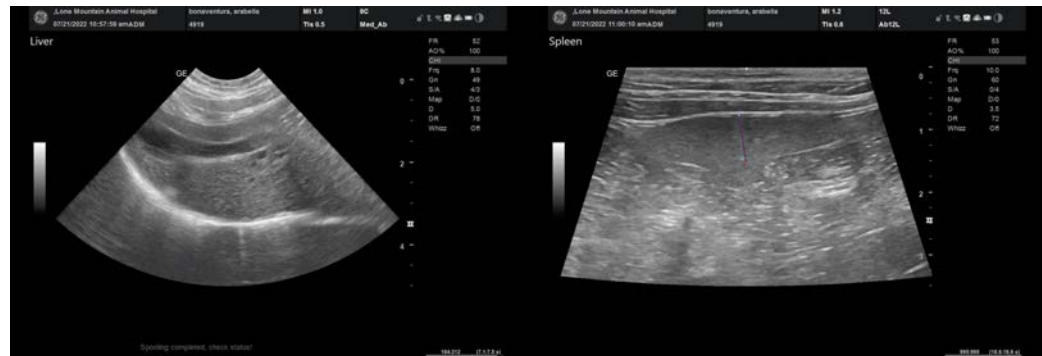Feline

BREED

DSH

SEX

Spayed Female

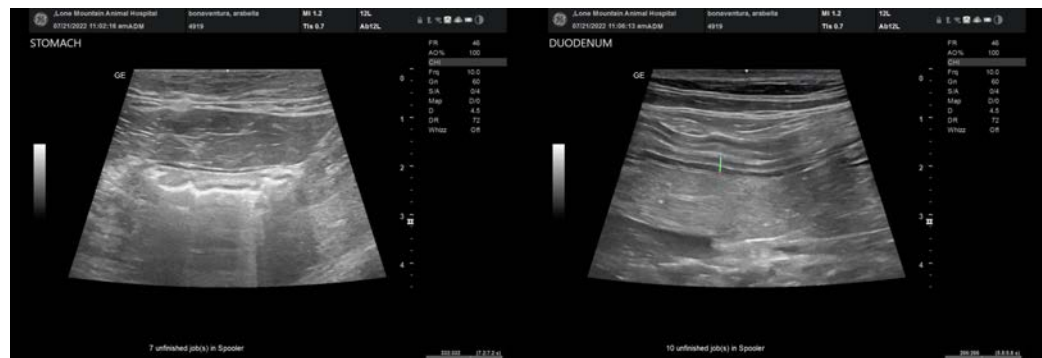

AGE

13 Years

WEIGHT

7.02 kg



INTERPRETED BY

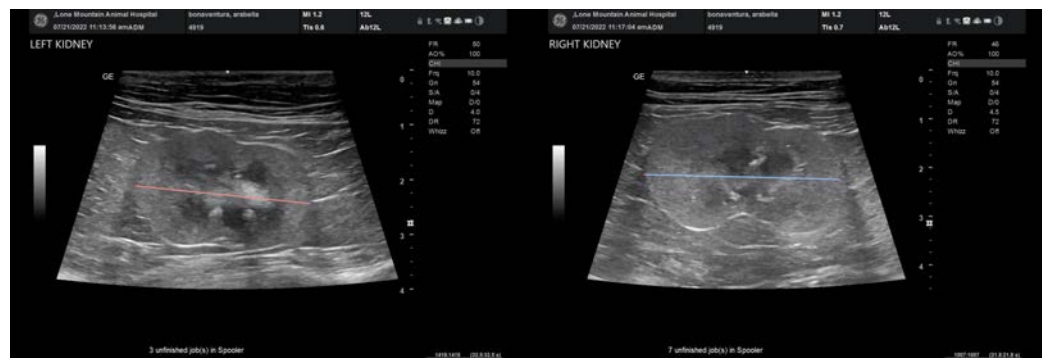Kathleen Sennello DVM, MS, Diplomate ACVIM (Small Animal Internal Medicine)

IMAGING PERFORMED BY

Dallas Ramberg

HOSPITAL NAME

Lone Mountain AH



REFERRING VET

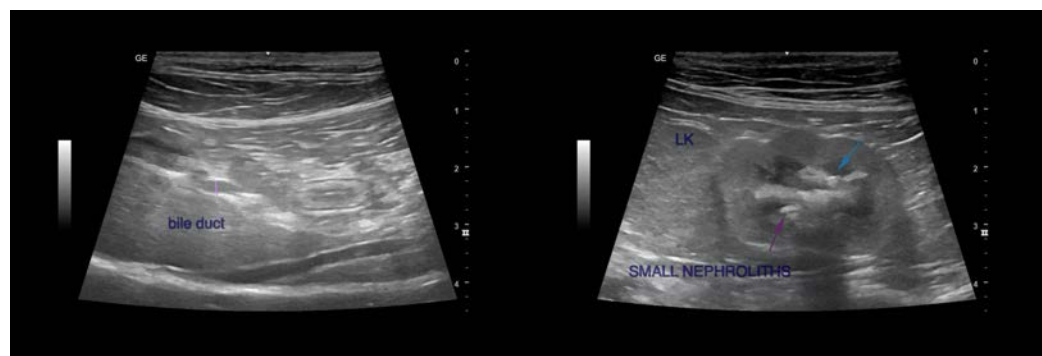
Dr. Jacquelyn Shoppa

INVOICE

39739

DATE

7/21/22





PATIENT

Arabella Bonaventura

SPECIES

Feline

BREED

DSH

SEX

Spayed Female

AGE

13 Years

WEIGHT

7.02 kg

INTERPRETED BY

Kathleen Sennello DVM,
MS, Diplomate ACVIM
(Small Animal Internal
Medicine)

**IMAGING
PERFORMED BY**

Dallas Ramberg

HOSPITAL NAME

Lone Mountain AH

REFERRING VET

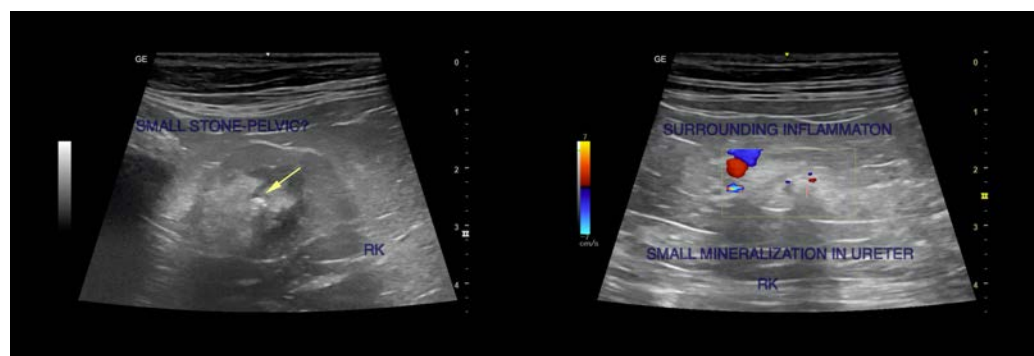
Dr. Jacquelyn Shoppa

INVOICE

39739

DATE

7/21/22



The information and recommendations provided are based on the images presented by the referring veterinarian/sonographer. No evaluation can be communicated regarding pathology that was not visible in the image/video clips provided.

Thank you for this referral. If the clinical or image interpretation does not parallel your findings or if I can be of any further assistance please contact me.

Kathleen Sennello DVM,MS, Diplomate ACVIM (Small animal Internal Medicine)

kathleen.sennello@sonopath.com