

**DATE PRESENTING CLINICAL SIGNS**

7/20/23 Increasing liver values. Losing weight. Occasional vomiting

PATIENT

Teddy Yalowitz

Current Medications: Nutrived/Thyro-tabs 0.2mg, 1 am, 1/2 pm, Apoquel 5.4mg 1SID, Trazodone 100mg 1BID, Adequan inj 1/2cc IM - given weekly, Tramadol 50mg 1/4mg TID - started 07/13/2023
 Carafate 1g 1/4 TID for 10 days, started 06/02/2023. Discontinued medications: Amantadine 45mg SID - stopped within the last 2 months, Meloxicam 1.5mg/mL 0.5mL SID - discontinued due to GI bleeding
 Denamarin 225mg 1 SID - discontinued due to vomiting. NSAID's have increased liver values, so Dr. stopped prescribing.

SPECIES

Canine

Lab Results: See attached.

Radiographs: See attached.

BREED

Bichon

Date of Previous IntraPet Ultrasound: 12/16/22. See attached.

Sedation: Not required to complete full diagnostic ultrasound.

Stat Report: Not requested.

Imaging Performed By: Rachel Brillhart, RDMS.

SEX

Neutered Male

ULTRASONOGRAPHIC EXAMINATION OF THE ABDOMEN**Urinary System****AGE**

8/5/08

The urinary bladder is moderately distended with anechoic urine. The Bladder wall, trigone, ureteral papillae and visible urethra (to a depth of 2cm) appear normal with no evidence of wall thickening, mucosal irregularities, or masses. There is a small hyperechoic shadowing focus in the dependent portion of the urinary bladder, most consistent with a stone or small pile of mineralized debris, measuring 1.03 cm (this is similar to the 1.0 cm mineralization noted on the previous scan 12/2022).

WEIGHT

16.2 Pounds

The visualized areas of prostate and surrounding tissue appear normal. Unfortunately, the prostate is not fully visualized likely due to its intrapelvic location. Correlate with rectal exam findings.

INTERPRETED BY

Kathleen Sennello DVM,
 MS, Diplomate ACVIM
 (Small Animal Internal
 Medicine)

The left kidney has a normal shape and size (4.59 cm) with pyelectasia at 0.46 cm and numerous small non-obstructive nephroliths, one of which measures 0.31 cm. Overall echogenicity is slightly hyperechoic with poor corticomedullary distinction and a typical 1:3 cortex:medulla ratio. There is no evidence of focal perinephric inflammation or effusion. There is no evidence of infarcts or hydroureter. Renal vasculature is normal.

HOSPITAL NAME

AMC of Dulaney Valley

The right kidney has a normal shape and size (4.9 cm) with pyelectasia at 0.46 cm and a non-obstructive nephrolith visualized at 0.26 cm. Overall echogenicity is slightly hyperechoic with poor corticomedullary distinction and a typical 1:3 cortex:medulla ratio. There is no evidence of focal perinephric inflammation or effusion. There is no evidence of infarcts or hydroureter. Renal vasculature is normal.

REFERRING VET

Dr. Chrest

Adrenal Glands**INVOICE**

44200

The left adrenal gland is normal in size measuring 0.73 cm at the caudal pole. It is observed in its normal position cranial to the left renal artery. It is normal in appearance (uniformly hypoechoic) and shape with no evidence of a mass effect.

The right adrenal gland is normal in size measuring 0.60 cm at the caudal pole. It is observed in its normal position between the cranial aspect of the right kidney and the caudal vena cava. It is normal in appearance (uniformly hypoechoic) and shape with no evidence of a mass effect.

Spleen

The spleen is subjectively normal in size, echotexture is homogenous, and the splenic capsule is smooth with no irregularities. The blood flow through the hilus and splenic parenchyma appears normal. No focal parenchymal abnormalities are visualized.

Liver

The liver is large in size, and normal in echogenicity with smooth peripheral margins. The parenchyma is heterogenous in echotexture with subtle, indistinct focal mottling. The visible portions of the vasculature and biliary tract appear normal. There are some very ill-defined hypo- and hyperechoic nodules visualized within the parenchyma. The previously described left-sided hyperechoic cystic lesion is not visualized on today's exam.

The gall bladder lumen is moderately distended. The wall of the gall bladder is not thickened and has a smooth mucosal surface. There is a moderate amount of non-organized echogenic debris. The cystic and common bile ducts are normal/not visible.

Gastrointestinal

The stomach contains minimal luminal contents. It measures at a normal thickness of <0.7cm with some variability due to the presence of rugal folds. The distinction of the gastric wall layers is adequate and there is no impression of reduced peristaltic activity. No masses or focal lesions were observed.

The visualized areas of duodenum, jejunum and ileum have a relatively uniform diameter with minimal fluid distension. Wall thickness is normal. Bowel loops follow a curvilinear path with distinct wall layering maintaining the typical 1:3 muscularis:mucosa layer ratio. Jejunum wall measures 0.22 cm. Visualized peristalsis appears appropriate. There were no focal lesions consistent with obstruction or a mass effect observed.

The ileocecal junction was visualized and exhibited normal intact wall layering and is subjectively of normal thickness. Sections of colon are visualized with formed fecal material and gas shadowing distally. There is no observed focal or generalized colon wall thickening or loss of layering.

Pancreas

The pancreas is large, prominent and mottled compared to the surrounding isoechoic mesentery. There is no evidence of nodules or cystic lesions. There is no evidence of regional mesenteric inflammation or fluid.

Free Abdomen

Evaluation of the peritoneal cavity did not reveal any evidence of effusion, or subjective lymphadenomegaly. The Medial iliac nodes appear normal and there was no evidence of a caudal aortic thrombus at the bifurcation. The omentum is of normal uniform echogenicity.

ULTRASONOGRAPHIC FINDINGS

- Focal mineralization visualized in the urinary bladder – Findings are most consistent with a bladder stone. Recommend urinalysis and culture.
- Decreased corticomedullary distinction in both kidneys with bilateral pyelectasia and numerous non-obstructive nephroliths – Mild loss of corticomedullary distinction in both kidneys could be consistent with chronic degenerative disease or interstitial nephrosis. The diffusely hyperechoic mesentery and abdominal effusion are changes consistent with peritonitis (either infectious or inflammatory). Recommend fluid analysis and culture.

- Prominent, mottled pancreas – The pancreatic changes are most consistent with mild pancreatitis or a recent episode of pancreatic inflammation.
- Large, heterogeneous liver with ill-defined nodules – The diffuse hepatic changes are non-specific and could be consistent with vacuolar hepatopathy, nodular hyperplasia, inflammatory/immune-mediated disease, fibrosis, extramedullary hematopoiesis, toxic hepatopathy (e.g., copper), infiltrative neoplasia (less likely) or other hepatopathy. The nodules observed trend toward a more benign process but underlying neoplasia cannot be ruled out.
- Moderate gallbladder debris – The significance of the aggregated gallbladder debris is unclear. This could represent an early mucocele, cholestasis, or may be secondary to fasting but seems unlikely to be causing a current issue. Recommend continued monitoring.

INTERPRETATION OF THE FINDINGS & FURTHER RECOMMENDATIONS

The findings on today's scan are similar to those identified in the scan performed 12/2022. No significant progression of the liver lesions is observed.

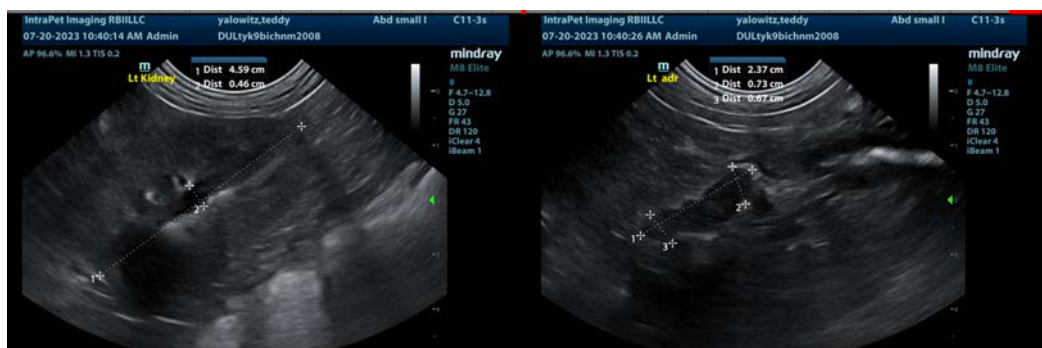
The pancreas questionably appears more prominent on today's exam. Correlate with a quantitative cPLI level. If there are no GI symptoms, the significance of this is uncertain.

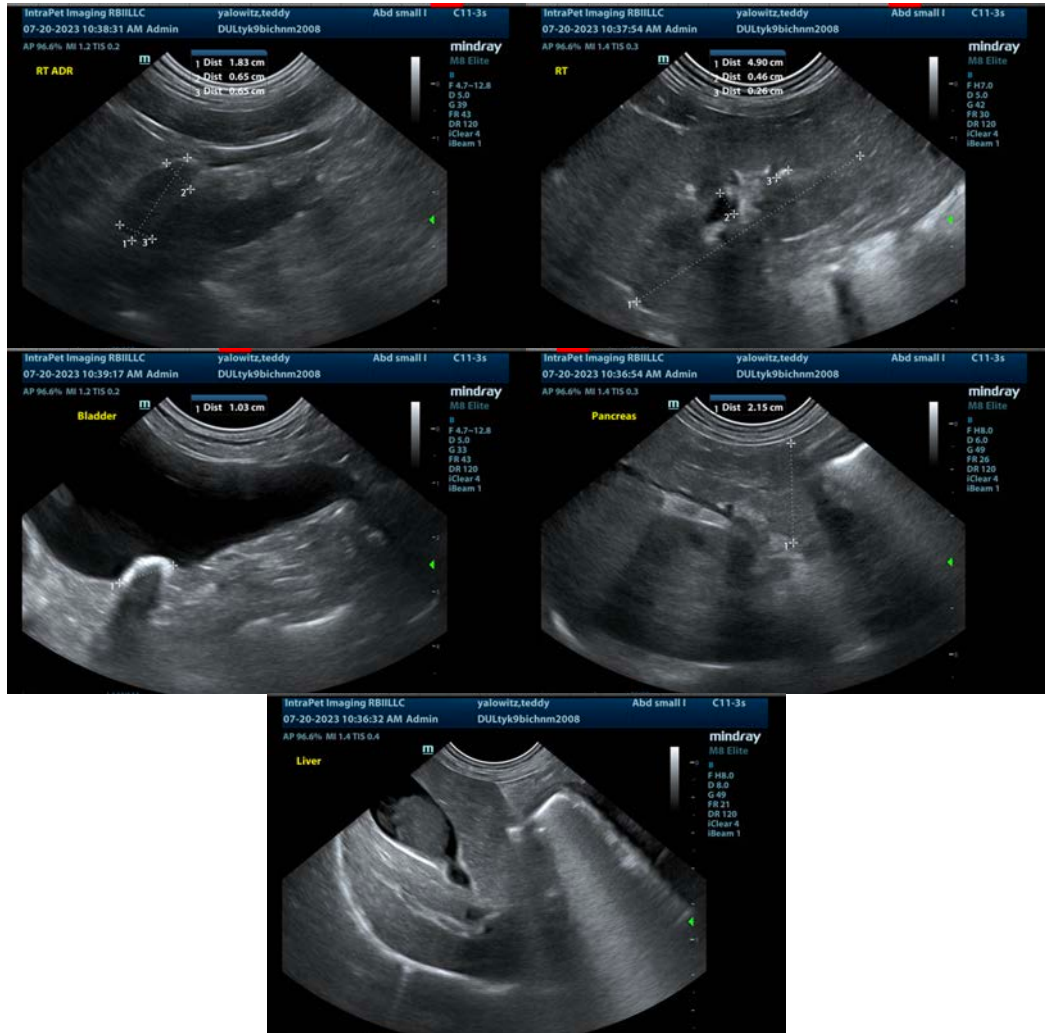
Recommendations for today's exam would be similar to those previously identified, including a liver function test, possibly a fine needle aspirate of the liver.

Based on the changes in the kidneys, I would recommend a blood pressure, urinalysis and culture.

If weight loss is persistent and there is no significant liver dysfunction, etc., you could have underlying gastrointestinal disease. If there are symptoms consistent with gastrointestinal disease, you could consider a GI panel to Texas A&M for a qualitative PLI, TLI, cobalamin and folate to further evaluate.

Recommend three view thoracic radiographs to evaluate for possible concurrent thoracic disease/involvement.





The information and recommendations provided are based on the images presented by the referring veterinarian/sonographer. No evaluation can be communicated regarding pathology that was not visible in the image/video clips provided.

Thank you for this referral. If the clinical or image interpretation does not parallel your findings or if I can be of any further assistance please contact me.

Kathleen Sennello DVM,MS, Diplomate ACVIM (Small animal Internal Medicine)
info@sonopath.com