

**DATE PRESENTING CLINICAL SIGNS**

7/20/23

Hx of mild weight loss, decreased appetite from usually ravenous, increased thirst, chronic diarrhea- made mildly improved with Prednisone, pot bellied appearance/bloated.

PATIENT

Stewey Benjamin Moore

Current Medications: Prednisone.

Lab Results: See attached.

Radiographs: Concern for loss of serosal detail/possible mass effect mid abdomen.

Date of Previous IntraPet Ultrasound: No previous.

SPECIES

Canine

Sedation: Not required to complete full diagnostic ultrasound.

Stat Report: Not requested.

Imaging Performed By: Stephanie Warga RDCS, RVT.

BREED

Poodle X

ULTRASONOGRAPHIC EXAMINATION OF THE ABDOMEN**SEX**

Neutered Male

Urinary System

The urinary bladder is moderately distended with anechoic urine. The Bladder wall, trigone, ureteral papillae and visible urethra (to a depth of 2cm) appear normal with no evidence of wall thickening, mucosal irregularities, masses or cystic calculi.

AGE

11/23/08

The prostate is normal in size (0.53 cm) and shape for this neutered male dog. The parenchyma is homogenous and the external margins are smooth. The prostatic urethra appears normal with no evidence of irregularity, invasion, mass effect or calculi.

WEIGHT

12.5 Pounds

The left kidney has a normal shape and size (4.14 cm). Overall echogenicity is normal with adequate corticomedullary distinction and a typical 1:3 cortex:medulla ratio. There is no evidence of focal perinephric inflammation or effusion. There is no evidence of pyelectasia, nephroliths, infarcts or hydroureter. Renal vasculature is normal.

INTERPRETED BY

Kathleen Sennello DVM,
MS, Diplomate ACVIM
(Small Animal Internal
Medicine)

The right kidney has a normal shape and size (3.75 cm). Overall echogenicity is normal with adequate corticomedullary distinction and a typical 1:3 cortex:medulla ratio. There is no evidence of focal perinephric inflammation or effusion. There is no evidence of pyelectasia, nephroliths, infarcts or hydroureter. Renal vasculature is normal.

HOSPITAL NAME

Bayside AMC

Adrenal Glands

The left adrenal gland is normal in size measuring 0.51 cm at the caudal pole. It is observed in its normal position cranial to the left renal artery. It is normal in appearance (uniformly hypoechoic) and shape with no evidence of a mass effect.

REFERRING VET

Dr. Buchanan

The right adrenal gland is normal in size measuring 0.39 cm at the caudal pole. It is observed in its normal position between the cranial aspect of the right kidney and the caudal vena cava. It is normal in appearance (uniformly hypoechoic) and shape with no evidence of a mass effect.

INVOICE

44215

Spleen

The spleen is subjectively normal in size, echotexture is homogenous, and the splenic capsule is smooth with no irregularities. The blood flow through the hilus and splenic parenchyma appears normal. No focal parenchymal abnormalities are visualized.

Liver

The liver is subjectively normal in size, and echogenicity with smooth peripheral margins. The parenchyma is homogenous echotexture. The visible portions of the vasculature and biliary tract appear normal. No focal nodules or cystic lesions are observed.

The gallbladder lumen is moderately distended. The wall of the gall bladder is not thickened and has a smooth mucosal surface. Luminal contents are mild and primarily anechoic. The cystic and common bile ducts are normal/not visible.

Gastrointestinal

The stomach contains minimal luminal contents. It measures at a normal thickness of <0.7cm with some variability due to the presence of rugal folds. The distinction of the gastric wall layers is adequate and there is no impression of reduced peristaltic activity. No masses or focal lesions were observed.

The visualized areas of duodenum, jejunum and ileum have a uniform diameter with minimal fluid distension. Wall thickness is increased. Bowel loops follow a typical curvilinear path. Some areas have reduced detail of wall layering. Duodenum wall measures 0.53 cm. Jejunum wall measures 0.40 cm. There is mucosal speckling and fogging evident. Visualized peristalsis appears appropriate. There were no focal lesions consistent with obstruction or a mass effect observed.

The ileocecal junction was visualized and exhibited normal intact wall layering and is subjectively of normal thickness. In the region of the descending colon the colon is distended with non-formed fecal material.

Pancreas

The area of the pancreas is normal and isoechoic to surrounding mesentery. There is no evidence of nodules or cystic lesions. There is no evidence of regional mesenteric inflammation or fluid.

Free Abdomen

Scant free abdominal fluid is noted. No significant lymphadenopathy is noted, but there is diffusely hyperechoic mesentery.

ULTRASONOGRAPHIC FINDINGS

- Diffusely thickened small intestine with mucosal speckling and fogging evident – The bowel wall thickening could be consistent with inflammation, edema, or infiltrative neoplasia. Bright mucosal speckling has been postulated to represent dilated lacteals or focal accumulations of mucus, cellular debris, etc.. in the mucosal crypts.
- Fluid distended colon – Findings are consistent with the reported diarrhea.
- Scant free abdominal fluid and hyperechoic mesentery

INTERPRETATION OF THE FINDINGS & FURTHER RECOMMENDATIONS

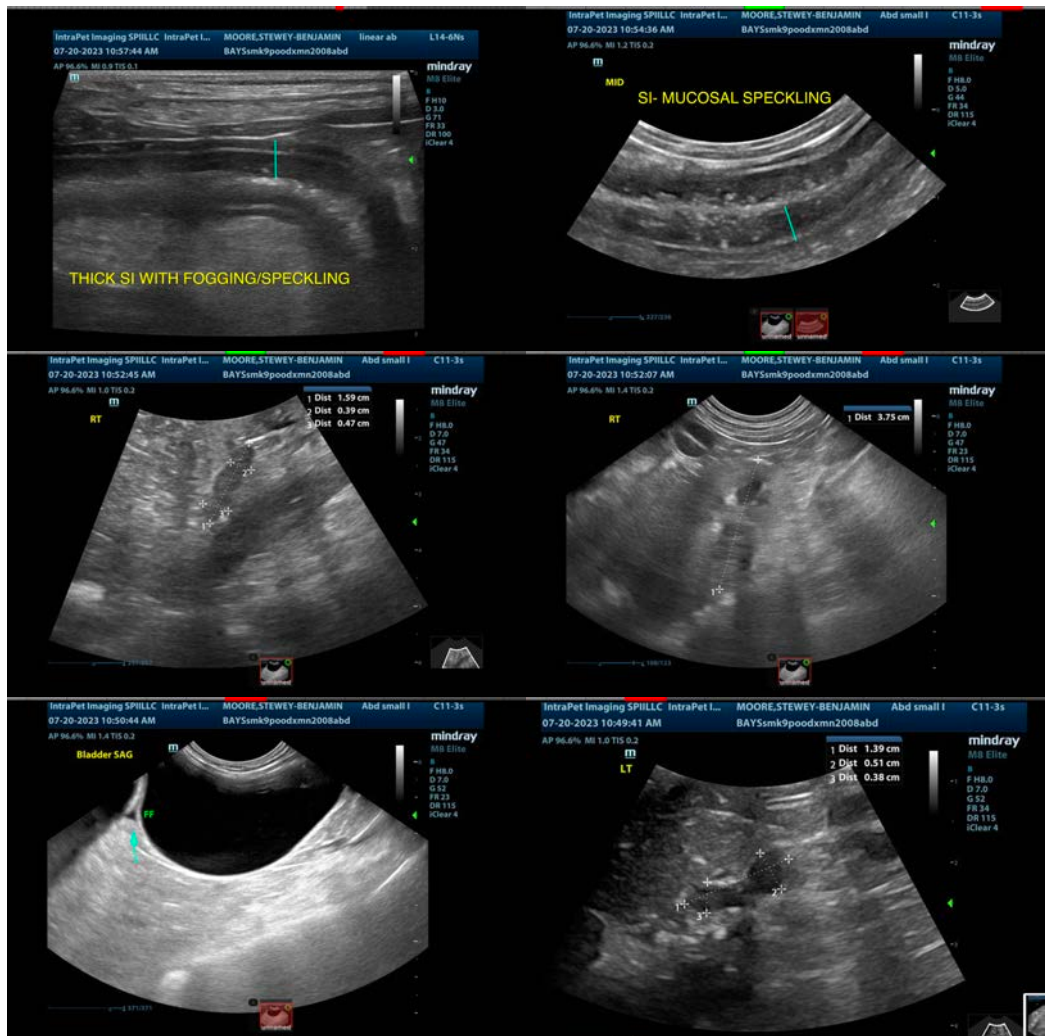
The small bowel appears diffusely thickened with speckling and fogging of the mucosa, most consistent with a primary enteropathy. There are many possible differentials. Of primary concern would be severe IBD, intestinal lymphangiectasia, intestinal neoplasia, etc. These would all be differentiated based on GI biopsies. Consider the following:

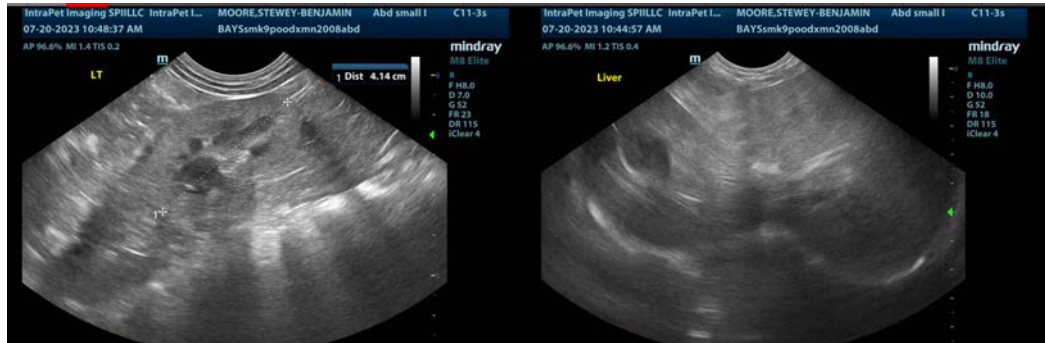
- Consider a novel protein/hydrolyzed protein diet (exclusively at least 4-6 weeks)

- Consider a GI panel to Texas A&M for evaluation of B12 levels, folate, PLI/TLI etc.. to further evaluate for pancreatic/small intestinal disease.
- Recommend chronic probiotic therapy.

If GI biopsies are considered, recommend endoscopic biopsies and efforts to taper off the steroids prior to obtaining biopsies, as this can mask both ultrasonographic changes and histologic changes of primary gastrointestinal disease.

Recommend three view thoracic radiographs to evaluate for possible concurrent thoracic disease/involvement.





The information and recommendations provided are based on the images presented by the referring veterinarian/sonographer. No evaluation can be communicated regarding pathology that was not visible in the image/video clips provided.

Thank you for this referral. If the clinical or image interpretation does not parallel your findings or if I can be of any further assistance please contact me.

Kathleen Sennello DVM,MS, Diplomate ACVIM (Small animal Internal Medicine)
info@sonopath.com