

**DATE PRESENTING CLINICAL SIGNS**

7/20/23

Pet presented for appt on 05/10/2023. P presents for GI concerns. O states P has been having blood in their stool for 1-2 months. O also states P vomited yesterday and it had a red appearance. Pet has gotten into the dog food but has not eaten anything else unusual that owner knows of. P has been eating and drinking normal. P is indoor only. Pet was treated symptomatically, offered radiographs and o declined.

PATIENT

Otis Pumphrey

Pet presented for dental cleaning today and o stated he is still having blood in stool, strains to defecate 2 lbs weight loss in 2 months

SPECIES

Feline

Current Medications: None.

Lab Results: cbc/iof/T4: wnl

Date of Previous IntraPet Ultrasound: No previous.

BREED

DSH

Sedation: Not required to complete full diagnostic ultrasound.

Stat Report: Not requested.

Imaging Performed By: Rachel Brillhart, RDMS.

SEX

Neutered Male

ULTRASONOGRAPHIC EXAMINATION OF THE ABDOMEN**Urinary System**

The urinary bladder is moderately distended with mild primarily suspended echogenic debris present. The Bladder wall, trigone, ureteral papillae and visible urethra (to a depth of 2cm) appear normal with no evidence of wall thickening, mucosal irregularities, or masses. Echogenic debris of this type can be associated with small crystals, cellular debris and proteinaceous debris. In the dependent portion of the urinary bladder, there is a small line of shadowing hyperechoic debris, most consistent with sandy/mineralized debris.

AGE

6/16/21

WEIGHT

4.81 kg

The left kidney has a normal shape and size (4.21 cm) with a small cortical mineralization measuring 0.30 cm. Overall echogenicity is normal with adequate corticomedullary distinction and a typical 1:3 cortex:medulla ratio. There is no evidence of focal perinephric inflammation or effusion. There is no evidence of pyelectasia, nephroliths, infarcts or hydroureter. Renal vasculature is normal.

INTERPRETED BY

Kathleen Sennello DVM,
MS, Diplomate ACVIM
(Small Animal Internal
Medicine)

The right kidney has a normal shape and size (4.18 cm). Overall echogenicity is normal with adequate corticomedullary distinction and a typical 1:3 cortex:medulla ratio. There is no evidence of focal perinephric inflammation or effusion. There is no evidence of pyelectasia, nephroliths, infarcts or hydroureter. Renal vasculature is normal.

HOSPITAL NAME

BPH Towson

Adrenal Glands

The left adrenal gland is normal in size measuring 0.44 cm at the caudal pole. It is observed in its normal position cranial to the left renal artery. It is normal in appearance (uniformly hypoechoic) and shape with no evidence of a mass effect.

REFERRING VET

Dr. Chadha

The right adrenal gland is normal in size measuring 0.41 cm at the caudal pole. It is observed in its normal position between the cranial aspect of the right kidney and the caudal vena cava. It is normal in appearance (uniformly hypoechoic) and shape with no evidence of a mass effect.

INVOICE

44202

Spleen

The spleen is subjectively normal in size (1.0 cm), echotexture is homogenous, and the splenic capsule is smooth with no irregularities. The blood flow through the hilus and splenic parenchyma appears normal. No focal parenchymal abnormalities are visualized.

Liver

The liver is subjectively normal in size, and echogenicity with smooth peripheral margins. The parenchyma is homogenous echotexture. The visible portions of the vasculature and biliary tract appear normal. No focal nodules or cystic lesions are observed.

The gallbladder lumen is moderately distended. The wall of the gall bladder is not thickened and has a smooth mucosal surface. Luminal contents are mild and primarily anechoic. The cystic and common bile ducts are normal/not visible.

Gastrointestinal

The stomach contains minimal luminal contents. It measures at a normal thickness of <0.36cm with some variability due to the presence of rugal folds. The distinction of the gastric wall layers is adequate and there is no impression of reduced peristaltic activity. No masses or focal lesions were observed.

The visualized areas of duodenum, jejunum and ileum have a relatively uniform diameter with minimal fluid distension. Wall thickness is normal. Bowel loops follow a curvilinear path with distinct wall layering maintaining the typical 1:3 muscularis:mucosa layer ratio. Jejunum wall measures 0.41 cm. Visualized peristalsis appears appropriate. There were no focal lesions consistent with obstruction or a mass effect observed.

The area of the ileocecal junction was visualized with no apparent thickening and intact wall layering. More distally at the level of the cystourethral junction the colon appears severely irregular and thickened with asymmetrical wall thickening of 0.64 cm, creating a mass effect. This abnormal area of colon measures 3.52 cm in length and 1.36 cm in diameter. The colon proximal to this irregular area measures at 0.26 cm with intact wall layering.

Pancreas

The area of the pancreas is normal and isoechoic to surrounding mesentery. There is no evidence of nodules or cystic lesions. There is no evidence of regional mesenteric inflammation or fluid.

Free Abdomen

Evaluation of the peritoneal cavity did not reveal any evidence of effusion. There are prominent mesenteric lymph nodes in the abdomen, particularly at the ileocecal junction, with lymph nodes measuring at 0.40 cm and 0.36 cm, and a larger colonic lymph node measuring 0.79 cm x 1.45 cm. The omentum is of normal echogenicity.

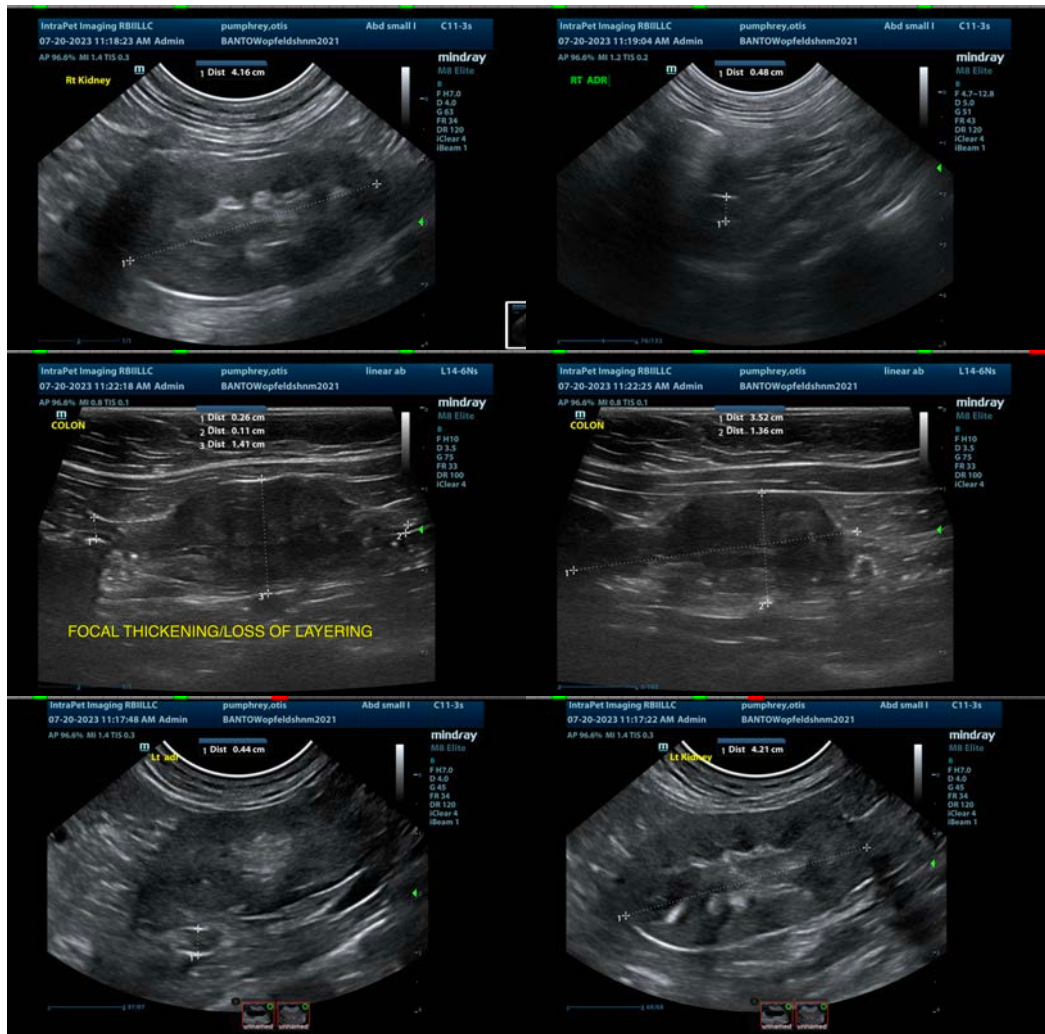
ULTRASONOGRAPHIC FINDINGS

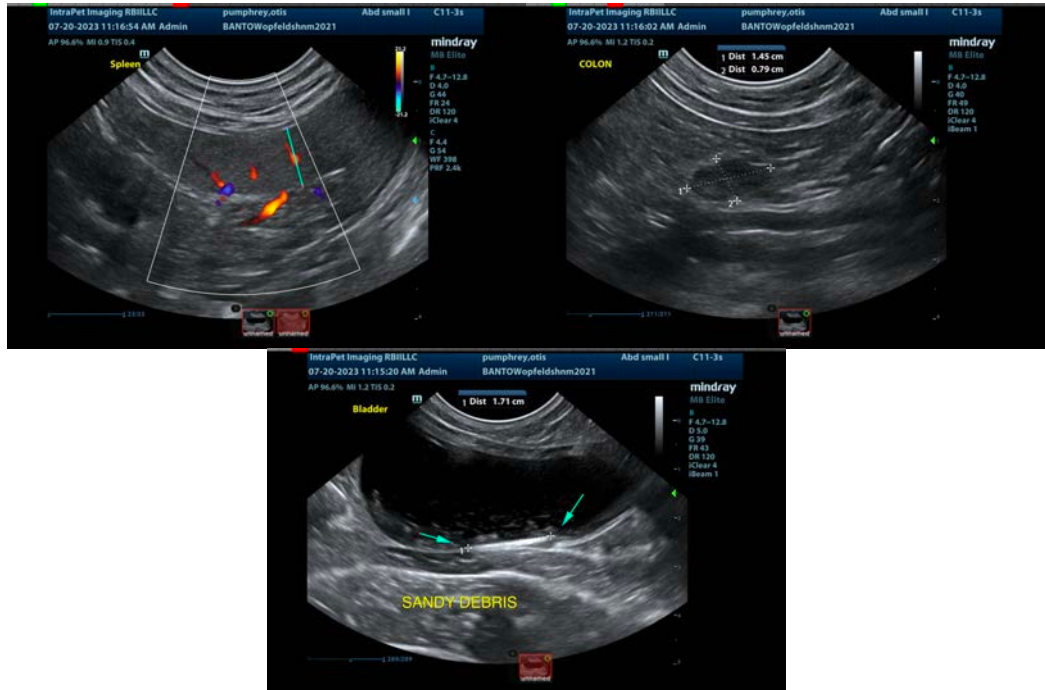
- Echogenic/sandy debris in the dependent portion of the urinary bladder – Recommend urinalysis and culture.
- Focal irregular thickening of the distal descending colon with complete loss of wall layering – Findings are concerning for a colonic wall mass. This could be benign, neoplastic, or infectious/inflammatory lesion.
- Enlarged colonic lymph node – This could represent a reactive or metastatic lymph node.

INTERPRETATION OF THE FINDINGS & FURTHER RECOMMENDATIONS

There is a severely thickened, irregular area of distal colon, which is likely responsible for the reported hematochezia. This lesion is concerning for infiltrative disease. This could represent a neoplastic or benign lesion. Additionally, FIP or some other infectious/inflammatory conditions could present this way. Recommend a fine needle aspirate of the distal colonic mass if possible. If not, consider a colonoscopy for further evaluation and biopsies. If surgical resection is considered, a contrast CT scan is strongly recommended to try and further evaluate the extent of this lesion for surgical planning.

Recommend three view thoracic radiographs to evaluate for possible concurrent thoracic disease/involvement.





The information and recommendations provided are based on the images presented by the referring veterinarian/sonographer. No evaluation can be communicated regarding pathology that was not visible in the image/video clips provided.

Thank you for this referral. If the clinical or image interpretation does not parallel your findings or if I can be of any further assistance please contact me.

Kathleen Sennello DVM,MS, Diplomate ACVIM (Small animal Internal Medicine)
info@sonopath.com