



**PATIENT**

Brighia Hannon

**PRESENTING CLINICAL SIGNS**

PU/PD - drinking a lot of water per owner.

**SPECIES**

Canine

Abnormal PE/Chem/CBC/UA Results: T4 0.7 but free T4 normal; UA: pH 8.5, WBC 4-10/hpf, microalbumin 3.6, USPG 1.007

**BREED**

Beagle

**ULTRASONOGRAPHIC EXAMINATION OF THE ABDOMEN**

**Urinary System**

The urinary bladder is moderately distended with anechoic urine. The Bladder wall, trigone, ureteral papillae and visible urethra (to a depth of 2cm) appear normal with no evidence of wall thickening, mucosal irregularities, masses or cystic calculi.

**SEX**

Spayed Female

The left kidney has a normal shape and size (5.18 cm) with small cortical mineralizations. Overall echogenicity is normal with adequate corticomedullary distinction and a typical 1:3 cortex:medulla ratio. There is no evidence of focal perinephric inflammation or effusion. There is no evidence of pyelectasia, nephroliths, infarcts or hydroureter. Renal vasculature is normal.

**AGE**

8 Years

**WEIGHT**

27.3 Pounds

The right kidney has a normal shape and size (6.21 cm) with occasional small cortical mineralizations. Overall echogenicity is normal with adequate corticomedullary distinction and a typical 1:3 cortex:medulla ratio. There is no evidence of focal perinephric inflammation or effusion. There is no evidence of pyelectasia, nephroliths, infarcts or hydroureter. Renal vasculature is normal.

**INTERPRETED BY**

Kathleen Sennello DVM,  
MS, Diplomate ACVIM  
(Small Animal Internal  
Medicine)

**Adrenal Glands**

The left adrenal gland is normal in size measuring 0.58 cm at the caudal pole. It is observed in its normal position cranial to the left renal artery. It is normal in appearance (uniformly hypoechoic) and shape with no evidence of a mass effect.

**IMAGING PERFORMED BY**

Diane McFadden

The right adrenal gland is normal in size measuring 0.59 cm at the caudal pole. It is observed in its normal position between the cranial aspect of the right kidney and the caudal vena cava. It is normal in appearance (uniformly hypoechoic) and shape with no evidence of a mass effect.

**HOSPITAL NAME**

Newton Vet Hospital

**Spleen**

The spleen is subjectively normal in size, echotexture is homogenous, and the splenic capsule is smooth with no irregularities. The blood flow through the hilus and splenic parenchyma appears normal. No focal parenchymal abnormalities are visualized.

**REFERRING VET**

Dr. Wyman-Greenwald

**Liver**

The liver is subjectively normal in size, and echogenicity with smooth peripheral margins. The parenchyma is homogenous echotexture. The visible portions of the vasculature and biliary tract appear normal. No focal nodules or cystic lesions are observed.

**INVOICE**

44183

The gall bladder lumen is moderately distended. The wall of the gall bladder is not thickened and has a smooth mucosal surface. There is a moderate amount of non-organized echogenic debris. The cystic and common bile ducts are normal/not visible.

**DATE**

7/20/23



**PATIENT** *Gastrointestinal*

**Brighia Hannon**  
The stomach contains moderate ingesta. It measures at a normal thickness of <0.7cm with some variability due to the presence of rugal folds. The distinction of the gastric wall layers is adequate and there is no impression of reduced peristaltic activity. No masses or focal lesions were observed.

**SPECIES**

**Canine**  
The visualized areas of duodenum, jejunum and ileum have a relatively uniform diameter with minimal fluid distension. Wall thickness is normal. Bowel loops follow a curvilinear path with distinct wall layering maintaining the typical 1:3 muscularis:mucosa layer ratio. The duodenum measured as normal (between 0.3-0.5cm in wall thickness) and the jejunum measured as normal (between 0.2-0.47cm.)

**BREED**

**Beagle**  
Visualized peristalsis appears appropriate. There were no focal lesions consistent with obstruction or a mass effect observed.

**SEX**

**Spayed Female**  
The ileocecal junction was visualized and exhibited normal intact wall layering and is subjectively of normal thickness. Sections of colon are visualized with formed fecal material and gas shadowing distally. There is no observed focal or generalized colon wall thickening or loss of layering.

**AGE**

**8 Years**

**Pancreas**

The pancreas is normal and isoechoic to surrounding mesentery. There is no evidence of nodules or cystic lesions. There is no evidence of regional mesenteric inflammation or fluid.

**WEIGHT**

**27.3 Pounds**

**Free Abdomen**

Evaluation of the peritoneal cavity did not reveal any evidence of effusion, or subjective lymphadenomegaly. The Medial iliac nodes appear normal and there was no evidence of a caudal aortic thrombus at the bifurcation. The omentum is of normal uniform echogenicity.

**INTERPRETED BY**

**Kathleen Sennello DVM, MS, Diplomate ACVIM (Small Animal Internal Medicine)**

**ULTRASONOGRAPHIC FINDINGS**

- Moderate gallbladder debris – The significance of the aggregated gallbladder debris is unclear. This could represent an early mucocele, cholestasis, or may be secondary to fasting but seems unlikely to be causing a current issue. Recommend continued monitoring.
- Moderate ingesta within the gastric lumen – Findings are most consistent with a non-fasted patient.

**IMAGING PERFORMED BY**

**Diane McFadden**

**HOSPITAL NAME**

**Newton Vet Hospital**

**INTERPRETATION OF THE FINDINGS & FURTHER RECOMMENDATIONS**

An obvious lesion responsible for the reported increase in thirst and urination was not visualized. Some issues such as early renal disease, Cushing’s disease, behavioral, neurologic, dietary, electrolyte disturbances etc.. are not able to be diagnosed with ultrasound alone. These can be challenging cases. The top 10 differentials can be ruled in/out with routine bloodwork, urinalysis and culture, several more can be evaluated with a good history and imaging. Unfortunately, as you work your way down the list the differentials become harder to definitively diagnose. This is the differential list I start with.

**REFERRING VET**

**Dr. Wyman-Greenwald**

**INVOICE**

**44183**

**DATE**

**7/20/23**

1. Diabetes Mellitus
2. Chronic Renal Disease/Renal Failure (can present pre-azotemic, especially in dogs, but expect the BUN & creatinine not to be at the low end of the reference range)
3. Hypercalcemia
4. Urinary tract infection



**PATIENT**

Brighia Hannon

**SPECIES**

Canine

**BREED**

Beagle

**SEX**

Spayed Female

**AGE**

8 Years

**WEIGHT**

27.3 Pounds

5. Iatrogenic Disease due to medications (diuretics, phenobarbital, KBr; diets either high in salt [such as S/D] or very low in protein (such as U/D))
6. Hyperthyroidism
7. Hypokalemia
8. Liver Disease (hepatic encephalopathy may be a mixed primary PU and PD)
9. Pyelonephritis
10. Polycythemia
11. Renal Tubular Diseases (glycosuria or Fanconi & Fanconi-like syndromes or RTA)
12. Hyperadrenocorticism (may be a mixed primary PU and PD)
13. Hypoadrenocorticism (either Addison's or hypocortisolism)
14. Paraneoplastic Syndromes (particularly splenic hemangiosarcoma?)
15. Pericardial Effusion
16. Pyometra (including stump pyometra in spayed dogs)
17. Chronic Partial Urinary Obstruction or Post-Obstructive Diuresis
18. Pheochromocytoma
19. Psychogenic Polydipsia (as in a true behavior disorder with a compulsive element)
20. Primary Non-Medical Polydipsia (aka "I drink a lot because I like it or I engage in activities that promote it, but that doesn't mean I'm sick")
21. Primary Nephrogenic Diabetes Insipidus (Congenital Nephrogenic Diabetes Insipidus, other diseases that cause primary PU other than Congenital Diabetes Insipidus would be considered Acquired Nephrogenic Diabetes Insipidus)
22. Atypical Cushing's and SARDS
23. Central Diabetes Insipidus

**INTERPRETED BY**

Kathleen Sennello DVM,  
MS, Diplomate ACVIM  
(Small Animal Internal  
Medicine)

**IMAGING PERFORMED BY**

Diane McFadden

**HOSPITAL NAME**

Newton Vet Hospital

**REFERRING VET**

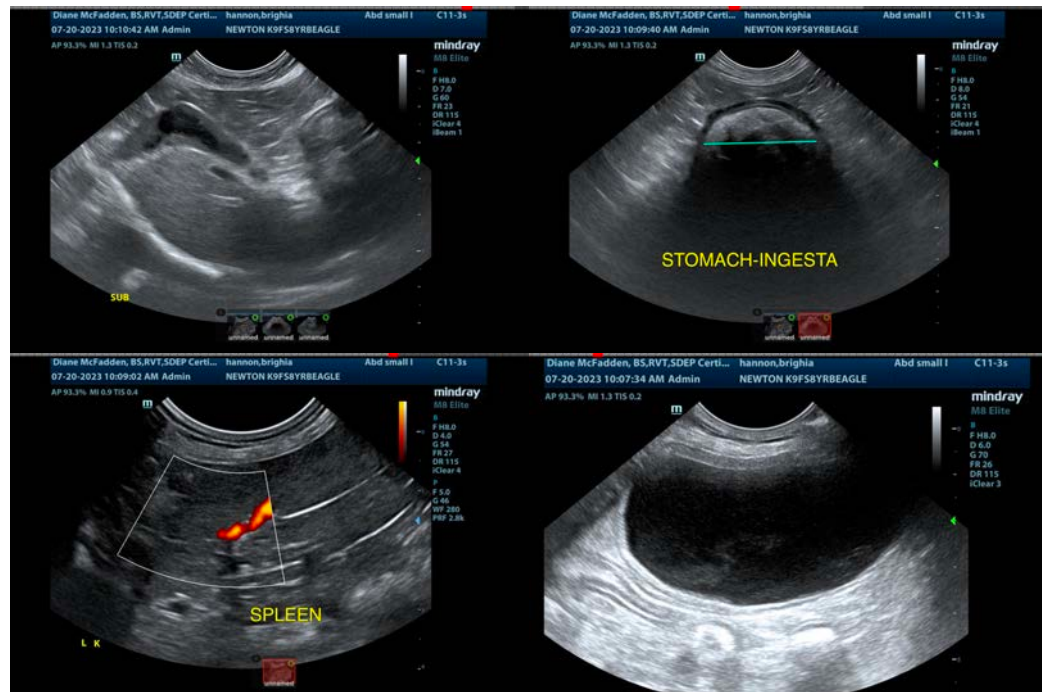
Dr. Wyman-Greenwald

**INVOICE**

44183

**DATE**

7/20/23





**PATIENT**

Brighia Hannon

**SPECIES**

Canine

**BREED**

Beagle

**SEX**

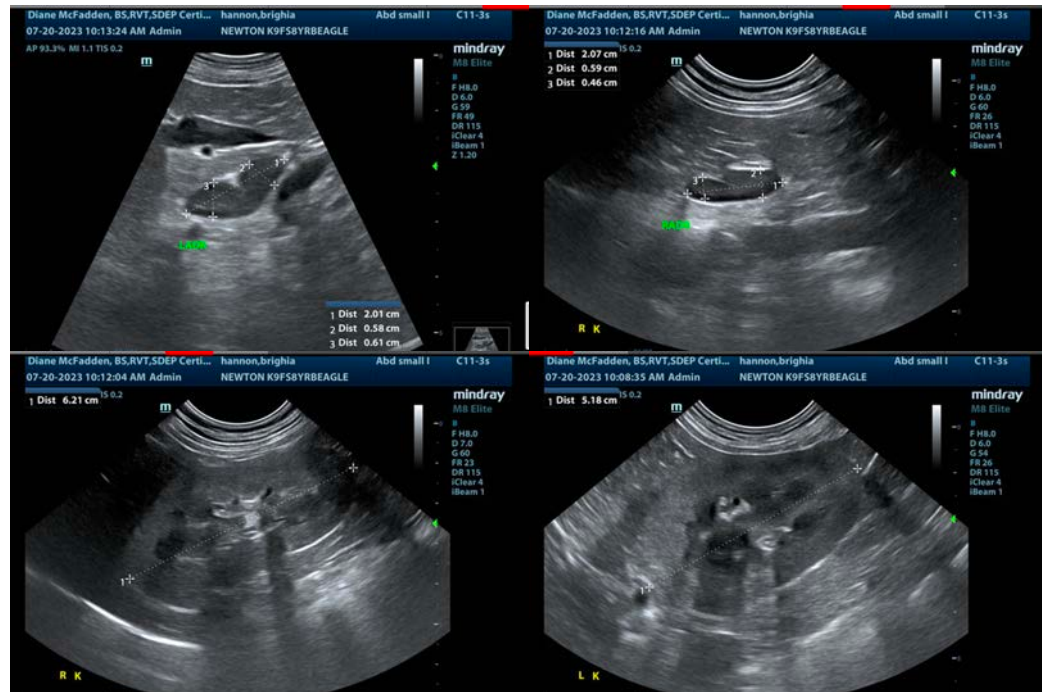
Spayed Female

**AGE**

8 Years

**WEIGHT**

27.3 Pounds



**INTERPRETED BY**

Kathleen Sennello DVM,  
MS, Diplomate ACVIM  
(Small Animal Internal  
Medicine)

The information and recommendations provided are based on the images presented by the referring veterinarian/sonographer. No evaluation can be communicated regarding pathology that was not visible in the image/video clips provided.

Thank you for this referral. If the clinical or image interpretation does not parallel your findings or if I can be of any further assistance please contact me.

**IMAGING PERFORMED BY**

Diane McFadden

Kathleen Sennello DVM,MS, Diplomate ACVIM (Small animal Internal Medicine)

info@sonopath.com

**HOSPITAL NAME**

Newton Vet Hospital

**REFERRING VET**

Dr. Wyman-Greenwald

**INVOICE**

44183

**DATE**

7/20/23