

**DATE PRESENTING CLINICAL SIGNS**

7/19/23

Vomiting and anorexia starting Friday. Since Sunday p not holding food down. Radiographs of abd inconclusive; gas pattern in cecum and suspect irregular splenic margins. Elevated liver values, mild increase bilirubin, SDMA.

PATIENT

Fiona Hudson

Current Medications: Today starting protonix 1 mg/kg IV sid and cerenia low dose 0.5 mg/kg SID IV
Lab Results: Elevated liver values, mild increase bilirubin, SDMA. PCV 54%, TS 6.2 g/dL

SPECIES

Canine

Date of Previous IntraPet Ultrasound: No previous.

Sedation: Not required to complete full diagnostic ultrasound.

Stat Report: STAT requested.

Imaging Performed By: Rachel Brillhart, RDMS.

BREED

Boxer

ULTRASONOGRAPHIC EXAMINATION OF THE ABDOMEN**SEX**

Spayed Female

Urinary System

The urinary bladder is moderately distended with anechoic urine. The Bladder wall, trigone, ureteral papillae and visible urethra (to a depth of 2cm) appear normal with no evidence of wall thickening, mucosal irregularities, masses or cystic calculi.

AGE

11/25/18

The left kidney has a normal shape and size (7.14 cm). Overall echogenicity is normal with adequate corticomedullary distinction and a typical 1:3 cortex:medulla ratio. There is no evidence of focal perinephric inflammation or effusion. There is no evidence of pyelectasia, nephroliths, infarcts or hydroureter. Renal vasculature is normal.

WEIGHT

94 Pounds

The right kidney has a normal shape and size (5.62 cm). Overall echogenicity is normal with adequate corticomedullary distinction and a typical 1:3 cortex:medulla ratio. There is no evidence of focal perinephric inflammation or effusion. There is no evidence of pyelectasia, nephroliths, infarcts or hydroureter. Renal vasculature is normal.

INTERPRETED BY

Kathleen Sennello DVM,
MS, Diplomate ACVIM
(Small Animal Internal
Medicine)

Adrenal Glands

The left adrenal gland is normal in size measuring 0.74 cm at the caudal pole. It is observed in its normal position cranial to the left renal artery. It is normal in appearance (uniformly hypoechoic) and shape with no evidence of a mass effect.

HOSPITAL NAME

Perry Hall AH

The right adrenal gland is normal in size measuring 0.68 cm at the caudal pole. It is observed in its normal position between the cranial aspect of the right kidney and the caudal vena cava. It is normal in appearance (uniformly hypoechoic) and shape with no evidence of a mass effect.

REFERRING VET

Dr. Hatzigiannakis

Spleen

The spleen is large and irregular. The spleen echotexture is heterogenous and mottled, the splenic capsule is smooth with no irregularities. The blood flow through the hilus and splenic parenchyma appears normal. The margins of the spleen are scalloped and irregular, and there are numerous ill-defined hypoechoic "moth eaten" appearing lesions. One such nodule is visualized at 1.23 cm.

INVOICE

44108

Liver

The liver is subjectively normal in size, and hypoechoic with smooth peripheral margins. The parenchyma is heterogenous in echotexture with subtle, indistinct focal mottling. The visible portions of the vasculature and biliary tract appear normal. No focal nodules or cystic lesions are observed.

The gallbladder lumen is moderately distended. The wall of the gall bladder appears thickened with a smooth mucosal surface, measuring 0.53 cm. Luminal contents are mild and primarily anechoic. The cystic and common bile ducts are normal/not visible.

Gastrointestinal

The stomach contains minimal luminal contents. It measures at a normal thickness of <0.7cm with some variability due to the presence of rugal folds. The distinction of the gastric wall layers is adequate and there is no impression of reduced peristaltic activity. No masses or focal lesions were observed.

The visualized areas of duodenum, jejunum and ileum have a relatively uniform diameter with minimal fluid distension. Wall thickness is normal. Bowel loops follow a curvilinear path with distinct wall layering maintaining the typical 1:3 muscularis:mucosa layer ratio. Duodenum wall measures 0.48 cm. Jejunum wall measures 0.33 cm. Visualized peristalsis appears appropriate. There were no focal lesions consistent with obstruction or a mass effect observed.

The ileocecal junction was visualized and exhibited normal intact wall layering and is subjectively of normal thickness. Sections of colon are visualized with formed fecal material and gas shadowing distally. There is no observed focal or generalized colon wall thickening or loss of layering.

Pancreas

The area of the pancreas is normal and isoechoic to surrounding mesentery. There is no evidence of nodules or cystic lesions. There is no evidence of regional mesenteric inflammation or fluid.

Free Abdomen

Evaluation of the peritoneal cavity did not reveal any evidence of effusion. There is a significant diffuse mesenteric lymphadenopathy with large, hypoechoic, irregular lymph nodes. There is a lymph node measuring 2.38 cm x 8.09 cm at the root of the mesentery. A portal lymph node is visualized measuring 1.42 cm x 2.51 cm, and the sublumbar lymph nodes measure 0.74 cm and 0.76 cm. The omentum is hyperechoic around the enlarged lymph nodes.

Other

The right auricle and pericardium were visualized and were unremarkable. No obvious pathology is visualized. If cardiac function evaluation is desired a full echocardiogram is warranted. There is no evidence of pleural effusion or a mediastinal mass.

ULTRASONOGRAPHIC FINDINGS

- Large, mottled, moth eaten, irregular spleen with ill-defined hypoechoic nodules – The diffuse splenic changes are non-specific and could be consistent with lymphoid hyperplasia, extramedullary hematopoiesis, infiltrative neoplasia, inflammation, other. Cytology or histopathology would be necessary to get a definitive diagnosis.
- Hypoechoic, heterogeneous liver – The diffuse hepatic changes are non-specific and could be consistent with vacuolar hepatopathy, nodular hyperplasia, inflammatory/immune-mediated disease, fibrosis, extramedullary hematopoiesis, toxic hepatopathy (e.g., copper), infiltrative neoplasia (less likely) or other hepatopathy.
- Thickened gallbladder wall with a hyperechoic luminal surface – Findings are most consistent with edema, inflammation, or infiltration.

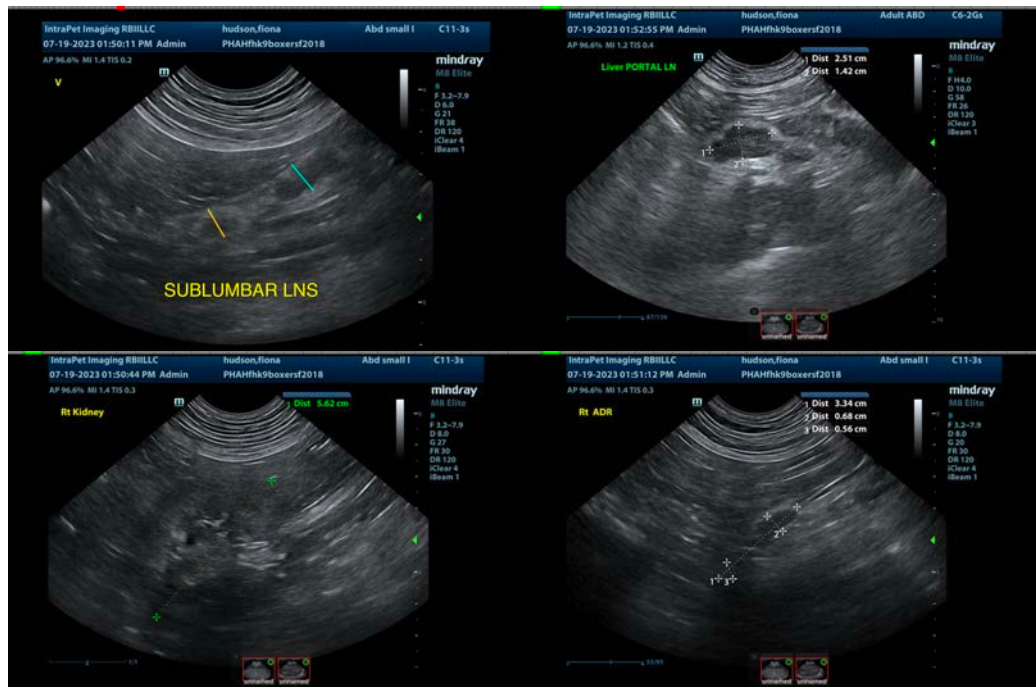
- Enlarged, hypoechoic, irregular lymph nodes at the mesenteric root, portal region, and sublumber region – The moderate mesenteric lymphadenopathy could be concerning for a neoplastic process, although you can see significant lymphadenopathy in some cases of autoimmune/inflammatory disease, infectious disease (tick born disease-such as bartonella, fungal infections, FIP (cats)) etc. A fine needle aspirate with cytology is recommended for further evaluation.

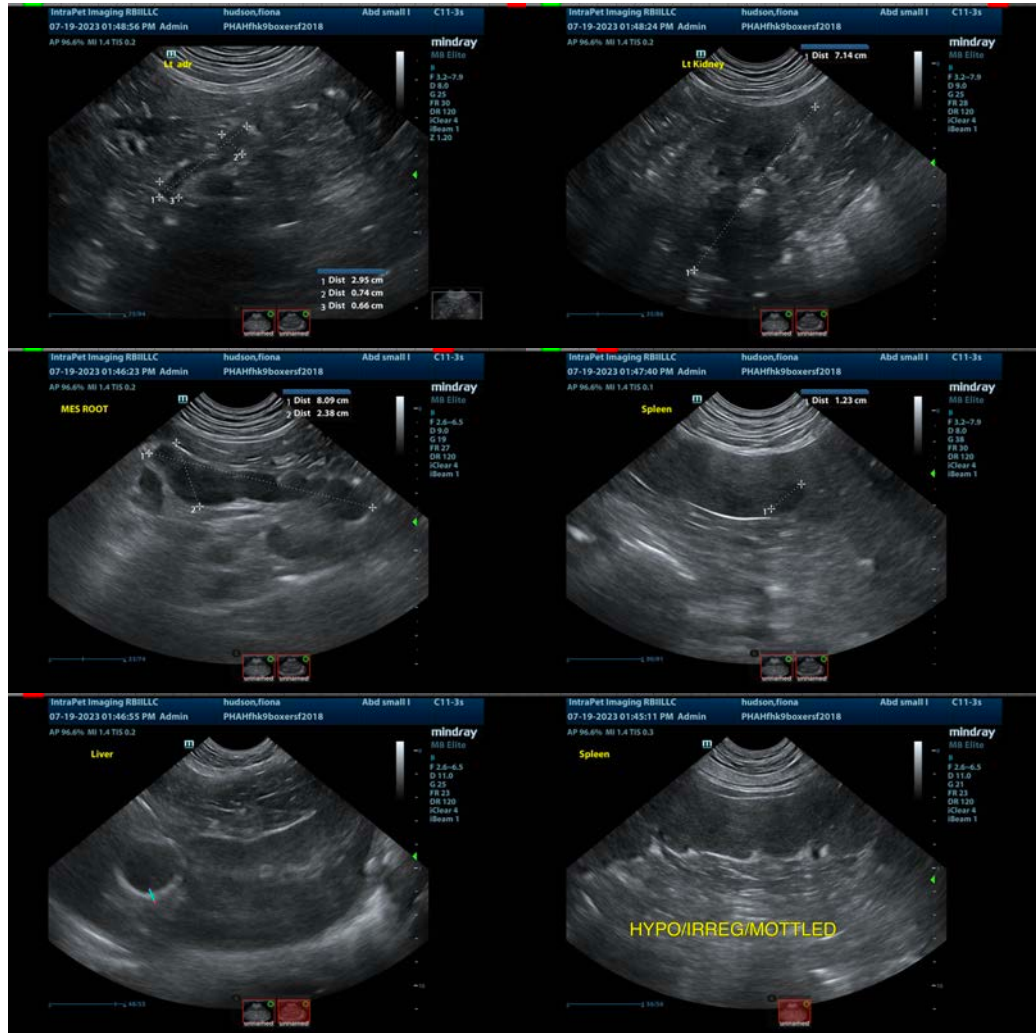
INTERPRETATION OF THE FINDINGS & FURTHER RECOMMENDATIONS

No focal gastrointestinal or hepatic lesions were observed to explain the inappetence and/or the elevation in liver enzymes reported. The liver does appear diffusely hypoechoic and heterogeneous. Additionally, the spleen is large, scalloped, irregular, and significantly mottled with some ill-defined hypoechoic nodules. These findings could be concerning for infiltrative disease to both the liver and the spleen (round cell neoplasia, but other differentials are possible). Consider a fine needle aspirate.

Additionally, there is a diffuse significant lymphadenopathy present with large lymph nodes visualized at the root of the mesentery, in the portal region, and the sublumber region. Recommend a fine needle aspirate of an abdominal lymph node.

Recommend three view thoracic radiographs to evaluate for possible concurrent thoracic disease/involvement.





The information and recommendations provided are based on the images presented by the referring veterinarian/sonographer. No evaluation can be communicated regarding pathology that was not visible in the image/video clips provided.

Thank you for this referral. If the clinical or image interpretation does not parallel your findings or if I can be of any further assistance please contact me.

Kathleen Sennello DVM,MS, Diplomate ACVIM (Small animal Internal Medicine)
 info@sonopath.com