



PATIENT PRESENTING CLINICAL SIGNS

Brooklyn Miller Stranguria, urinary accidents. Concern for neoplasia. No current meds.

SPECIES ULTRASONOGRAPHIC EXAMINATION OF THE ABDOMEN

Canine **Urinary System**

BREED The urinary bladder is significantly distended with anechoic urine. The Bladder wall largely appears of normal thickness and smooth echogenicity up until the cystourethral junction, where there is focal irregularity and wall thickening up to 1.0 cm. This irregular tissue extends into the urethra, which dilated with a large amount of irregular intraluminal tissue with some mineralization. The urethra measures at 1.54 cm in diameter in this region, and the urethral irregularity extends for over 5.96 cm. Findings are most consistent with a urethral mass lesions.

Lab X

SEX

Spayed Female

AGE

12 Years

WEIGHT

73 Pounds

INTERPRETED BY

Kathleen Sennello DVM,
MS, Diplomate ACVIM
(Small Animal Internal
Medicine)

IMAGING PERFORMED BY

Shari Reffi, CVT

HOSPITAL NAME

Millburn Vet Hospital

REFERRING VET

Dr. Rotsides

INVOICE

44159

DATE

7/19/23

The left kidney has a normal shape and size (5.38 cm) with a cortical cyst in the mid caudal kidney measures 1.00 cm in diameter. Overall echogenicity is normal with adequate corticomedullary distinction and a typical 1:3 cortex:medulla ratio. There is no evidence of focal perinephric inflammation or effusion. There is no evidence of pyelectasia, nephroliths, infarcts or hydroureter. Renal vasculature is normal.

The right kidney has a normal shape and size (5.83 cm). Overall echogenicity is normal with adequate corticomedullary distinction and a typical 1:3 cortex:medulla ratio. There is no evidence of focal perinephric inflammation or effusion. There is no evidence of pyelectasia, nephroliths, infarcts or hydroureter. Renal vasculature is normal.

Adrenal Glands

The left adrenal gland is normal in size measuring 0.63 cm at the caudal pole. It is observed in its normal position cranial to the left renal artery. It is normal in appearance (uniformly hypoechoic) and shape with no evidence of a mass effect.

The right adrenal gland is normal in size measuring 0.71 cm at the caudal pole. It is observed in its normal position between the cranial aspect of the right kidney and the caudal vena cava. It is normal in appearance (uniformly hypoechoic) and shape with no evidence of a mass effect.

Spleen

The spleen is subjectively normal in size, echotexture is homogenous, and the splenic capsule is smooth with no irregularities. The blood flow through the hilus and splenic parenchyma appears normal. No focal parenchymal abnormalities are visualized.

Liver

The liver is subjectively normal in size, and echogenicity with smooth peripheral margins. The parenchyma is homogenous echotexture. The visible portions of the vasculature and biliary tract appear normal. No focal nodules or cystic lesions are observed.

The gallbladder lumen is moderately distended. The wall of the gall bladder is not thickened and has a smooth mucosal surface. Luminal contents are mild and primarily anechoic. The cystic and common bile ducts are normal/not visible.



PATIENT *Gastrointestinal*

Brooklyn Miller

The stomach contains minimal luminal contents. It measures at a normal thickness of <0.7cm with some variability due to the presence of rugal folds. The distinction of the gastric wall layers is adequate and there is no impression of reduced peristaltic activity. No masses or focal lesions were observed.

SPECIES

Canine

The visualized areas of duodenum, jejunum and ileum have a relatively uniform diameter with minimal fluid distension. Wall thickness is normal. Bowel loops follow a curvilinear path with distinct wall layering maintaining the typical 1:3 muscularis:mucosa layer ratio. Duodenum wall measures 0.40 cm. Jejunum wall measures 0.37 cm. Visualized peristalsis appears appropriate. There were no focal lesions consistent with obstruction or a mass effect observed.

BREED

Lab X

SEX

Spayed Female

The ileocecal junction was visualized and exhibited normal intact wall layering and is subjectively of normal thickness. Sections of colon are visualized with formed fecal material and gas shadowing distally. There is no observed focal or generalized colon wall thickening or loss of layering.

AGE

12 Years

Pancreas

The area of the pancreas is normal and isoechoic to surrounding mesentery. There is no evidence of nodules or cystic lesions. There is no evidence of regional mesenteric inflammation or fluid.

WEIGHT

73 Pounds

Free Abdomen

Evaluation of the peritoneal cavity did not reveal any evidence of effusion, or subjective lymphadenomegaly. The Medial iliac nodes appear normal and there was no evidence of a caudal aortic thrombus at the bifurcation. The omentum is of normal uniform echogenicity.

INTERPRETED BY

Kathleen Sennello DVM,
MS, Diplomate ACVIM
(Small Animal Internal
Medicine)

PRIMARY FINDINGS

- Thickened, irregular tissue visualized at the cystourethral junction extending into the urethra with associated mineralization – Findings are concerning for a urethral mass. Primary differential would be transitional cell carcinoma, although other differentials are possible.

IMAGING PERFORMED BY

Shari Reffi, CVT

SECONDARY FINDINGS

- Cystic lesion in the caudal pole of the left kidney – Findings are most consistent with benign renal cyst.

HOSPITAL NAME

Millburn Vet Hospital

INTERPRETATION OF THE FINDINGS & FURTHER RECOMMENDATIONS

There is abnormal tissue visualized within the urinary bladder, starting at the cystourethral junction and extending into the urethra for over 6.0 cm. This tissue is irregular and mineralized with a very high concern for a transitional cell carcinoma, although other differentials such as granulomatous urethritis, etc. are possible. Options moving forward would include cytology on a free catch urine sample if there is adequate cellularity for cytology, a traumatic catheterization, and/or you could consider a urine BRAF test. If this test is positive, it would greatly increase the likelihood that this is a transitional cell carcinoma. If this test is negative, it is a non-diagnostic test and additional diagnostics would be required.

REFERRING VET

Dr. Rotsides

INVOICE

44159

DATE

7/19/23

If a cytologic diagnosis can be obtained, consider consultation with a veterinary oncologist regarding treatment options and prognosis. This lesion is in a non-resectable location and there is concern for a urethral obstruction. Treatment with Piroxicam/Misoprostol could be initiated (provided the patient has normal renal function, etc.) while awaiting test results.



PATIENT

Recommend three view thoracic radiographs to evaluate for possible concurrent thoracic disease/involvement.

Brooklyn Miller

SPECIES

Canine

BREED

Lab X

SEX

Spayed Female

AGE

12 Years

WEIGHT

73 Pounds

INTERPRETED BY

Kathleen Sennello DVM,
MS, Diplomate ACVIM
(Small Animal Internal
Medicine)

**IMAGING
PERFORMED BY**

Shari Reffi, CVT

HOSPITAL NAME

Millburn Vet Hospital

REFERRING VET

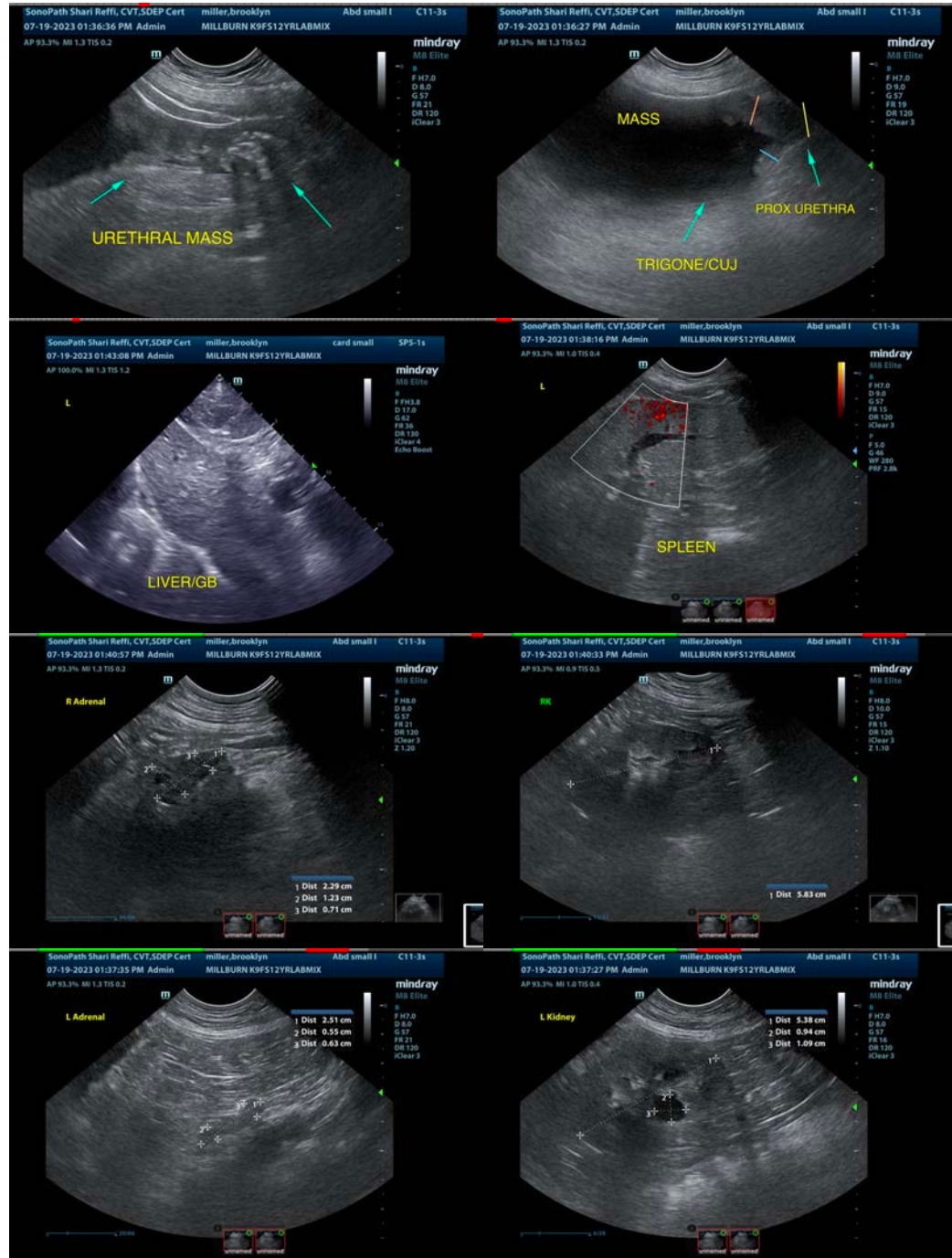
Dr. Rotsides

INVOICE

44159

DATE

7/19/23





PATIENT

Brooklyn Miller

SPECIES

Canine

BREED

Lab X

SEX

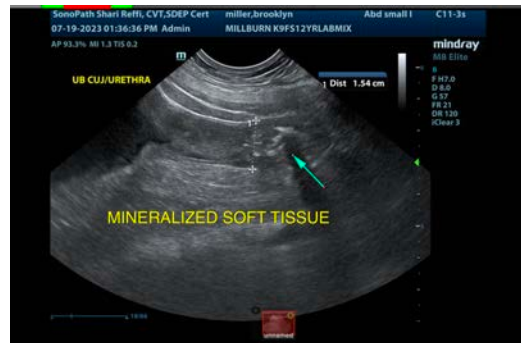Spayed Female

AGE

12 Years

WEIGHT

73 Pounds



The information and recommendations provided are based on the images presented by the referring veterinarian/sonographer. No evaluation can be communicated regarding pathology that was not visible in the image/video clips provided.

Thank you for this referral. If the clinical or image interpretation does not parallel your findings or if I can be of any further assistance please contact me.

Kathleen Sennello DVM,MS, Diplomate ACVIM (Small animal Internal Medicine)

info@sonopath.com

INTERPRETED BY

Kathleen Sennello DVM,
MS, Diplomate ACVIM
(Small Animal Internal
Medicine)

IMAGING PERFORMED BY

Shari Reffi, CVT

HOSPITAL NAME

Millburn Vet Hospital

REFERRING VET

Dr. Rotsides

INVOICE

44159

DATE

7/19/23