

**DATE PRESENTING CLINICAL SIGNS**

7/19/22 Presented for weight loss. Has muscle loss along the spine. CBC, chem unremarkable. T4 2.8. Can only slightly feel the thyroid gland. Chest and abdominal rads done- NSF seen.

**PATIENT**

Weemo Leftwich

Current Medications: None.

Lab Results: See attached.

Radiographs: See attached.

Date of Previous IntraPet Ultrasound: No previous.

Sedation: Not required to complete full diagnostic ultrasound.

Stat Report: Not requested.

**SPECIES**

Feline

**BREED**

DSH

**SEX**

Neutered Male

**AGE**

5/31/08

**WEIGHT**

8.13 Pounds

**INTERPRETED BY**

Kathleen Sennello DVM,  
MS, Diplomate ACVIM  
(Small Animal Internal  
Medicine)

**IMAGING PERFORMED BY**

Rachel Brilhart RDMS

**HOSPITAL NAME**

All Creatures  
Veterinary Services

**REFERRING VET**

Dr. Meadows

**INVOICE**

39659

**ULTRASONOGRAPHIC EXAMINATION OF THE ABDOMEN****Urinary System**

The urinary bladder is moderately distended with anechoic urine. The Bladder wall, trigone, ureteral papillae and visible urethra (to a depth of 2cm) appear normal with no evidence of wall thickening, mucosal irregularities, masses or cystic calculi.

The left kidney has a normal shape and size (3.47 cm) with a non-obstructive nephrolith measuring 0.38 cm. Overall echogenicity is slightly hyperechoic with poor corticomedullary distinction and a typical 1:3 cortex:medulla ratio. There is no evidence of perinephric inflammation or effusion. There is no evidence of pyelectasia, infarcts or hydroureter. Renal vasculature is normal.

The right kidney has a normal shape and size (3.79 cm). Overall echogenicity is slightly hyperechoic with poor corticomedullary distinction and a typical 1:3 cortex:medulla ratio. There is no evidence of perinephric inflammation or effusion. There is no evidence of pyelectasia, nephroliths, infarcts or hydroureter. Renal vasculature is normal.

**Adrenal Glands**

The left adrenal gland is normal in size measuring 0.40 cm at the caudal pole. It is observed in its normal position cranial to the left renal artery. It is somewhat irregular in appearance in that it is mineralized, as can be seen in some older cats.

The right adrenal gland is normal in size measuring 0.46 cm at the caudal pole. It is observed in its normal position between the cranial aspect of the right kidney and the caudal vena cava. It is somewhat irregular in appearance in that it is mineralized, as can be seen in some older cats.

**Spleen**

The spleen is subjectively normal in size, echotexture is homogenous, and the splenic capsule is smooth with no irregularities. The blood flow through the hilus and splenic parenchyma appears normal. No focal parenchymal abnormalities are visualized.

**Liver**

The liver is subjectively normal in size, and echogenicity with smooth peripheral margins. The parenchyma is homogenous echotexture. The visible portions of the vasculature and biliary tract appear normal. No focal nodules or cystic lesions are observed.

The gallbladder lumen is moderately distended. The wall of the gall bladder is not thickened and has a smooth mucosal surface. Luminal contents are primarily anechoic. The cystic and common bile ducts are normal/not visible.

### ***Gastrointestinal***

The stomach contains minimal luminal contents. It measures at a normal thickness of <0.36cm with some variability due to the presence of rugal folds. The distinction of the gastric wall layers is adequate and there is no impression of reduced peristaltic activity. No masses or focal lesions were observed.

The visualized areas of duodenum, jejunum and ileum have a uniform diameter with minimal fluid distension. Wall thickness is normal to slightly increased. Bowel loops follow a typical curvilinear path with distinct wall layering, but some areas display a prominent muscularis layer which does not display the typical 1:3 muscularis:mucosa layer ratio. Jejunum wall measured 0.28 cm. Visualized peristalsis appears appropriate. There were no focal lesions consistent with obstruction or a mass effect observed.

The ileocecal junction was visualized and exhibited normal intact wall layering and is subjectively of normal thickness. Sections of colon are visualized with formed fecal material and gas shadowing distally. There is no observed focal or generalized colon wall thickening or loss of layering.

### ***Pancreas***

The pancreas is prominent and hypoechoic as compared to the surrounding isoechoic mesentery. There is no evidence of nodules or cystic lesions. There is no evidence of regional mesenteric inflammation or fluid.

### ***Free Abdomen***

There is a small amount of free fluid. A diffuse mild mesenteric lymphadenopathy is present with mesenteric lymph nodes measuring 0.67, 0.38, 0.41 cm. The omentum is of normal echogenicity.

## **PRIMARY FINDINGS**

- Hypoechoic, prominent pancreas – The pancreatic changes are most consistent with mild pancreatitis or a recent episode of pancreatic inflammation.
- Prominent muscularis layer to the small intestine – The small intestinal wall changes are most consistent with an inflammatory process (i.e., inflammatory bowel disease) with a low possibility of emerging lymphoma.
- Mild diffuse mesenteric lymphadenopathy – The prominent abdominal lymph nodes are most consistent with reactive lymphadenitis or lymphoid hyperplasia. Neoplastic infiltration is considered less likely.
- Small volume free abdominal fluid.

## **SECONDARY FINDINGS**

- Decreased corticomedullary distinction in both kidneys with a left-sided non-obstructive nephroliths – The bilateral renal findings are consistent with age-related change.
- Bilateral adrenal mineralization – This can be a normal finding in some older cats.

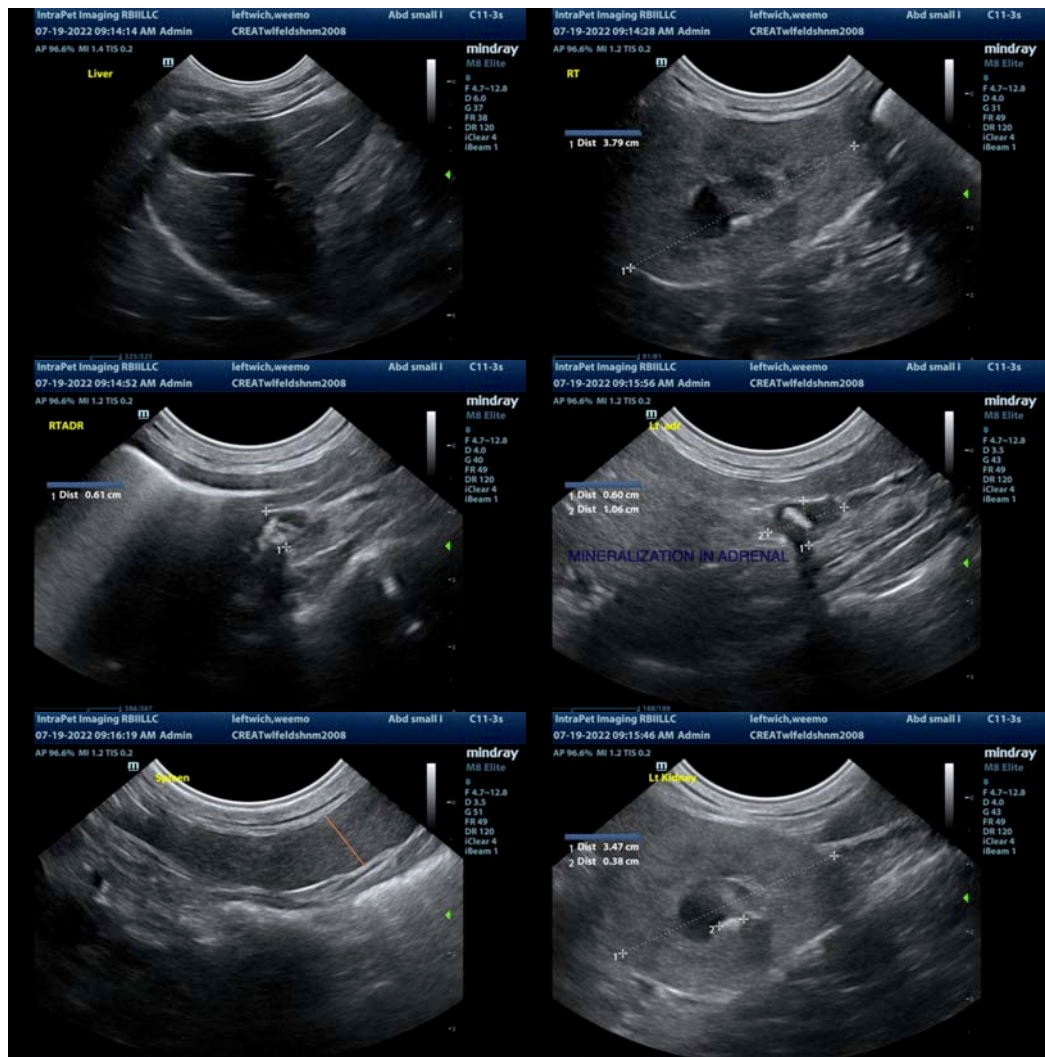
## **INTERPRETATION OF THE FINDINGS & FURTHER RECOMMENDATIONS**

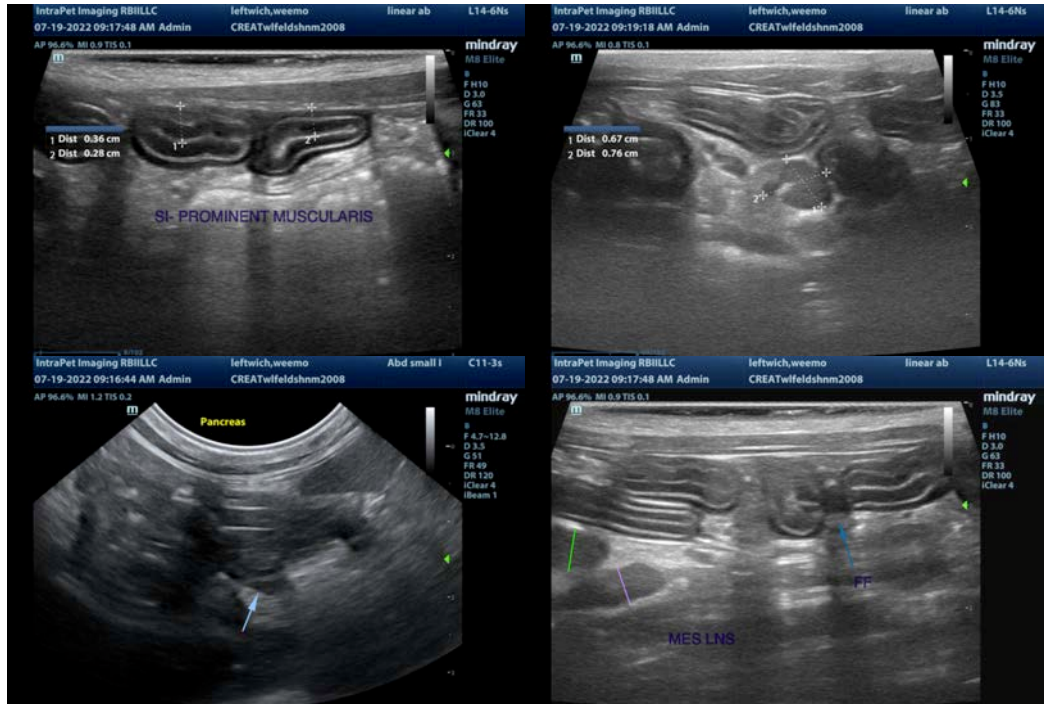
There is the general appearance of “ropey” small intestine with a prominent muscularis layer and a generalized lymphadenopathy. Additionally, there is a scant amount of free fluid. These findings are suggestive of likely primary gastrointestinal disease (inflammatory, infectious, neoplastic).

Additionally, the pancreas is prominent and hypoechoic. This could be consistent with previous episodes of pancreatitis and remodeling, or current mild pancreatitis.

- Consider a novel protein/hydrolyzed protein prescription diet.
- Recommend a GI panel to Texas A&M for a qualitative fPLI, TLI, cobalamin and folate to further evaluate the pancreas and small intestine.
- Recommend chronic probiotic therapy.
- Consider three view thoracic radiographs to rule out concurrent thoracic disease/involvement.
- If weight loss persists, recommend obtaining GI biopsies.

A fine needle aspirate of a mesenteric lymph node could be considered. These lymph nodes are on the small side for an aspirate, but this additional information could be helpful.





The information and recommendations provided are based on the images presented by the referring veterinarian/sonographer. No evaluation can be communicated regarding pathology that was not visible in the image/video clips provided.

Thank you for this referral. If the clinical or image interpretation does not parallel your findings or if I can be of any further assistance please contact me.

Kathleen Sennello DVM,MS, Diplomate ACVIM (Small animal Internal Medicine)  
 kathleen.sennello@sonopath.com