

**DATE PRESENTING CLINICAL SIGNS**

7/19/22

Presented for distended abdomen and incontinence on 6/24/22. Has increased hunger and drinking more. No C/S/V/D. Energy wnl. Has grade 2-3/6 systolic murmur and distended abdomen. FAST scan done 6/24/22 and no apparent free fluid seen. Liver appeared enlarged. Recommended BW. BW showed markedly elevated liver values; slight WBC elevation, and USG of 1.001 with a UPC of 1.1. Pet put on Clavamox, metronidazole, and Denamarin with recommendation for full abdominal ultrasound.

**PATIENT**

Peanut Willen

**SPECIES**

Canine

Current Medications: Clavamox 62.5mg tablets: 1.5T BID, Metronidazole 250mg: 1/4T BID, Denamarin Advanced small to medium: 1/4T SID.

Lab Results: See attached.

Date of Previous IntraPet Ultrasound: No previous.

**BREED**

Sedation: Not required to complete full diagnostic ultrasound.

Stat Report: Not requested.

Chihuahua X

**ULTRASONOGRAPHIC EXAMINATION OF THE ABDOMEN****SEX**

Intact Female

**Urinary System**

The urinary bladder is moderately distended with anechoic urine. The Bladder wall, trigone, ureteral papillae and visible urethra (to a depth of 2cm) appear normal with no evidence of wall thickening, mucosal irregularities, masses or cystic calculi.

**AGE**

11/21/09

The left kidney has a normal shape and size (4.41 cm). Overall echogenicity is normal with adequate corticomedullary distinction and a typical 1:3 cortex:medulla ratio. There is no evidence of perinephric inflammation or effusion. There is no evidence of pyelectasia, nephroliths, infarcts or hydroureter. Renal vasculature is normal.

**WEIGHT**

13.56 Pounds

The right kidney has a normal shape and size (5.16 cm). Overall echogenicity is normal with adequate corticomedullary distinction and a typical 1:3 cortex:medulla ratio. There is no evidence of perinephric inflammation or effusion. There is no evidence of pyelectasia, nephroliths, infarcts or hydroureter. Renal vasculature is normal.

**INTERPRETED BY**

Kathleen Sennello DVM,  
MS, Diplomate ACVIM  
(Small Animal Internal  
Medicine)

**IMAGING PERFORMED BY**

Rachel Brillhart RDMS

**Adrenal Glands**

The left adrenal gland is large in size measuring 0.65 cm at the cranial pole, 0.91 cm at the caudal pole, and 2.34 cm in length. It is observed in its normal position cranial to the left renal artery. It is somewhat abnormal in appearance in that it is large, hypoechoic, and there appears to be some soft tissue in the region of the phrenicoabdominal vein, possibly indicative of early invasion.

**HOSPITAL NAME**

All Creatures  
Veterinary Service

The right adrenal gland is large in size measuring 1.16 cm at the cranial pole, 0.75 cm at the caudal pole, and 2.18 cm in length. It is observed in its normal position between the cranial aspect of the right kidney and the caudal vena cava. It is normal in appearance (uniformly hypoechoic) and shape with no evidence of a mass effect.

**REFERRING VET**

Dr. Meadows

**Spleen**

The spleen is subjectively normal in size, echotexture is homogenous, and the splenic capsule is smooth with no irregularities. The blood flow through the hilus and splenic parenchyma appears normal. No focal parenchymal abnormalities are visualized.

**INVOICE**

39653

**Liver**

The liver is large in size, and normal in echogenicity with smooth peripheral margins. The parenchyma is heterogenous in echotexture with subtle, indistinct focal mottling. The visible portions of the vasculature and biliary tract appear normal. No focal nodules or cystic lesions are observed.

The gall bladder lumen is significantly distended. Some areas of the wall appear mildly thickened with adherent debris. There is a large amount of primarily non-organized echogenic debris. There is no evidence of bile duct dilation. These changes can be consistent with an early gall bladder mucocele.

### ***Gastrointestinal***

The stomach contains minimal luminal contents. It measures at a normal thickness of <0.7cm with some variability due to the presence of rugal folds. The distinction of the gastric wall layers is adequate and there is no impression of reduced peristaltic activity. No masses or focal lesions were observed.

The visualized areas of duodenum, jejunum and ileum have a relatively uniform diameter with minimal fluid distension. Wall thickness is normal. Bowel loops follow a curvilinear path with distinct wall layering maintaining the typical 1:3 muscularis:mucosa layer ratio. The duodenum measured as normal (between 0.3-0.5cm in wall thickness) and the jejunum measured as normal (between 0.2-0.47cm.) Visualized peristalsis appears appropriate. There were no focal lesions consistent with obstruction or a mass effect observed.

The ileocecal junction was visualized and exhibited normal intact wall layering and is subjectively of normal thickness. Sections of colon are visualized with formed fecal material and gas shadowing distally. There is no observed focal or generalized colon wall thickening or loss of layering.

### ***Pancreas***

The pancreas is prominent and mottled compared to the surrounding isoechoic mesentery. There is no evidence of nodules or cystic lesions. There is no evidence of regional mesenteric inflammation or fluid.

### ***Free Abdomen***

Evaluation of the peritoneal cavity did not reveal any evidence of effusion, or subjective lymphadenomegaly. The Medial iliac nodes appear normal and there was no evidence of a caudal aortic thrombus at the bifurcation. The omentum is of normal uniform echogenicity.

### ***Other***

The uterus and ovaries were not visualized on today's exam (labeled as intact female).

## **ULTRASONOGRAPHIC FINDINGS**

- Bilateral adrenomegaly with possible early left-sided vascular invasion – The bilateral adrenomegaly could be consistent with bilateral hyperplasia (e.g., secondary to pituitary-dependent hyperadrenocorticism), bilateral infiltrative neoplasia, inflammatory adrenal disease, other. Correlation with clinical findings is recommended. The possible vascular invasion would not be typical for hyperplasia. Close continued monitoring is recommended.
- Prominent, mottled pancreas – The pancreatic changes are most consistent with age-related parenchymal remodeling, potentially secondary to a prior inflammatory episode, early fibrosis or chronic pancreatitis.
- Large, heterogeneous liver – The diffuse hepatic changes are non-specific and could be consistent with vacuolar hepatopathy, nodular hyperplasia, inflammatory/immune-mediated disease, fibrosis, extramedullary hematopoiesis, toxic hepatopathy (e.g., copper), infiltrative neoplasia (less likely) or other hepatopathy.
- Large amount of gallbladder debris – The significance of the aggregated gallbladder sludge is unclear. This could represent an early mucocele, cholestasis, or may be secondary to fasting.

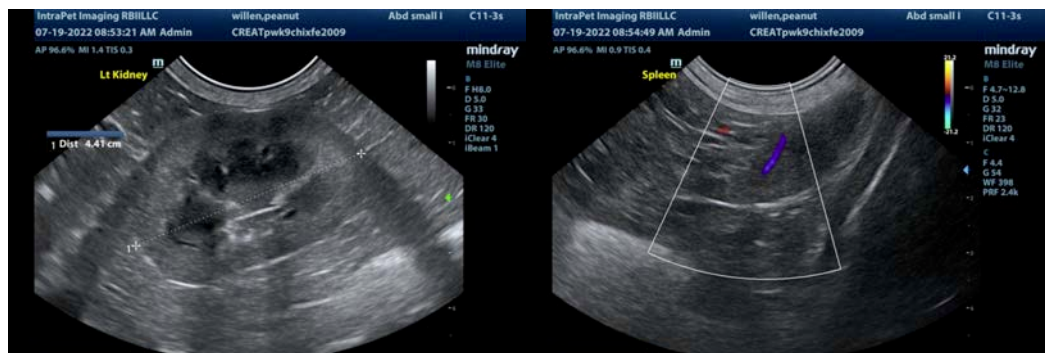
## INTERPRETATION OF THE FINDINGS & FURTHER RECOMMENDATIONS

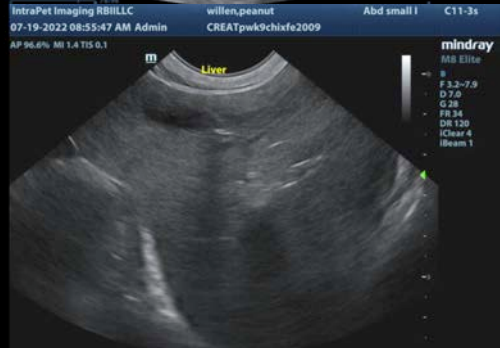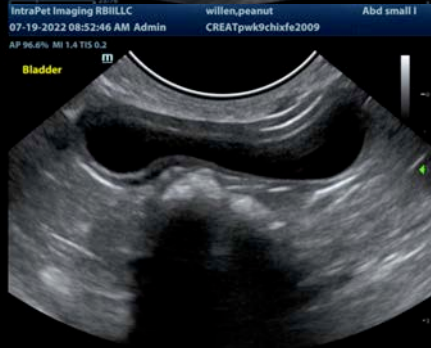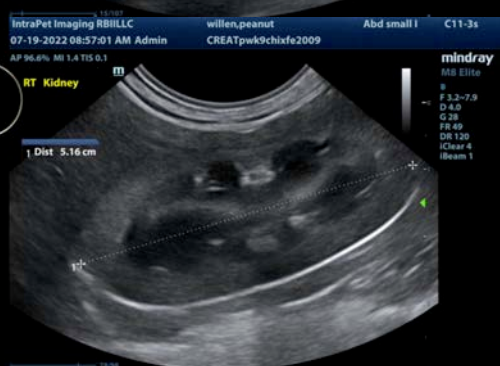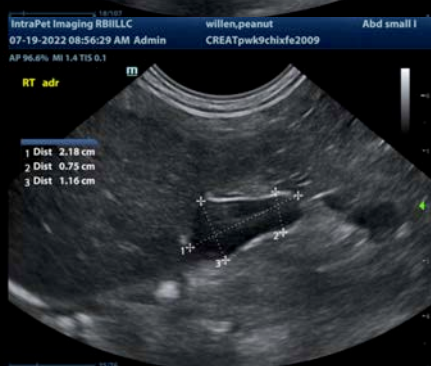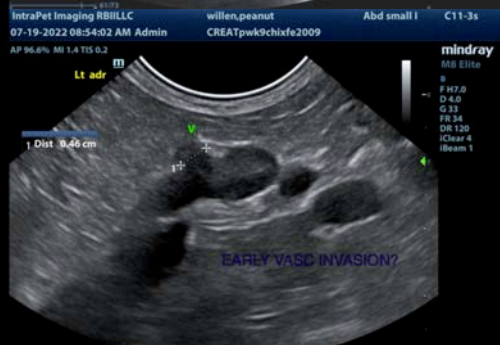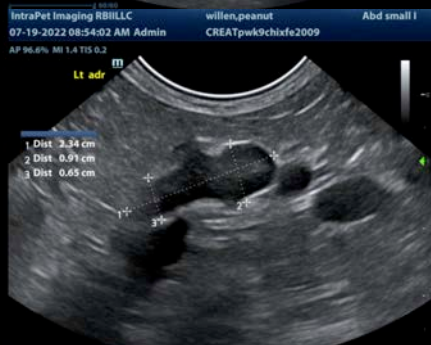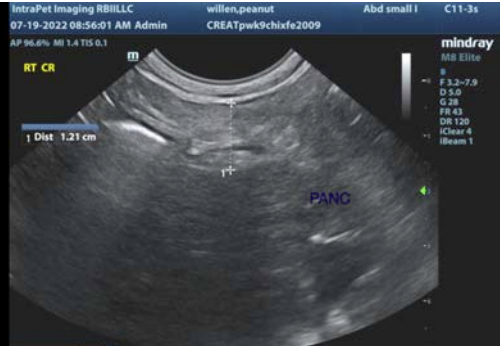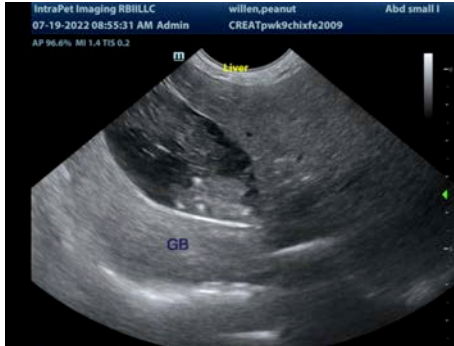Both adrenal glands are large and hypoechoic. These findings would typically be most consistent with pituitary dependent hyperadrenocorticism, but there is some irregularity to the left adrenal gland, which could be consistent with early vascular invasion. Options moving forward would be to continue with evaluation and possible therapy, as if this is most likely pituitary dependent, with close continued monitoring of the left adrenal gland with ultrasound. Alternately, you could consider a contrast CT scan to get better resolution and views of the adrenal glands to look for additional evidence, which could merit surgical removal.

I suspect the enlarged heterogeneous liver is secondary to the adrenomegaly, and possibly a steroid hepatopathy.

Consider starting Ursodiol and continued monitoring of the gallbladder to make sure that it does not progress to a surgical lesion.

- Recommend blood pressure evaluation both for the proteinuria reported and for possible adrenal lesions.
- Consider adrenal function testing (possibly an ACTH stimulation test, as this may be less affected by non-adrenal illness).
- Consider three view thoracic radiographs to rule out concurrent thoracic disease/involvement.
- Recommend starting Ursodiol therapy and continued monitoring of the gallbladder.
- Consider contrast CT scan to further evaluate the adrenal glands. If PDH is suspected, and adrenal function testing correlate with this, consider medical management. If early vascular invasion is noted, then consider surgical evaluation, as this could have a positive outcome, as this is an early/mild lesion.





**The information and recommendations provided are based on the images presented by the referring veterinarian/sonographer. No evaluation can be communicated regarding pathology that was not visible in the image/video clips provided.**

Thank you for this referral. If the clinical or image interpretation does not parallel your findings or if I can be of any further assistance please contact me.

Kathleen Sennello DVM,MS, Diplomate ACVIM (Small animal Internal Medicine)  
kathleen.sennello@sonopath.com