

**DATE PRESENTING CLINICAL SIGNS**

7/19/22

Presented for history of intermittent vomiting and diarrhea of 4-5 weeks duration. Diarrhea will gradually progress from firm to soft then became liquid. Vomited 1 week after diarrhea started, bile, yellowish and clear

PATIENT

Buster Yost

O starting feed p ground turkey white rice and pumpkin for upset stomach which seems to help. Stool is more firm but when O tried to return back to normal diet diarrhea returned despite probiotics.

E/D normal, activity normal. Exam unremarkable other than 2 lb weight loss over a 2 week period. Bloodwork shows low albumin.

SPECIES

Canine

Current Medications: Metronidazole 250 mg 1/2 t BID started 7/13

Provable 1 capsule daily, Royal Canin GI low fat diet

BREED

Boston Terrier

Lab Results: T Pro- 4.1 (5-7.4), ALB- 2.2 (2.7- 4.4), fecal neg

Date of Previous IntraPet Ultrasound: No previous.

Sedation: Not required to complete full diagnostic ultrasound.

Stat Report: Not requested.

SEX

Neutered Male

ULTRASONOGRAPHIC EXAMINATION OF THE ABDOMEN**Urinary System**

The urinary bladder is moderately distended with anechoic urine. The Bladder wall, trigone, ureteral papillae and visible urethra (to a depth of 2cm) appear normal with no evidence of wall thickening, mucosal irregularities, masses or cystic calculi.

AGE

9/9/15

WEIGHT

27.3 Pounds

The prostate is normal in size (0.72 cm) and shape for this neutered male dog. The parenchyma is homogenous and the external margins are smooth. The prostatic urethra appears normal with no evidence of irregularity, invasion, mass effect or calculi.

INTERPRETED BY

Kathleen Sennello DVM,
MS, Diplomate ACVIM
(Small Animal Internal
Medicine)

The left kidney has a normal shape and size (5.02 cm). Overall echogenicity is normal with adequate corticomedullary distinction and a typical 1:3 cortex:medulla ratio. There is no evidence of perinephric inflammation or effusion. There is no evidence of pyelectasia, nephroliths, infarcts or hydroureter. Renal vasculature is normal.

IMAGING PERFORMED BY

Stephanie Pearce
RDCS, RVT

The right kidney has a normal shape and size (4.67 cm). Overall echogenicity is normal with adequate corticomedullary distinction and a typical 1:3 cortex:medulla ratio. There is no evidence of perinephric inflammation or effusion. There is no evidence of pyelectasia, nephroliths, infarcts or hydroureter. Renal vasculature is normal.

HOSPITAL NAME

Fullerton AH

Adrenal Glands

The left adrenal gland is normal in size measuring 0.62 cm at the caudal pole. It is observed in its normal position cranial to the left renal artery. It is normal in appearance (uniformly hypoechoic) and shape with no evidence of a mass effect.

REFERRING VET

Dr. Unger

The right adrenal gland is normal in size measuring 0.70 cm at the caudal pole. It is observed in its normal position between the cranial aspect of the right kidney and the caudal vena cava. It is normal in appearance (uniformly hypoechoic) and shape with no evidence of a mass effect.

INVOICE

39646

Spleen

The spleen is subjectively normal in size. The spleen echotexture is heterogenous and mottled, the splenic capsule is smooth with no irregularities. The blood flow through the hilus and splenic parenchyma appears normal. No focal parenchymal abnormalities are visualized.

Liver

The liver is subjectively normal in size, and echogenicity with smooth peripheral margins. The parenchyma is homogenous echotexture. The visible portions of the vasculature and biliary tract appear normal. No focal nodules or cystic lesions are observed.

The gallbladder lumen is moderately distended. The wall of the gall bladder is not thickened and has a smooth mucosal surface. Luminal contents are primarily anechoic. The cystic and common bile ducts are normal/not visible.

Gastrointestinal

The stomach contains minimal luminal contents. It measures at a normal thickness of <0.7cm with some variability due to the presence of rugal folds. The distinction of the gastric wall layers is adequate and there is no impression of reduced peristaltic activity. No masses or focal lesions were observed.

The visualized areas of duodenum, jejunum and ileum have a uniform diameter with minimal fluid distension. Wall thickness is increased. Bowel loops follow a typical curvilinear path. Some areas have reduced detail of wall layering. Duodenum wall measured 0.42 cm. Jejunum wall measured 0.36 cm. There is moderate mucosal speckling visualized. Visualized peristalsis appears appropriate. There were no focal lesions consistent with obstruction or a mass effect observed.

The ileocecal junction was visualized and exhibited normal intact wall layering and is subjectively of normal thickness. Sections of colon are visualized with formed fecal material and gas shadowing distally. There is no observed focal or generalized colon wall thickening or loss of layering.

Pancreas

The pancreas is prominent and hypoechoic as compared to the surrounding isoechoic mesentery. There is no evidence of nodules or cystic lesions. There is no evidence of regional mesenteric inflammation or fluid.

Free Abdomen

There is scant free abdominal fluid. No significant lymphadenopathy. The omentum appears hyperechoic around some of the abnormal bowel loops.

ULTRASONOGRAPHIC FINDINGS

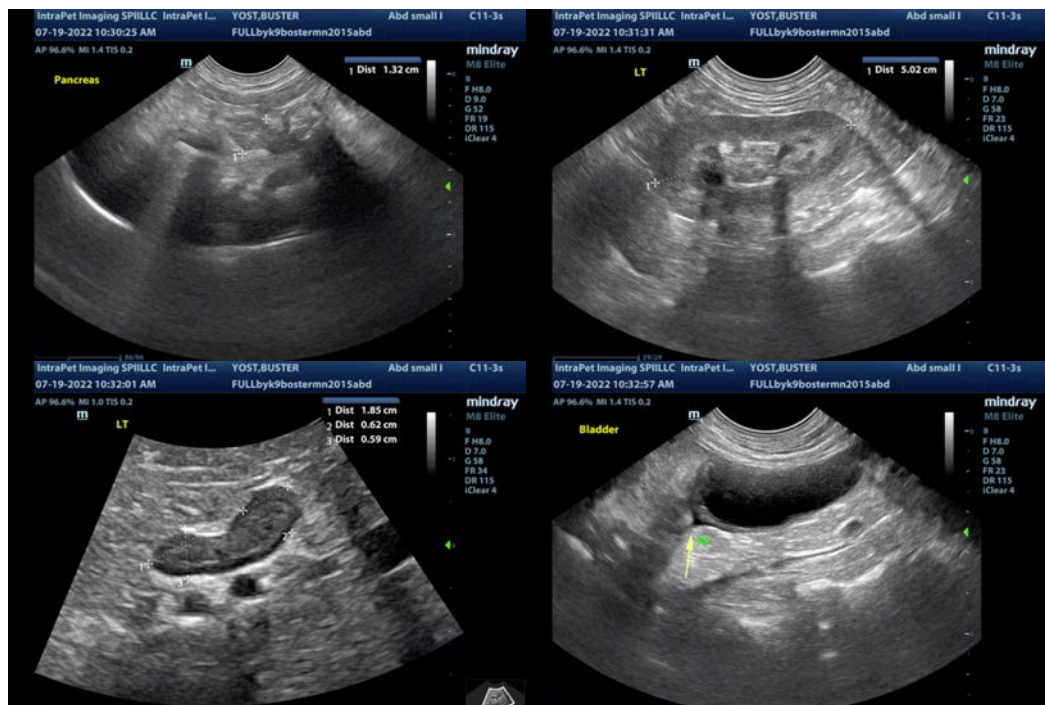
- Subjectively mildly mottled spleen – The diffuse splenic changes are non-specific and could be consistent with lymphoid hyperplasia, extramedullary hematopoiesis, infiltrative neoplasia, inflammation, other. Cytology or histopathology would be necessary to get a definitive diagnosis. These changes are mild and could be within normal limits for this individual.
- Prominent, hypoechoic pancreas – The pancreatic changes are most consistent with mild pancreatitis or a recent episode of pancreatic inflammation.
- Mildly thickened small intestine with moderate mucosal speckling – Bright mucosal speckling has been proposed to represent dilated lacteals or focal accumulation of mucus, cellular debris etc.. in the mucosal crypts of the small intestine.
- Scant free abdominal fluid

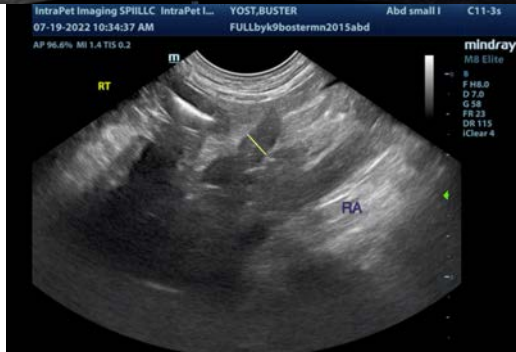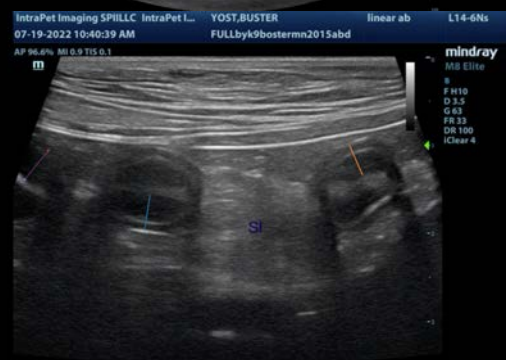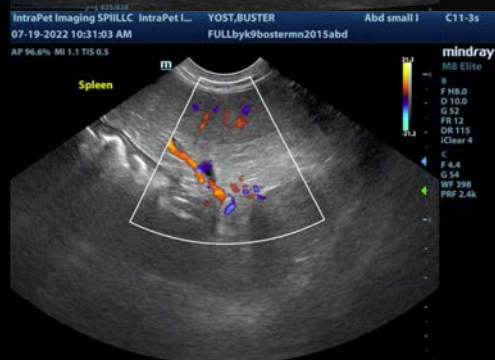
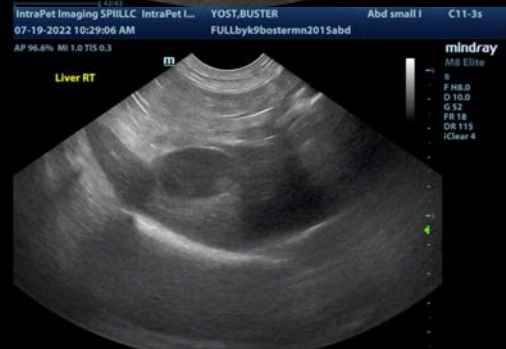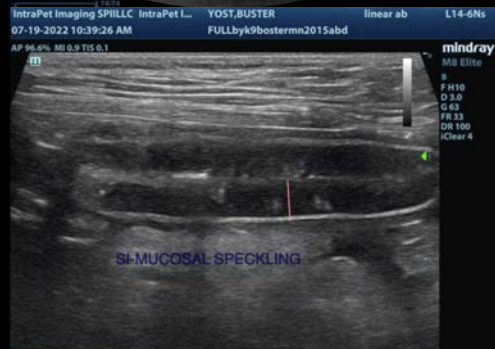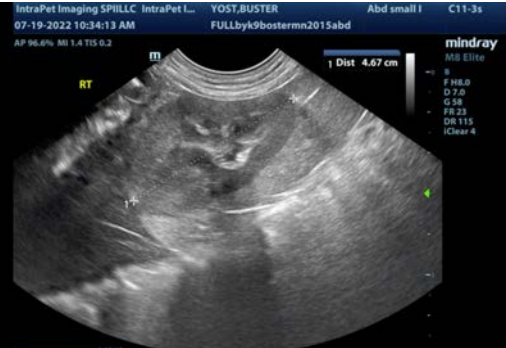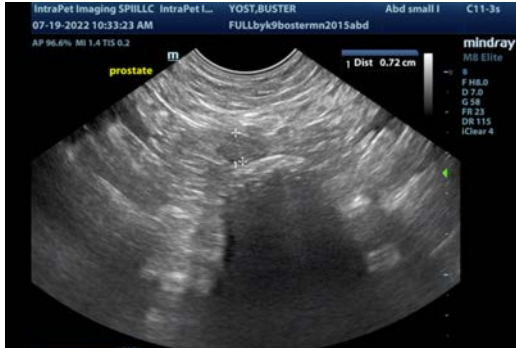INTERPRETATION OF THE FINDINGS & FURTHER RECOMMENDATIONS

Based on the changes observed in the GI tract, and the clinical signs presented in the history, there is the concern for an underlying protein losing enteropathy. Recommend a urine protein to creatinine ratio,

urinalysis, and a liver function test (pre- and post-prandial bile acids) to rule out the possibility of concurrent hypoalbuminemia due to renal protein loss or liver dysfunction.

- Consider such differentials as inflammatory GI Disease such as IBD, severe dietary intolerance, etc., lymphangiectasia, intestinal neoplasia, etc.
- Recommend a GI panel to Texas A&M for a qualitative PLI, TLI, cobalamin and folate to further evaluate the pancreas and small intestine.
- Initially, continue an ultra low-fat diet while additional diagnostics are pending.
- Recommend screening for Addison's disease.
- Consider chronic probiotic therapy.
- Recommend 3-view thoracic radiographs.
- If additional diagnostics point to a protein losing enteropathy, then recommend GI biopsies, as treatment recommendations and prognosis will vary greatly depending on the underlying intestinal disease present.





The information and recommendations provided are based on the images presented by the referring veterinarian/sonographer. No evaluation can be communicated regarding pathology that was not visible in the image/video clips provided.

Thank you for this referral. If the clinical or image interpretation does not parallel your findings or if I can be of any further assistance please contact me.

Kathleen Sennello DVM,MS, Diplomate ACVIM (Small animal Internal Medicine)
kathleen.sennello@sonopath.com