

**DATE PRESENTING CLINICAL SIGNS**

7/14/23

Patient presented 07/12/2023 for a 4 day history of vomiting and inappetance. Multiple episodes of vomiting day of presentation (water). Physical exam demonstrated sl tense and cranial organomegaly. Scant diarrhea on rectal. H/L auscult NSF. Abdominal radiographs- decreased detail (mass effect) cranial abdomen.

PATIENT

Harlee Young

SPECIES

Canine

BREED

Shepherd X

SEX

Spayed Female

AGE

10/18/12

WEIGHT

81.3 Pounds

INTERPRETED BY

Kathleen Sennello DVM,
MS, Diplomate ACVIM
(Small Animal Internal
Medicine)

HOSPITAL NAME

Hickory Vet Hospital

REFERRING VET

Dr. McNesby

INVOICE

43829

Current Medications: Cerenia 37 mg IV 7/12/2023, Cerenia 80 mg PO Q24 hours started 7/13/2023.
Lab Results: See attached.
Date of Previous IntraPet Ultrasound: No previous.
Sedation: Not required to complete full diagnostic ultrasound.
Stat Report: stat requested.
Imaging Performed By: Andi Parkinson, BS, RDMS.

ULTRASONOGRAPHIC EXAMINATION OF THE ABDOMEN**Urinary System**

The urinary bladder is moderately distended with anechoic urine. The Bladder wall, trigone, ureteral papillae and visible urethra (to a depth of 2cm) appear normal with no evidence of wall thickening, mucosal irregularities, masses or cystic calculi.

The left kidney has a normal shape and size (6.96 cm). Overall echogenicity is normal with adequate corticomedullary distinction and a typical 1:3 cortex:medulla ratio. There is no evidence of focal perinephric inflammation or effusion. There is no evidence of pyelectasia, nephroliths, infarcts or hydroureter. Renal vasculature is normal.

The right kidney has a normal shape and size (6.2 cm). Overall echogenicity is normal with adequate corticomedullary distinction and a typical 1:3 cortex:medulla ratio. There is no evidence of focal perinephric inflammation or effusion. There is no evidence of pyelectasia, nephroliths, infarcts or hydroureter. Renal vasculature is normal.

Adrenal Glands

The left adrenal gland is normal in size measuring 0.59 cm at the caudal pole. It is observed in its normal position cranial to the left renal artery. It is normal in appearance (uniformly hypoechoic) and shape with no evidence of a mass effect.

The region of the right adrenal (between right cranial kidney and vena cava) is unremarkable, but the adrenal is not distinctly visualized. No evidence of a mass effect is visualized.

Spleen

The spleen is subjectively normal in size, echotexture is homogenous, and the splenic capsule is smooth with no irregularities. The blood flow through the hilus and splenic parenchyma appears normal. No focal parenchymal abnormalities are visualized.

Liver

The liver is large and irregular. The parenchyma is homogenous echotexture. The visible portions of the vasculature and biliary tract appear normal. There are too numerous to count, large, expansile, hypoechoic (sometimes target lesion appearing) masses and nodules throughout the liver. Examples measure 4.26 cm x 5.12 cm, 3.15 cm, 3.75 cm in diameter, and nodules vary in size from 0.25-2.0 cm. The nodules are expansile and have criteria for malignancy.

The gallbladder lumen is moderately distended. The wall of the gall bladder is not thickened and has a smooth mucosal surface. Luminal contents are mild and primarily anechoic. The cystic and common bile ducts are normal/not visible.

Gastrointestinal

The stomach contains minimal luminal contents. It measures at a normal thickness of <0.7cm with some variability due to the presence of rugal folds. The distinction of the gastric wall layers is adequate and there is no impression of reduced peristaltic activity. No masses or focal lesions were observed.

The visualized areas of duodenum, jejunum and ileum have a relatively uniform diameter with minimal fluid distension. Wall thickness is normal. Bowel loops follow a curvilinear path with distinct wall layering maintaining the typical 1:3 muscularis:mucosa layer ratio. The duodenum measured as normal (between 0.3-0.5cm in wall thickness) and the jejunum measured as normal (between 0.2-0.47cm.) Visualized peristalsis appears appropriate. There were no focal lesions consistent with obstruction or a mass effect observed.

The ileocecal junction was visualized and exhibited normal intact wall layering and is subjectively of normal thickness. Sections of colon are visualized with formed fecal material and gas shadowing distally. There is no observed focal or generalized colon wall thickening or loss of layering.

Pancreas

The area of the pancreas is normal and isoechoic to surrounding mesentery. There is no evidence of nodules or cystic lesions. There is no evidence of regional mesenteric inflammation or fluid.

Free Abdomen

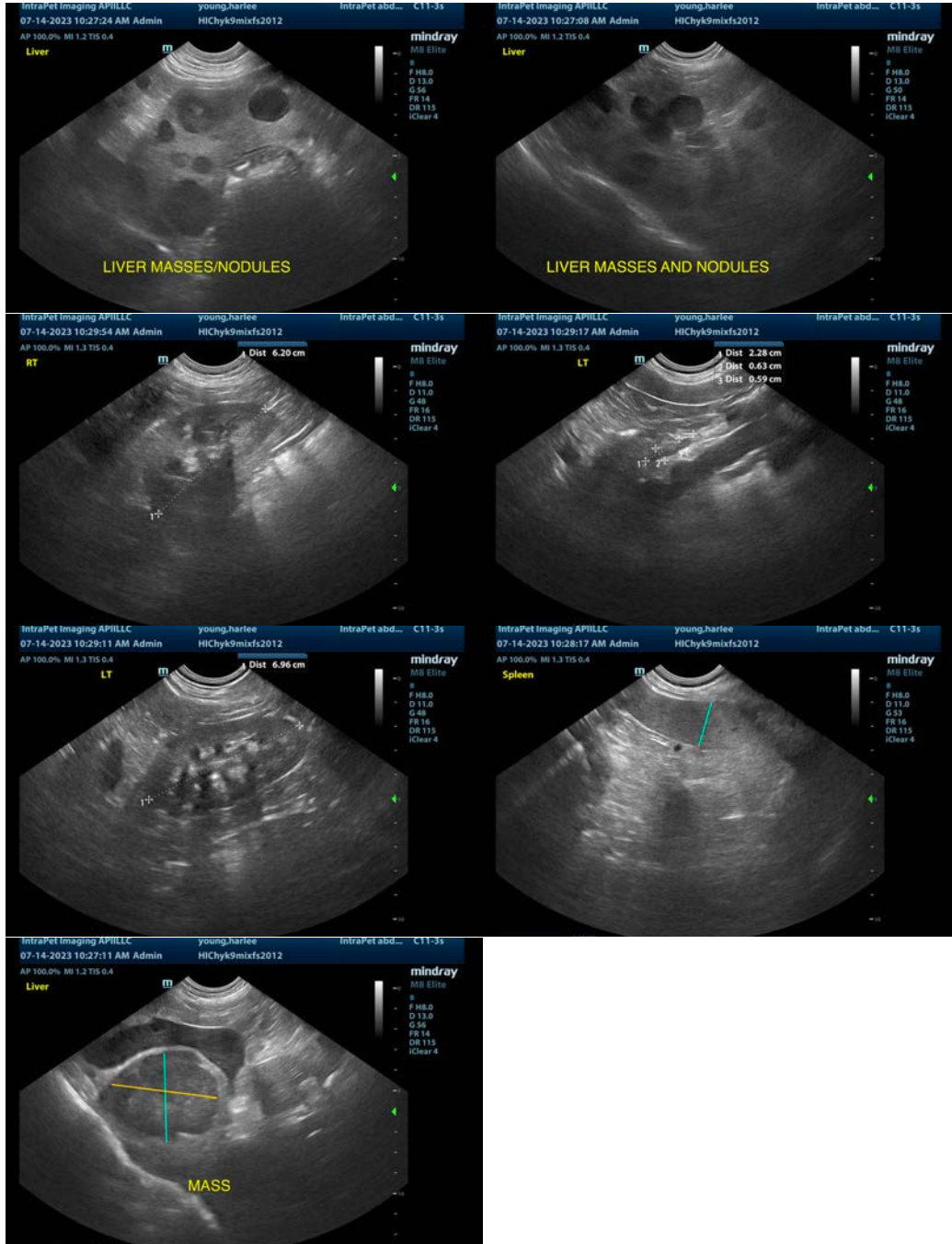
Evaluation of the peritoneal cavity did not reveal any evidence of effusion, or subjective lymphadenomegaly. The Medial iliac nodes appear normal and there was no evidence of a caudal aortic thrombus at the bifurcation. The omentum is of normal uniform echogenicity.

ULTRASONOGRAPHIC FINDINGS

- Too numerous to count, variably sized, hypoechoic, expansile mass lesions/nodules throughout the liver – Findings are highly concerning for metastatic neoplasia.

INTERPRETATION OF THE FINDINGS & FURTHER RECOMMENDATIONS

There are too numerous to count, hypoechoic, expansile masses and nodules visualized throughout the liver. These lesions deviate the hepatic margins and have criteria for malignancy. They likely represent a metastatic neoplastic process, although a primary lesion is not identified. Recommend 3-view thoracic radiographs, careful evaluation of cutaneous tissues, bony tissues, and a rectal exam. Consider a fine needle aspirate of a hepatic mass/nodule, and consultation with a veterinary oncologist regarding possible treatment options.



The information and recommendations provided are based on the images presented by the referring veterinarian/sonographer. No evaluation can be communicated regarding pathology that was not visible in the image/video clips provided.

Thank you for this referral. If the clinical or image interpretation does not parallel your findings or if I can be of any further assistance please contact me.

Kathleen Sennello DVM,MS, Diplomate ACVIM (Small animal Internal Medicine)
info@sonopath.com