

IMAGING PERFORMED BY

IntraPet.com



SonoPath

Clinical Sonography & Telectology

EDUCATIONAL TELECONSULTATION SERVICES™

1-800-838-4268 info@sonopath.com SonoPath.com

DATE PRESENTING CLINICAL SIGNS

7/14/22 Owner stated that Sparky had excessive drooling and that he is not urinating much. Not eating much.

PATIENT Current Medications: None listed.

Sparky Richmond

Lab Results: See attached.

Date of Previous IntraPet Ultrasound: No previous.

Sedation: Not required to complete full diagnostic ultrasound.

Stat Report: Not requested.

SPECIES

Feline

ULTRASONOGRAPHIC EXAMINATION OF THE ABDOMEN

BREED *Urinary System*

DSH

The urinary bladder is moderately distended with anechoic urine. The Bladder wall, trigone, ureteral papillae and visible urethra (to a depth of 2cm) appear normal with no evidence of wall thickening, mucosal irregularities, masses or cystic calculi.

SEX

Neutered Male

The left kidney has a normal shape and size (4.1 cm) with mild pyelectasia at 0.18 cm. Overall echogenicity is slightly hyperechoic with poor corticomedullary distinction and a typical 1:3 cortex:medulla ratio. There is no evidence of perinephric inflammation or effusion. There is no evidence of nephroliths, infarcts or hydroureter. Renal vasculature is normal.

AGE

4/23/05

The right kidney has a normal shape and size (3.3 cm) with pyelectasia at 0.16 cm. Overall echogenicity is slightly hyperechoic with poor corticomedullary distinction and a typical 1:3 cortex:medulla ratio. There is no evidence of perinephric inflammation or effusion. There is no evidence of pyelectasia, nephroliths, infarcts or hydroureter. Renal vasculature is normal.

WEIGHT

7.9 Pounds

Adrenal Glands

INTERPRETED BY

Kathleen Sennello DVM,
MS, Diplomate ACVIM
(Small Animal Internal
Medicine)

The left adrenal gland is normal in size measuring 0.37 cm at the caudal pole. It is observed in its normal position cranial to the left renal artery. It is normal in appearance (uniformly hypoechoic) and shape with no evidence of a mass effect.

The right adrenal gland is normal in size measuring 0.38 cm at the caudal pole. It is observed in its normal position between the cranial aspect of the right kidney and the caudal vena cava. It is normal in appearance (uniformly hypoechoic) and shape with no evidence of a mass effect.

IMAGING PERFORMED BY

Andi Parkinson RDMS

Spleen

The spleen is subjectively normal in size (0.67 cm in width at the level of the hilus), echotexture is homogenous, and the splenic capsule is smooth with no irregularities. The blood flow through the hilus and splenic parenchyma appears normal. No focal parenchymal abnormalities are visualized.

HOSPITAL NAME

Glen Burnie AH

Liver

The liver is subjectively normal in size with smooth peripheral margins. The parenchyma is hyperechoic and homogenous in echotexture. The visible portions of the vasculature and biliary tract appear normal. There is an ill-defined, hyperechoic nodule visualized in the left side of the liver measuring 0.86 cm in diameter.

REFERRING VET

Dr. Shah

INVOICE

39527

The gall bladder lumen is moderately distended. The wall of the gall bladder is not thickened and has a smooth mucosal surface. There is a moderate amount of non-organized echogenic debris. The cystic and common bile ducts are normal/not visible.

Gastrointestinal

The stomach contains a small amount of intraluminal shadowing material. It measures at a normal thickness of <0.36cm with some variability due to the presence of rugal folds. The distinction of the gastric wall layers is adequate and there is no impression of reduced peristaltic activity. No masses or focal lesions were observed.

The visualized areas of duodenum, jejunum and ileum have a relatively uniform diameter with minimal fluid distension. Wall thickness is normal. Bowel loops follow a curvilinear path with distinct wall layering maintaining the typical 1:3 muscularis:mucosa layer ratio. Jejunum wall measured 0.28 cm. Visualized peristalsis appears appropriate. There were no focal lesions consistent with obstruction or a mass effect observed.

The ileocecal junction was visualized and exhibited normal intact wall layering and is subjectively of normal thickness. Sections of colon are visualized with formed fecal material and gas shadowing distally. There is no observed focal or generalized colon wall thickening or loss of layering.

Pancreas

The pancreas is normal and isoechoic to surrounding mesentery. There is no evidence of nodules or cystic lesions. There is no evidence of regional mesenteric inflammation or fluid.

Free Abdomen

Evaluation of the peritoneal cavity did not reveal any evidence of effusion, or subjective lymphadenomegaly. The Medial iliac nodes appear normal and there was no evidence of a caudal aortic thrombus at the bifurcation. The omentum is of normal uniform echogenicity.

ULTRASONOGRAPHIC FINDINGS

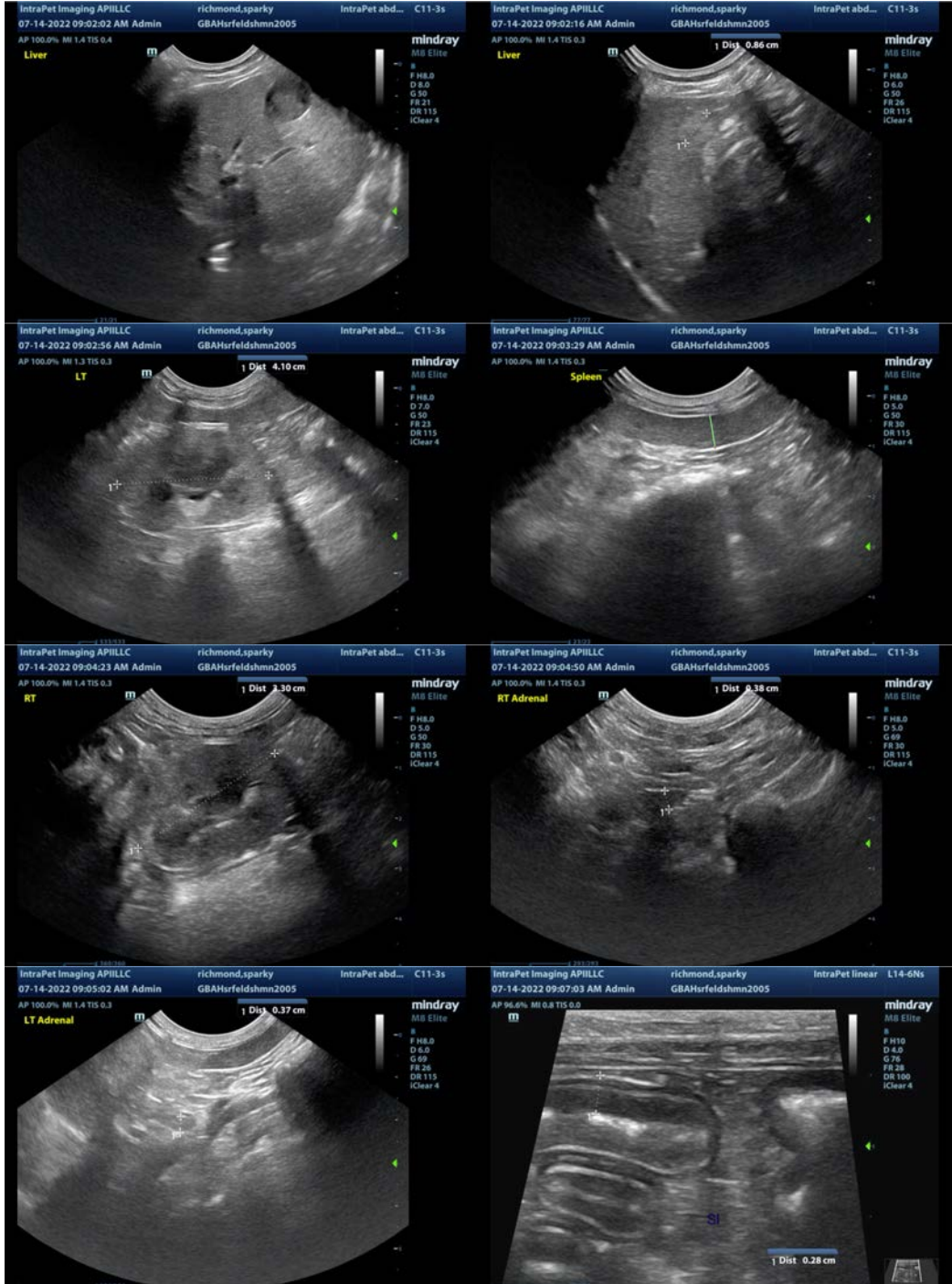
- Hyperechoic liver with ill-defined hyperechoic nodule – Hepatic changes are non-specific and could be consistent with hepatic lipidosis, inflammatory/infectious disease, infiltrative neoplasia, or other hepatopathy.
- Moderate gallbladder debris – The significance of the aggregated gallbladder sludge is unclear. This could represent an early mucocele, cholestasis, or may be secondary to fasting.
- Mildly reduced corticomedullary distinction in both kidneys with bilateral pyelectasia – The bilateral renal findings are consistent with age-related change. Pyelectasia of the left/right kidney could be consistent with pyelonephritis, chronic renal disease, secondary to PU/PD or fluid therapy (if applicable), other.

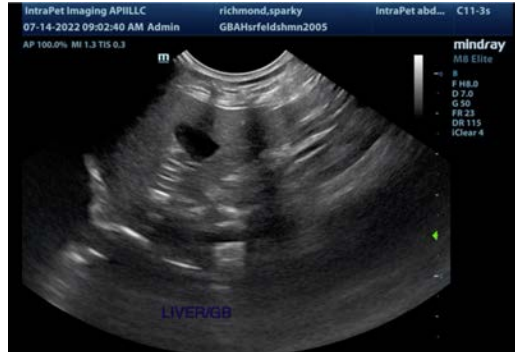INTERPRETATION OF THE FINDINGS & FURTHER RECOMMENDATIONS

No focal mass lesions or focal hepatic or bowel lesions are visualized on today's exam. The liver is generally hyperechoic. This is a non-specific finding that could be secondary to historical anorexia, or could be due to a primary hepatopathy. Consider pre- and post-prandial bile acids to evaluate liver function, and a fine needle aspirate of the liver, as long as coagulation parameters are within a safe range.

There are chronic age related changes observed in the kidneys, along with mild pyelectasia. Recommend a urinalysis and culture to ensure there is no evidence of pyelonephritis. There is a fair amount of gas visualized within the GI tract, and some mild shadowing in the stomach. Correlate these findings with abdominal radiographs, looking for any evidence of foreign material, etc. This patient is mildly hypoglycemic. This can be seen in a thin cat due to a debilitated state and anorexia, secondary to liver disease, sepsis, and much less likely an insulin secreting tumor, etc.

Consider three view thoracic radiographs to rule out concurrent thoracic disease/involvement.





The information and recommendations provided are based on the images presented by the referring veterinarian/sonographer. No evaluation can be communicated regarding pathology that was not visible in the image/video clips provided.

Thank you for this referral. If the clinical or image interpretation does not parallel your findings or if I can be of any further assistance please contact me.

Kathleen Sennello DVM,MS, Diplomate ACVIM (Small animal Internal Medicine)
kathleen.sennello@sonopath.com