

PATIENT

Potato Tucker

SPECIES

Canine

BREED

Terrier x

SEX

Neutered Male

AGE

01/19/2015

WEIGHT

20lbs

INTERPRETED BY

Kathleen Sennello DVM,
MS, Diplomate ACVIM
(Small Animal Internal
Medicine)

IMAGING PERFORMED BY

Loetitia Saint-Jacques,
LVT

HOSPITAL NAME

Sierra Animal Wellness
Center

REFERRING VET

Dr. Peggy Roberts

INVOICE

10318

DATE

7/13/2023

PRESENTING CLINICAL SIGNS

History of calcium oxalate bladder stones surgically removed in 2019. Was fed RC urinary SO after surgery. In 11/21 first seen at our clinic for hematuria. Abd xrays revealed sm radiodense debris. We have been following him with periodic xrays and the radiodense debris hasn't cleared but is smaller. He is also being treated with potassium citrate. He came in for a possible foxtail in his foot, so we took follow up abdominal xrays and saw hepatomegaly and a possible gall bladder stone. His lab work has also been sent.

ULTRASONOGRAPHIC EXAMINATION OF THE ABDOMEN

Urinary System

The urinary bladder is moderately distended with anechoic urine. The Bladder wall, trigone, ureteral papillae, and visible urethra (to a depth of 2cm) appear normal with no evidence of wall thickening, mucosal irregularities, or masses. The dependent portion of the urinary bladder there is a large pile of small hyperechoic shadowing calculi. One of these visualized measures at 0.35 cm. Recommend a urine analysis and culture.

The prostate is normal in size (0.68 cm) and shape for this neutered male dog. The parenchyma is homogenous, and the external margins are smooth. The prostatic urethra appears normal with no evidence of irregularity, invasion, mass effect, or calculi.

The left kidney has a normal shape and size (4.86 cm). Overall echogenicity is normal with adequate corticomedullary distinction and a typical 1:3 cortex: medulla ratio. There is no evidence of focal perinephric inflammation or effusion. There is no evidence of pyelectasia, nephroliths, infarcts or hydroureter. Renal vasculature is normal.

The right kidney has a normal shape and size (4.53 cm). Overall echogenicity is normal with adequate corticomedullary distinction and a typical 1:3 cortex: medulla ratio. There is no evidence of focal perinephric inflammation or effusion. There is no evidence of pyelectasia, nephroliths, infarcts or hydroureter. Renal vasculature is normal.

Adrenal Glands

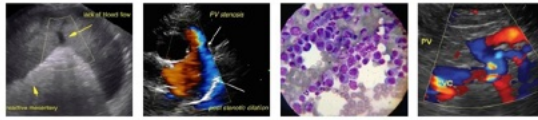
The left adrenal gland is normal in size measuring 0.39 cm at the caudal pole. It is observed in its normal position cranial to the left renal artery. It is normal in appearance (uniformly hypoechoic) and shape with no evidence of a mass effect.

The right adrenal gland is normal in size measuring 0.45 cm at the caudal pole. It is observed in its normal position between the cranial aspect of the right kidney and the caudal vena cava. It is normal in appearance (uniformly hypoechoic) and shape with no evidence of a mass effect.

Spleen

The spleen is subjectively normal in size and slightly irregular in shape, echotexture is homogenous, and the splenic capsule is smooth with no irregularities. The blood flow through the hilus and splenic parenchyma appears normal. There is a hypoechoic target-like nodule visualized within the splenic parenchyma (center is almost anechoic) measuring 1.31 cm x 1.87 cm.

Liver



PATIENT

Potato Tucker

The liver is large in size, and normal in echogenicity with smooth peripheral margins. The parenchyma is heterogenous in echotexture with subtle, indistinct focal mottling. The visible portions of the vasculature and biliary tract appear normal. No focal nodules or cystic lesions are observed.

SPECIES

Canine

The gallbladder lumen is moderately distended. The wall of the gall bladder is not thickened and has a smooth mucosal surface. There is a moderate amount of hyperechoic shadowing debris visualized within the gallbladder. Most consistent with small choleliths and mineralized debris. Additionally, there is which could be some organized debris or tissue. There is minimal uptake on color flow. The cystic and common bile ducts are normal/not visible.

BREED

Terrier x

Gastrointestinal

SEX

Neutered Male

The stomach contains moderate shadowing ingesta and fluid. It measures at a normal thickness of <0.7cm with some variability due to the presence of rugal folds. The distinction of the gastric wall layers is adequate and there is no impression of reduced peristaltic activity. No masses or focal lesions were observed.

AGE

01/19/2015

The visualized areas of duodenum, jejunum and ileum have a relatively uniform diameter with minimal fluid distension. Wall thickness is normal. Bowel loops follow a curvilinear path with distinct wall layering maintaining the typical 1:3 muscularis: mucosa layer ratio. The duodenum measured as normal (0.37 cm), and the jejunum measured as normal (0.33 cm.) Visualized peristalsis appears appropriate. There were no focal lesions consistent with obstruction or a mass effect observed.

WEIGHT

20lbs

The ileocecal junction was visualized and exhibited normal intact wall layering and is subjectively of normal thickness. Sections of colon are visualized with formed fecal material and gas shadowing distally. There is no observed focal or generalized colon wall thickening or loss of layering.

INTERPRETED BY

Kathleen Sennello DVM,
MS, Diplomate ACVIM
(Small Animal Internal
Medicine)

Pancreas

The pancreas is prominent and mottled in the right limb compared to the surrounding isoechoic mesentery. There is no evidence of nodules or cystic lesions. There is no evidence of regional mesenteric inflammation or fluid.

IMAGING PERFORMED BY

Loetitia Saint-Jacques,
LVT

Free Abdomen

Evaluation of the peritoneal cavity did not reveal any evidence of effusion, or subjective lymphadenomegaly. The Medial iliac nodes appear normal and there was no evidence of a caudal aortic thrombus at the bifurcation. The omentum is of normal uniform echogenicity.

HOSPITAL NAME

Sierra Animal Wellness
Center

Other

The right auricle and pericardium were visualized and were unremarkable. No obvious pathology is visualized. If cardiac function evaluation is desired a full echocardiogram is warranted.

REFERRING VET

Dr. Peggy Roberts

PRIMARY FINDINGS

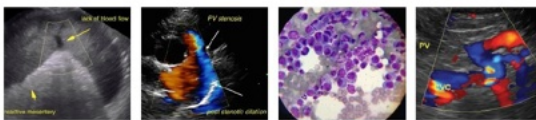
INVOICE

10318

- Dependent mineralize material visualized within the urinary bladder. Findings are most consistent with a large pile of small calculi. Recommend a urine analysis and culture.
- Hypoechoic splenic nodule with an anechoic center. There is a non-cavitated, hypoechoic splenic nodule visualized. Differentials include lymphoid hyperplasia, extramedullary hematopoiesis, infiltrative neoplasia, inflammation, other. Cytology or histopathology would be necessary to get a definitive diagnosis.

DATE

7/13/2023



PATIENT

Potato Tucker

SPECIES

Canine

BREED

Terrier x

SEX

Neutered Male

AGE

01/19/2015

WEIGHT

20lbs

INTERPRETED BY

Kathleen Sennello DVM,
MS, Diplomate ACVIM
(Small Animal Internal
Medicine)

**IMAGING
PERFORMED BY**

Loetitia Saint-Jacques,
LVT

HOSPITAL NAME

Sierra Animal Wellness
Center

REFERRING VET

Dr. Peggy Roberts

INVOICE

10318

DATE

7/13/2023

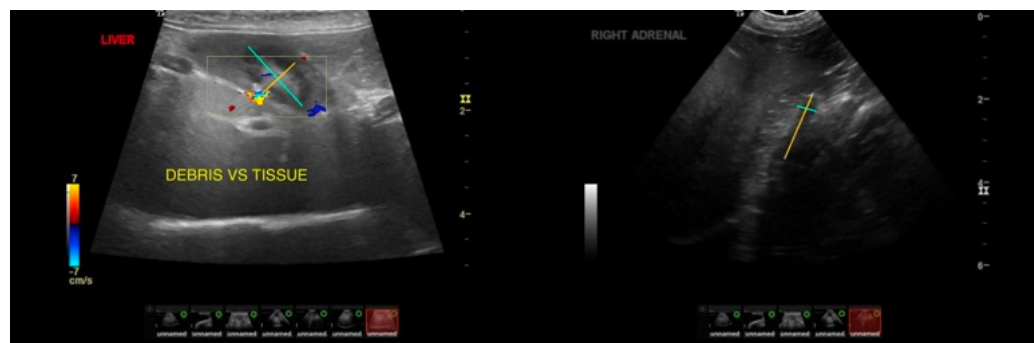- Prominent mottled right limb of the pancreas. The pancreatic changes are most consistent with mild pancreatitis or a recent episode of pancreatic inflammation.
- Large, heterogenous liver. The diffuse hepatic changes are non-specific and could be consistent with vacuolar hepatopathy, nodular hyperplasia, inflammatory/immune-mediated disease, fibrosis, extramedullary hematopoiesis, toxic hepatopathy (e.g., copper), infiltrative neoplasia (less likely) or other hepatopathy.
- Moderate amount of dependent mineralized material visualized within the gallbladder as well as some hypoechoic organized material. Findings are most consistent with choleliths and either organized debris or soft tissue mass effect.
- Shadowing ingesta within the gastric lumen. Correlate with the feeding history. If the patient was adequately fasted consider the possibility of delayed gastric emptying, a partial outflow tract obstruction (functional versus mechanical) (non-observed),

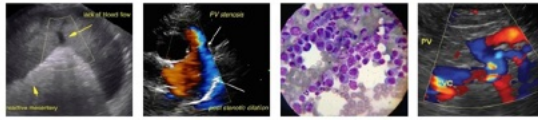
INTERPRETATION OF THE FINDINGS & FURTHER RECOMMENDATIONS

There is a moderate pile of small calculi visualized in the urinary bladder. Recommend a urine analysis and culture and correlate the size and number of the stones with abdominal radiographs. Additionally, there is evidence of mineralized choleliths in the dependent portion of the urinary bladder with minimal surrounding inflammation or wall thickening. There is some abnormal appearing hypoechoic structure which could represent organized debris or a mass effect. Recommend continued monitoring of the gallbladder with ultrasound.

There is a hypoechoic nodule visualized within the spleen. This could represent a benign or neoplastic process. Options moving forward would include continued monitoring with ultrasound or fine needle aspirate.

The pancreas appears somewhat prominent and mottled the significance of this is unclear if the patient is currently asymptomatic. Additionally, the liver is large and heterogenous. Liver enzyme elevations are mild you could consider a Denamarin trial, liver function test, or even a fine needle aspirate to further evaluate.





PATIENT

Potato Tucker

SPECIES

Canine

BREED

Terrier x

SEX

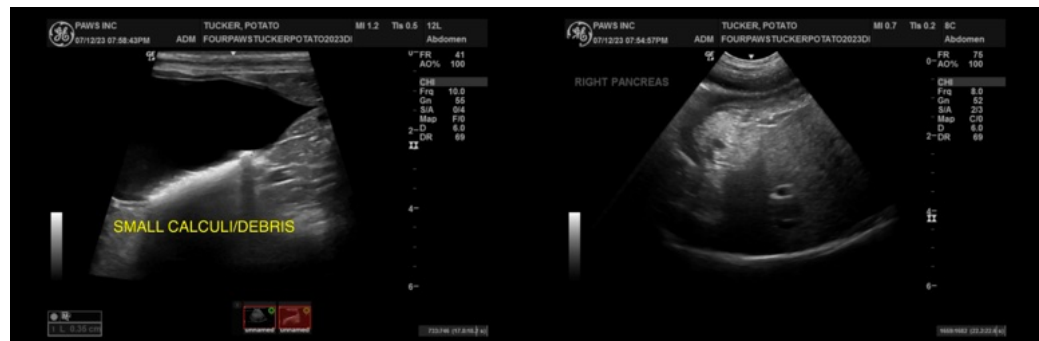
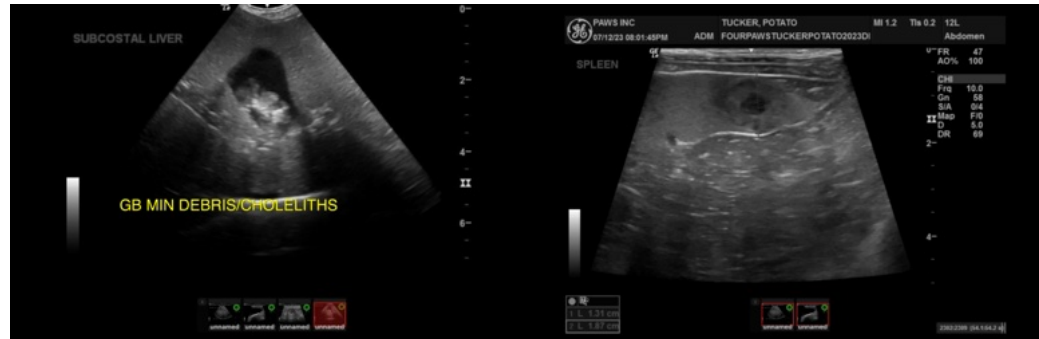
Neutered Male

AGE

01/19/2015

WEIGHT

20lbs

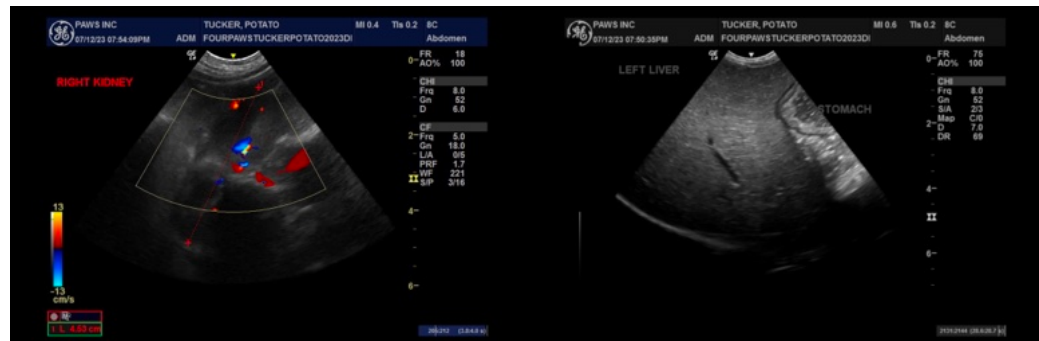


INTERPRETED BY

Kathleen Sennello DVM,
MS, Diplomate ACVIM
(Small Animal Internal
Medicine)

IMAGING PERFORMED BY

Loetitia Saint-Jacques,
LVT



HOSPITAL NAME

Sierra Animal Wellness
Center

REFERRING VET

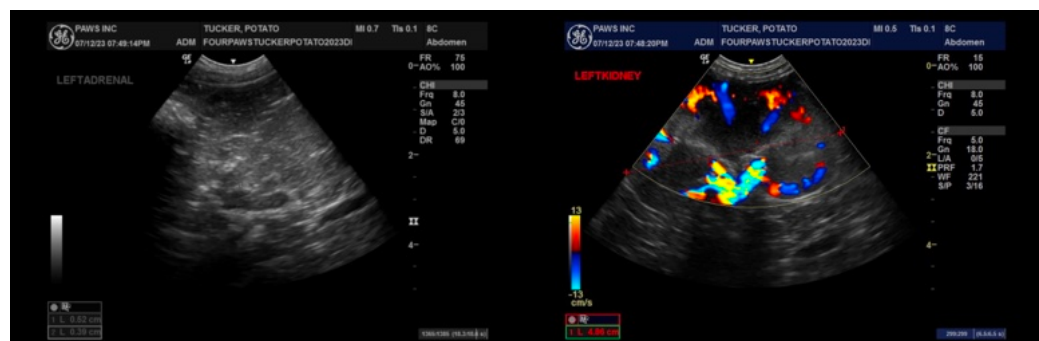Dr. Peggy Roberts

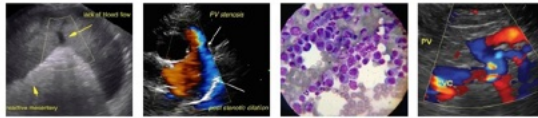
INVOICE

10318

DATE

7/13/2023





PATIENT

Potato Tucker

SPECIES

Canine

BREED

Terrier x

SEX

Neutered Male

AGE

01/19/2015

WEIGHT

20lbs

INTERPRETED BY

Kathleen Sennello DVM,
MS, Diplomate ACVIM
(Small Animal Internal
Medicine)

**IMAGING
PERFORMED BY**

Loetitia Saint-Jacques,
LVT

HOSPITAL NAME

Sierra Animal Wellness
Center

REFERRING VET

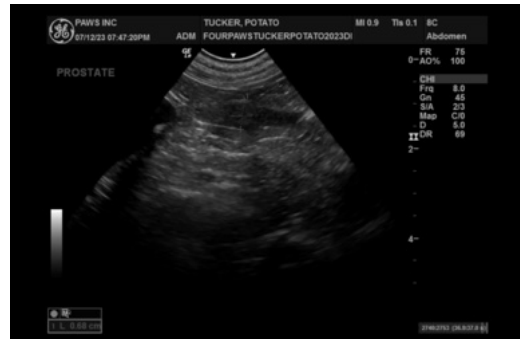Dr. Peggy Roberts

INVOICE

10318

DATE

7/13/2023



The information and recommendations provided are based on the images presented by the referring veterinarian/sonographer. No evaluation can be communicated regarding pathology that was not visible in the image/video clips provided.

Thank you for this referral. If the clinical or image interpretation does not parallel your findings or if I can be of any further assistance, please contact me.

Kathleen Sennello DVM, MS, Diplomate ACVIM (Small animal Internal Medicine)

info@sonopath.com