

**PATIENT**

Hollie Griffiths 52102A

SPECIES

Canine

BREED

Dachshund

SEX

Spayed Female

AGE

4 Years 10 Months

WEIGHT

5.18 kg

INTERPRETED BYKathleen Sennello DVM,
MS, Diplomate ACVIM
(Small Animal Internal
Medicine)**IMAGING
PERFORMED BY**

Tom McNeill

HOSPITAL NAME

SVS Imaging CT

REFERRING VET

MVS- Dr. Alucard

INVOICE

39494

DATE

7/12/22

PRESENTING CLINICAL SIGNS

Last Tuesday Hillie started acting off - she seemed more lethargic at home, and anxious. On Wednesday she started to cry out in pain whenever the owners touched her and they took her to an ER vet to be evaluated. They treated her for constipation and gave her an enema as part of outpatient care. On Thursday they showed no improvement so they started on lactulose. She still showed no improvement on lactulose so they returned to the ER on Saturday where they did abdominal x-rays/barium study and full bloodwork. That night they sent her home with Gabapentin and instructed them to feed a bland diet. On Sunday and Monday she was eating and had a large bowel movement on Sunday. Last night she did not want to eat. She has not been vomiting, having diarrhea, coughing or sneezing. The weekend before she started acting off she did get bacon and steak as table scraps. Per the owner she does not typically get into anything or ingest anything that she should not, but also as a puppy she did ingest a medication and needed ICU care as she almost died (per the owner).

Abnormal PE/Chem/CBC/UA Results: Extremely tense and painful abdomen (CSU score 2-3); GI loops could not be palpated; kidney poles and bladder could not be felt Bloodwork from pDVM was unremarkable.

ULTRASONOGRAPHIC EXAMINATION OF THE ABDOMEN**Urinary System**

The urinary bladder is moderately distended with anechoic urine. The Bladder wall, trigone, ureteral papillae and visible urethra (to a depth of 2cm) appear normal with no evidence of wall thickening, mucosal irregularities, masses or cystic calculi.

The left kidney has a normal shape and size (3.54 cm). Overall echogenicity is normal with adequate corticomedullary distinction and a typical 1:3 cortex:medulla ratio. There is no evidence of perinephric inflammation or effusion. There is no evidence of pyelectasia, nephroliths, infarcts or hydroureter. Renal vasculature is normal.

The right kidney has a normal shape and size (3.73 cm). Overall echogenicity is normal with adequate corticomedullary distinction and a typical 1:3 cortex:medulla ratio. There is no evidence of perinephric inflammation or effusion. There is no evidence of pyelectasia, nephroliths, infarcts or hydroureter. Renal vasculature is normal.

Adrenal Glands

The left adrenal gland is normal in size measuring 0.50 cm at the caudal pole. It is observed in its normal position cranial to the left renal artery. It is normal in appearance (uniformly hypoechoic) and shape with no evidence of a mass effect.

The right adrenal gland is normal in size measuring 0.46 cm at the caudal pole. It is observed in its normal position between the cranial aspect of the right kidney and the caudal vena cava. It is normal in appearance (uniformly hypoechoic) and shape with no evidence of a mass effect.

Spleen

The spleen is subjectively normal in size, echotexture is homogenous, and the splenic capsule is smooth with no irregularities. The blood flow through the hilus and splenic parenchyma appears normal. No focal parenchymal abnormalities are visualized.

Liver

The liver is subjectively normal in size, and echogenicity with smooth peripheral margins. The parenchyma is homogenous echotexture. The visible portions of the vasculature and biliary tract appear normal. No focal nodules or cystic lesions are observed.

IMAGING PERFORMED BYSVS Mobile Imaging CT 262-366-5970
fredgromalak@gmail.com

EDUCATIONAL TELECONSULTATION SERVICES™

1-800-838-4268 info@sonopath.com SonoPath.com

PATIENT

Hollie Griffiths 52102A

SPECIES

Canine

BREED

Dachshund

SEX

Spayed Female

AGE

4 Years 10 Months

WEIGHT

5.18 kg

INTERPRETED BYKathleen Sennello DVM,
MS, Diplomate ACVIM
(Small Animal Internal
Medicine)**IMAGING PERFORMED BY**

Tom McNeill

HOSPITAL NAME

SVS Imaging CT

REFERRING VET

MVS- Dr. Alucard

INVOICE

39494

DATE

7/12/22

The gallbladder lumen is moderately distended. The wall of the gall bladder is not thickened and has a smooth mucosal surface. Luminal contents are primarily anechoic. The cystic and common bile ducts are normal/not visible.

Gastrointestinal

The stomach contains minimal luminal contents. It measures at a normal thickness of <0.7cm with some variability due to the presence of rugal folds. The distinction of the gastric wall layers is adequate and there is no impression of reduced peristaltic activity. No masses or focal lesions were observed.

The visualized areas of duodenum, jejunum and ileum have a relatively uniform diameter with minimal fluid distension. Wall thickness is normal. Bowel loops follow a curvilinear path with distinct wall layering maintaining the typical 1:3 muscularis:mucosa layer ratio. Duodenum wall measured 0.42 cm. Jejunum wall measured 0.26 cm. Visualized peristalsis appears appropriate. There were no focal lesions consistent with obstruction or a mass effect observed.

The ileocecal junction was visualized and exhibited normal intact wall layering and is subjectively of normal thickness. Sections of colon are visualized with formed fecal material and gas shadowing distally. There is no observed focal or generalized colon wall thickening or loss of layering.

Pancreas

The pancreas is prominent and mottled compared to the surrounding isoechoic mesentery. There is no evidence of nodules or cystic lesions. There is no evidence of regional mesenteric inflammation or fluid.

Free Abdomen

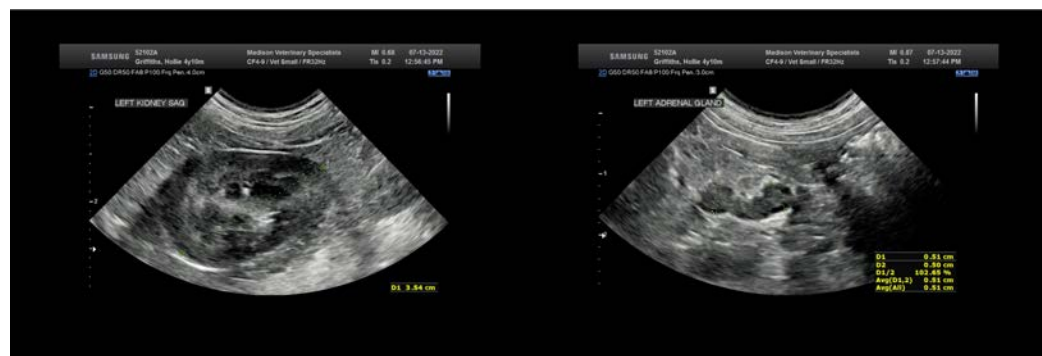
Evaluation of the peritoneal cavity did not reveal any evidence of effusion, or subjective lymphadenomegaly. The Medial iliac nodes appear normal and there was no evidence of a caudal aortic thrombus at the bifurcation. The omentum is of normal uniform echogenicity.

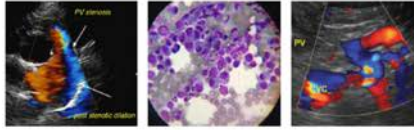
ULTRASONOGRAPHIC FINDINGS

- Prominent, mottled pancreas – The pancreatic changes are most consistent with age-related parenchymal remodeling, potentially secondary to a prior inflammatory episode, early fibrosis or chronic pancreatitis.

INTERPRETATION OF THE FINDINGS & FURTHER RECOMMENDATIONS

The changes observed on today's scan were very mild and could be within normal limits for this individual. Given the lack of overt GI signs and normal lab work, consider musculoskeletal pain as a differential with particular consideration to cervical or thoracolumbar pain in this breed. The pancreas is visible, but does not appear overtly inflamed. If pancreatitis is still strongly suspected, then consider a quantitative cPL and supportive treatment for pancreatitis.





PATIENT

Hollie Griffiths 52102A

SPECIES

Canine

BREED

Dachshund

SEX

Spayed Female

AGE

4 Years 10 Months

WEIGHT

5.18 kg

INTERPRETED BY

Kathleen Sennello DVM,
MS, Diplomate ACVIM
(Small Animal Internal
Medicine)

**IMAGING
PERFORMED BY**

Tom McNeill

HOSPITAL NAME

SVS Imaging CT

REFERRING VET

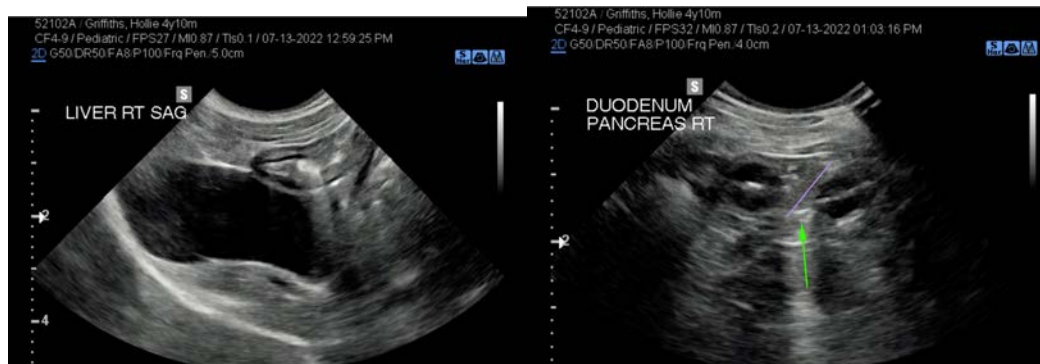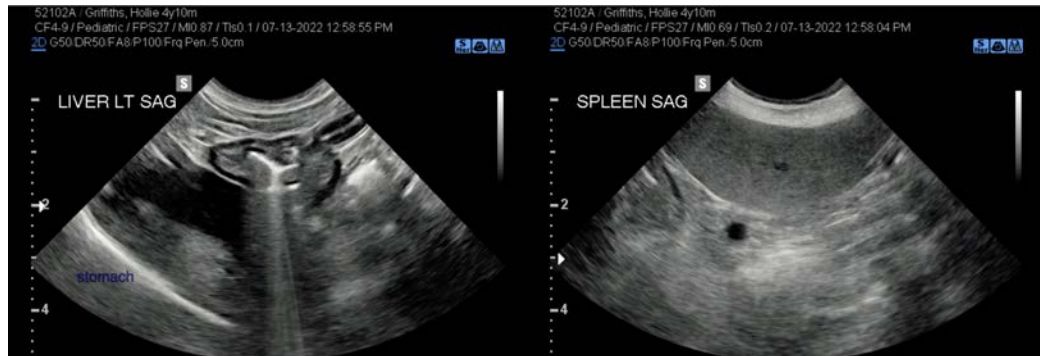
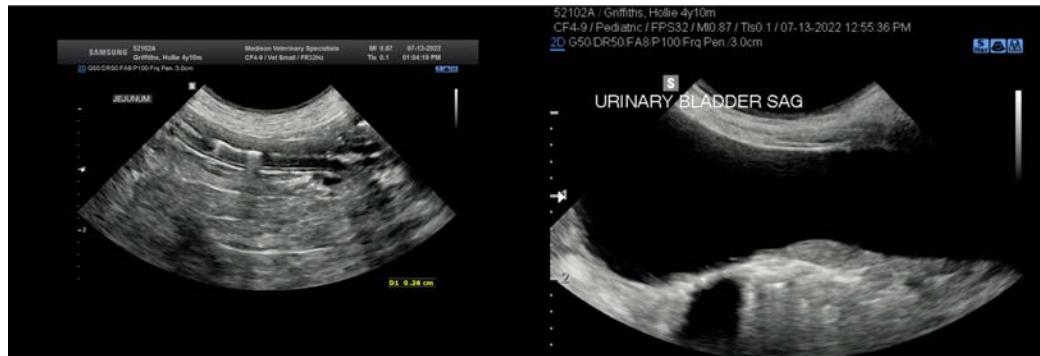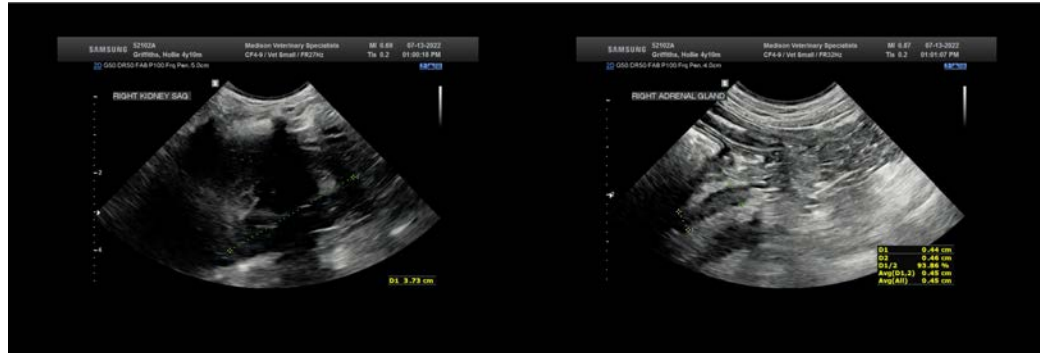
MVS- Dr. Alucard

INVOICE

39494

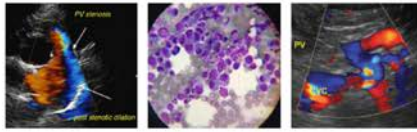
DATE

7/12/22



IMAGING PERFORMED BY

SVS Mobile Imaging CT 262 - 366 - 5970
fredgromalak@gmail.com



EDUCATIONAL TELECONSULTATION SERVICES™
1-800-838-4268 info@sonopath.com SonoPath.com

PATIENT

Hollie Griffiths 52102A

The information and recommendations provided are based on the images presented by the referring veterinarian/sonographer. No evaluation can be communicated regarding pathology that was not visible in the image/video clips provided.

SPECIES

Canine

Thank you for this referral. If the clinical or image interpretation does not parallel your findings or if I can be of any further assistance please contact me.

Kathleen Sennello DVM,MS, Diplomate ACVIM (Small animal Internal Medicine)

BREED

Dachshund

kathleen.sennello@sonopath.com

SEX

Spayed Female

AGE

4 Years 10 Months

WEIGHT

5.18 kg

INTERPRETED BY

Kathleen Sennello DVM,
MS, Diplomate ACVIM
(Small Animal Internal
Medicine)

**IMAGING
PERFORMED BY**

Tom McNeill

HOSPITAL NAME

SVS Imaging CT

REFERRING VET

MVS- Dr. Alucard

INVOICE

39494

DATE

7/12/22